

Cicero Urban, Mario Rietjens, Flavia Kuroda, and James Hurley II

2.1 Introduction

Breast cancer surgery has gone through various changes over the past decades. New techniques have been introduced and others have been applied to already existing models, which have made the surgical approach more complex, and biologically individualized. Although concern with local control of disease still persists as an essential element, this is currently associated with an aesthetic–functional concept.

Therefore, breast anatomy itself, or the way it is traditionally approached, needs updating. Form, volume, inframammary fold (IMF), height, and breast projection as well as the size and shape of the nipple and areola complex (NAC), liposubstitution level, and ptosis are some of the points concerning surface anatomy that have acquired more importance within the oncoplastic and reconstructive context. Similarly, the abdominal wall and the dorsal structure of the thorax must be part of the surgeon’s background, as one needs to have a reconstructive and oncoplastic view in order to make more suitable surgical decisions.

Patient requests were rarely considered as part of medical decisions in the past, in contrast with current breast cancer management, where oncologic and reconstructive surgery, chemotherapy (before or after definitive treatment), and radiation therapy are not separate issues, and should be combined with patient desires. So, it is expected that all surgeons involved in breast cancer surgery are comfortable with all alternatives for breast reconstruction, as well as the anatomic and functional relationships. It is within such a perspective that this chapter has been written.

2.2 Advances in Breast Surgery and Anatomic Repercussions

The decision to perform a mastectomy or breast-conserving therapy is based on local recurrence rates, and on aesthetic–functional outcomes, including the relationship between the tumor size and the breast size, as well as the location of the tumor inside the breast and its relation to the skin and the NAC and IMF.

Oncoplastic surgery combines plastic surgery techniques with oncologic breast surgery. This combination has resulted in multiple benefits for patients, as it allows larger resections, with wider margins, aiming to avoid compromising aesthetic–functional outcomes. However, this type of surgery implies knowledge of advanced mammoplasty techniques [1]. As a consequence, the vascularization and innervation of the NAC acquires fundamental importance in the choice of which mammoplasty technique should be used.

Skin-sparing mastectomy (SSM), initially described by Toth and Lappert in 1991, in which the breast, the NAC, the biopsy sites, and the skin above the tumor are removed, is already established for ductal carcinoma in situ and invasive cancers. In such a procedure most of the skin and the IMF are preserved, which makes it easier for immediate reconstruction performed by temporary expanders, definitive implants, or autologous tissues [2]. Histological studies of local recurrences in this type of surgery do not identify

C. Urban (✉)
Oncoplastic and Reconstructive Division, Breast Unit,
Hospital Nossa Senhora das Graças, Positivo University,
Curitiba, Brazil
e-mail: cicerourban@hotmail.com

M. Rietjens
Division of Plastic and Reconstructive Surgery,
European Institute of Oncology, Milan, Italy
e-mail: mario.rietjens@ieo.it

F. Kuroda
Breast Unit, Hospital Nossa Senhora das Graças, Curitiba, Brazil
e-mail: flaviakuroda@hotmail.com

J. Hurley II
Department of Breast Surgery, Chambersburg Hospital,
Chambersburg, USA
e-mail: jhurley54@hotmail.com

significant residual mammary tissue as a causative factor in the great majority of cases. These recurrences remain constant throughout time and are proportional to tumor size and to positive axillary lymph nodes. The mean time for local recurrence is between 2 and 4 years, and concomitant distant metastasis are frequent. This shows that this type of local recurrence, in contrast to the type that occurs after breast-conserving therapy, is rarely an isolated event, or one that may have any relationship with incomplete surgery, although representing a biological marker of tumor aggressiveness and risk of metastasis. Instead of having a minor importance in the oncologic context, the anatomy and the histology of the IMF became the basis for immediate breast reconstruction, and the IMF became one of the most important structures to be preserved.

Another recent technical alternative is nipple-sparing mastectomy. The results are considered better from the aesthetic–functional point of view. Therefore, preserving the NAC has a positive psychological influence. However, the long-term local recurrence rate is unknown for biologically different kinds of invasive tumors, and data reported in the literature are from retrospective cohorts [2]. Anatomical, histological, and electron-microscopic studies have been performed to ascertain the oncologic safety of this type of surgery, and trials are currently ongoing.

Sentinel node (SN) biopsy was introduced in the 1990s. Over 1,500 clinical studies have been performed around the world, involving over 11,000 patients. The SN is the first lymph node in the chain of breast lymphatic drainage. It is considered one of the greatest examples of success of applying evidence-based medicine to surgery. It is the standard procedure in patients with a clinically negative axilla, owing to two fundamental advantages: better axillary staging, when compared with axillary dissection, as the examination in the first lymph node is more detailed; and lower morbidity among patients with a negative axilla, owing to less extensive surgery [3]. Concern with lymphatic anatomy was reborn after the introduction of SN biopsy.

Axillary dissection is currently recommended only for patients with SN metastasis and inflammatory breast cancer. The recent publication of ACOSOG Z0011 results showed that it is possible to avoid axillary dissection even with SN metastases in breast-conserving therapy under certain conditions [4]. The most feared side effect is lymphedema, which can occur in 10–20 % of patients, in various degrees of severity, and mostly as an irreversible morbidity.

Regarding breast reconstruction, currently there is a preference for immediate reconstruction, as the psychological impact is positive and aesthetic results are generally better without compromising adjuvant treatments or

detection of future recurrences. Techniques employing temporary expanders and implants are the most frequently used. They bring the advantage of a faster procedure with low risk of complications. Among the techniques that use autologous flaps, the most frequently used ones are the transverse rectus abdominis myocutaneous (TRAM) flap and the latissimus dorsi flap, with or without addition of an implant. The TRAM flap allows the correction of excessive adipose tissue in the abdominal region as in an abdominoplasty, with transposition of skin islands and fat to reconstruct the breast. It can be monopedicled using only one rectus abdominis muscle or bipedicled, when both muscles are sacrificed. Microsurgical techniques represent a great advance in reconstructive surgery. They have the advantage of not causing major damage to the abdominal wall, and the risk of hernia is basically nonexistent.

So, anatomic concepts for reconstructive breast surgeons are not limited to the breast.

2.3 Surface Anatomy

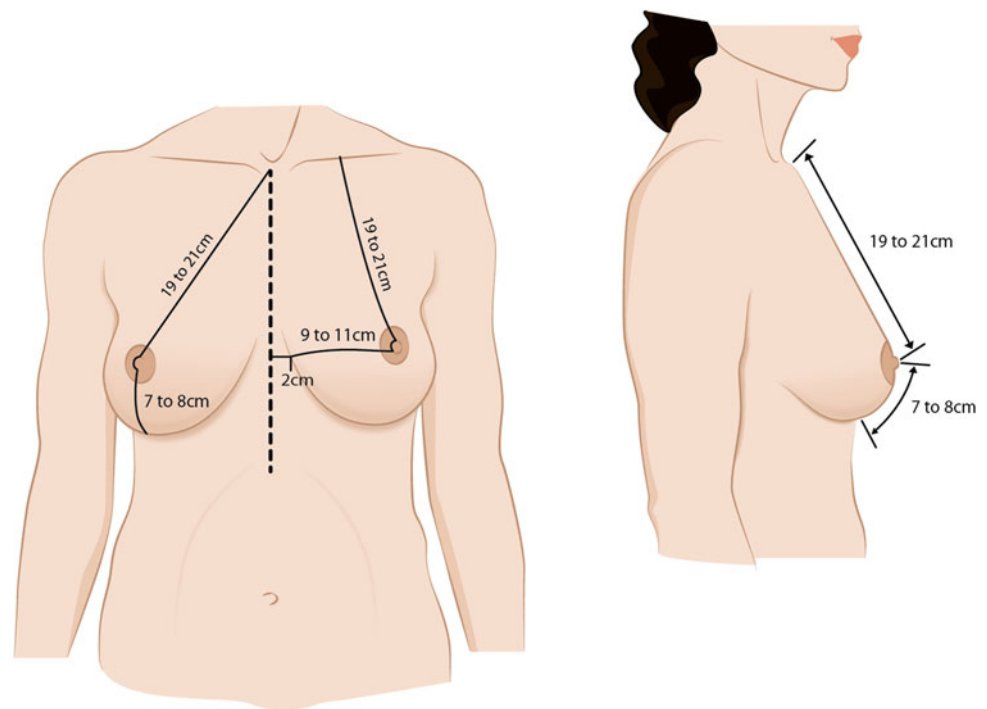
The breasts, vertically, are found on the anterior thoracic wall, extending between the second and sixth ribs, overlying the pectoralis major muscle superomedially, and the serratus anterior muscle in the lower third and medial areas. Considering the horizontal dimensions, they lie from the side edge of the sternum to the mid axillary line [5, 6]. This extension is critical, as it represents the size of the IMF, the so-called breast base, which is frequently used as a reference for the choice of implants or flaps in breast reconstruction. Differences in this base are known as a significant cause of asymmetry, and it is critical that the IMF be maintained or reconstructed in breast cancer surgery.

In the axillary region there is a prolongation beyond the anterior axillary line called the tail of Spencer. In adult women (i.e., after puberty), this has the shape of a drop, assuming the shape of a cone in nulliparous women and a more pendulous contour in multiparous women.

Determining factors for mammary aesthetics are volume, parenchyma distribution, tissue elasticity, location and appearance of the NAC, quality of the skin envelope, and the relation between the final shape of the breast, thoracic wall, and the body [7].

The normal breast has good skin and parenchyma elasticity, and most of the volume is located at the inferior and lateral pole. The NAC in a young person will be at a higher projection point, where all breast lines converge. The areola is usually round and from 15 to 45 mm in diameter. The nipple, placed at the central region of the areola, has between 4 and

Fig. 2.1 Surface anatomy demonstrating the relations between the nipple and areola complex, the sternum, and the inframammary fold



12 mm of projection and is where the lactiferous ducts converge in a number ranging from 15 to 20 (five to nine true mammary duct orifices and other sebaceous glands, tubercles, and tubes [8]). It contains a huge concentration of nerve sensorial terminations and an abundant lymphatic system called the subareolar or Sappey plexus [9–11]. The blood is supplied to the NAC by the internal mammary artery via its perforating branches, by the anterior intercostal arteries, by the lateral thoracic artery, and by branches from the axillary artery. The internal mammary artery is the main and constant contributor of blood to the NAC by means of its perforating branches numbering from one to four and anterior intercostal branches numbering from four to six [6–11].

The color of the NAC has particular importance as it differs according to ethnicity. It is a factor to be considered for reconstruction and for the final aesthetic result of the breast. It contains sebaceous and sudoriferous glands as well as an intermediate type of mammary and sudoriferous gland called Montgomery's glands. These open at the Morgagni tubercles and are able to secrete milk. There are also smooth muscle fibers in the areola, and through certain stimuli they can contract, reducing the size of the areola and projecting the papilla forward [6, 9, 10].

The relationship between the NAC and the IMF, within this context, can also differ according to the breast and the patient's age. The nipple is usually located between 19 and 25 cm from the manubrium, between 9 and 12 cm from the medial line of the sternum, and between 7 and 10 cm from the IMF. These distances are relative and may differ

according to the ethnic origin of the patient, and do not represent an anatomical abnormality (Fig. 2.1).

2.4 Surgical Anatomy of the Breast

The breasts are located over the pectoralis major muscle. Considering their structure, of cutaneous origin, a layer of adipose tissue and a layer of mammary tissue form them. The plane that separates the mammary tissue from the adipose tissue has great surgical value, as it can be identified in the flap during the surgical procedure and can be utilized in mastectomies and even in conservative surgical procedures.

In relation to the covering of the mammary tissue by fascia, it is important to consider the superficial fascia, which is found over the deep fascia of the skin (2–3 mm below), except at the areola and the nipple. This layer can be identified during the surgical dissection, allowing the separation of the mammary tissue from the skin where there is no bleeding, in an avascular plane. This fascia is connected with the deep fascia of the breast through fibrous fascia called Cooper's ligaments, which support the breast. On the posterior face of the gland there is a layer of thin adipose tissue that connects with the superficial fascia. This is separated from the pectoralis major muscle fascia by a layer of dense connective tissue called the posterior suspensory ligament of the breast. At the lateral and the inferior borders the breast lies on the fascia of the anterior

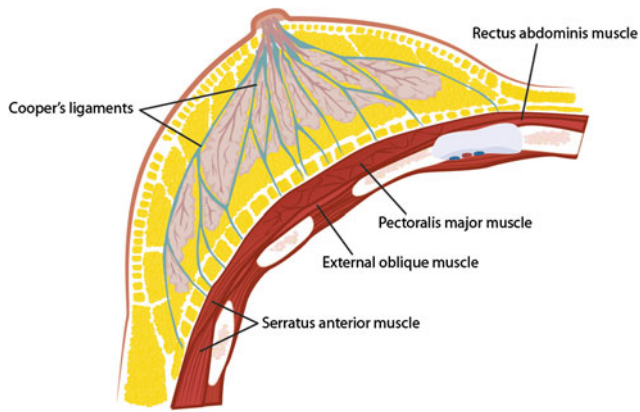


Fig. 2.2 Relationship between breast lobes, Cooper's ligaments, fat tissue, and thoracic muscles

serratus muscle and the anterior rectus abdominis muscle, respectively [6, 9].

Fifteen to twenty independent lobes that branch out in lobules and alveoli form the mammary gland. A lobe is made up of various lobules that branch out in ten to 12 alveoli. These form the functional units of the breast, and are responsible for the production and drainage of milk. They are enveloped by fatty fibrous tissue. The drainage system is made up of collecting ducts that drain to the lactiferous ducts situated at a retroareolar position where milk is stored and ejected then by the apex of the nipple [6] (Fig. 2.2).

The subclavian artery, the axillary artery, and intercostal arteries and their branches form the arterial vascularization of the breast. The knowledge of their relationships is important, as in reduction mammoplasties. It is essential that at least one of these arterial pathways be preserved so the areola and the nipple can remain viable. Therefore, there are techniques for the preservation of the upper pedicle, the lateral pedicle, or the inferior pedicle blood supplies.

The breast is supplied with blood coming from three main sources. The first one and also the most important one (representing over 60 % of the supply) is the internal mammary artery, which may originate from the second, third, or fourth intercostal space. It perforates these spaces and enters the breast in its superomedial portion, taking a superficial track from where it sends arterioles to the skin and to the mammary tissue [5, 6, 9]. It is important to identify and preserve the integrity of this system while making the skin flaps during SSM.

The second system originates in the axillary artery. The pectoral branch of the thoracoacromial artery, the highest thoracic artery, subscapular artery, and mainly the lateral mammary branches of the lateral thoracic artery are responsible for about 30 % of the blood supply of the breast. One of the lateral mammary branches is more developed and mainly supplies the upper outer quadrant of

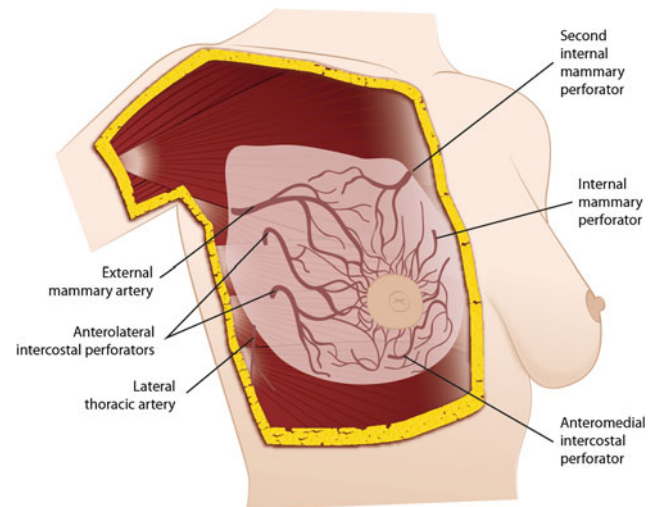


Fig. 2.3 Oblique view of the arterial vascularization of the breast

the breast [5, 6, 9]. The surgical relevance of this vessel is because it is used for mammary reconstruction procedures that demand microsurgical anastomoses.

The third source of breast blood supply comes from lateral cutaneous branches of the intercostal arteries, which are less important [5, 6, 9] (Figs. 2.3, 2.4).

The venous drainage is formed by a deep system and a superficial system. Low-caliber vessels that drain just below the superficial fascia form an interconnected traverse longitudinal network, like a knit cloth, which drains to the internal mammary vein and the anterior superficial jugular vein, the superficial system. In the deep system, the afferent branches discharge into three main pathways: tributaries of the internal mammary vein, tributaries of the intercostal veins, and the vertebral system. There is special interest in the mammary venous drainage owing to the potential use of certain branches in breast reconstructive surgical procedures. The drainage follows the course of the arteries, with a large number of anastomoses between the superficial and the deep system, and has the axillary vein (originating from the cephalic vein and the humeral vein) as its main system. Around the areola, the veins form a venous circle which together with the drainage of the mammary tissue follows a peripheral course up to the internal thoracic, axillary, and intercostal veins [6, 9]. Metastases can pass through any of these routes, following their way to the heart and then to the lung capillaries. Owing to a system of avalvular venous drainage that connects Batson's venous vertebral plexus to thoracic, abdominal, and pelvic organs, one can explain the route of metastases to the vertebra, ribs, and central nervous system from the breast, mainly through intercostal posterior veins.

Interest in studying lymphatic drainage has increased because of SN studies. In most cases, the SN position is at level I, close to the thoracodorsal artery and vein. The breast

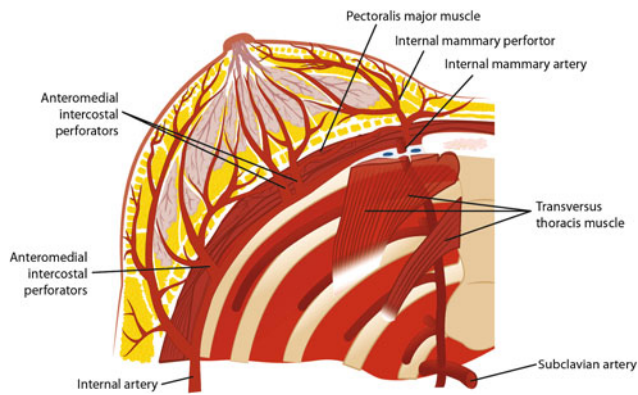


Fig. 2.4 Coronal view of the arterial vascularization of the breast

lymph vessels have their drainage established by two plexuses: superficial or Sappey's subareolar, and deep or aponeurotic. The former is made up by collecting trunks, which gather skin drainage, superficial breast planes, the nipple and areola, and the upper limb, supraumbilical region, and dorsum. The latter follows through the pectoralis muscles up to Rotter's lymph nodes (situated between the pectoralis major and the pectoralis minor muscles) and then toward the subclavian lymph nodes. Although the lymphatic flow is unidirectional, there is a great interrelation between the superficial system and the deep system as to breast drainage, which explains the broad variation of lymph drainage found in breast cancer [12]. Approximately 3 % of the breast lymph flows to the lymph nodes in the internal mammary chain and 97 % flows to the axillary lymph nodes. Any quadrant of the breast is able to drain to the internal mammary chain. Axillary nodes range in number from 20 to 30, and lymph node groups of axillary drainage can be divide into [5]:

- The axillary vein group or lateral group, consisting of four to six lymph nodes located medial or posterior to the axillary vein, holding most of the drainage from the superior portion of the breast.
- The external mammary group, also called the pectoral group, situated at the inferior border of the pectoralis minor muscle in association with the lateral thoracic vessels. It consists of four or five lymph nodes and holds most of the lymphatic drainage from the breast.
- The subscapular lymph node group or posterior lymph node group, consisting of six or seven lymph nodes situated along the posterior wall of the axilla up to the lateral border of the scapula and are associated with subscapular vessels. They also contain drainage from the cervical posterior region and the shoulder.
- The central group, consisting of three or four lymph nodes and situated posterior to the pectoralis minor

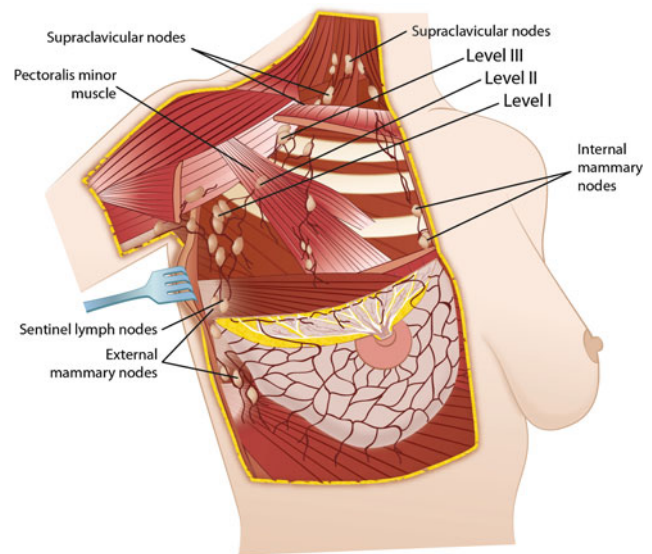


Fig. 2.5 Lymphatic drainage of the breast and the most frequent localization of the sentinel node

muscle, interwoven with the adipose tissue of the axilla. They hold drainage from the three groups mentioned above and they can also contain drainage directly from the breast. A sequence of this drainage moves on to the subclavicular lymph nodes or to apical lymph nodes. Clinically, this is the most palpable group, which is of extreme relevance to the clinical evaluation of axillary metastases.

- The subclavicular or apical group, consisting of six to 12 lymph nodes, situated posterior and superior to the border of the pectoralis minor muscle. It obtains drainage directly or indirectly from all the other groups. The lymphatic efferents of these ducts form the subclavian trunk, which pours into the right lymphatic duct and to the left side into the thoracic duct. Through this route there is also the possibility of drainage for lymph nodes from the deep cervical area.
- Rotter's group or the interpectoral group, consisting of one to four small lymph nodes situated between the pectoralis major and the pectoralis minor muscles associated with branches of thoracoacromial vessels.

There is another division of axillary lymph nodes that is routinely used by surgeons, taking into account the relation between the axilla and the pectoralis minor muscle. The lymph nodes that are situated lateral and below the pectoralis minor muscle are referred to as Berg's level I and encompass the external mammary group, the axillary vein, and the subscapular vein. Those situated behind this muscle are referred to as level II and correspond to the central group and part of the subclavicular group. The lymph nodes

situated above the superior border of the pectoralis minor muscle are referred to as level III and include the subclavicular group [5].

The lymph nodes of the internal mammary chain are situated in the intercostal spaces of the parasternal area. They are close to the internal mammary vessels, in the adipose extrapleural tissue. They are found medial to the mammary vessels in the first and second intercostal spaces and lateral to them in the third space [5]. There are also other accessory networks such as the one that connects the two breasts, called transmammary and paramammary, which is related to the hepatic lymph nodes and subdiaphragmatic nodes (Fig. 2.5).

Breast innervation in the inferior portion is dependent on the intercostal nerves, whereas in the superior portion it is dependent on levels 3 and 4 of the cervical plexus. The cutaneous sensation of the breast results from the anterior and lateral cutaneous branches originating from the second to the sixth intercostal branches, although mainly from the last three branches. The superior area of the breast is also innervated from the cervical plexus by the supraclavicular nerve. Important nerves to be identified in the axillary dissection are as follows: the nerve of the pectoralis major muscle, the nerve of the pectoralis minor muscle, the long thoracic nerve or Bell's nerve (if damaged it results in winged scapula), and the thoracodorsal nerve. The latter is easily visualized following the subscapular vessels up to the anterior–superior border of the latissimus dorsi muscle, and its identification as well as preservation is important when considering reconstructive cases with a latissimus dorsi flap. The intercostobrachial nerve is found below the axillary vein and is responsible for the sensory innervation of the superior third of the arm and the innervation of the sudoriferous glands of the axilla. It should, whenever possible, be preserved, as paresthesia in the medial portion of the arm and in the floor of the axilla is an important complaint from patients.

The most important muscles related to breast are as follows:

- The pectoralis major muscle is in close relation with most of the breast surface. It is a flat muscle and it is divided in two portions: clavicular and costosternal. The latter originates from the sternum and from the costal cartilages of the second and sixth ribs. It inserts in the major tubercular groove of the humerus and in the bicipital groove. The cephalic vein, which is often used for long-term catheters in chemotherapy, is the separation point between this muscle and the deltoid muscle, at the deltopectoral groove. Its function is flexion, adduction, and medial rotation of the arm. The medial and lateral portions of the pectoral nerves innervate it. These nerves, if sacrificed in axillary surgery, may cause retraction, local fibrosis, and loss of function [13]. The pectoralis major

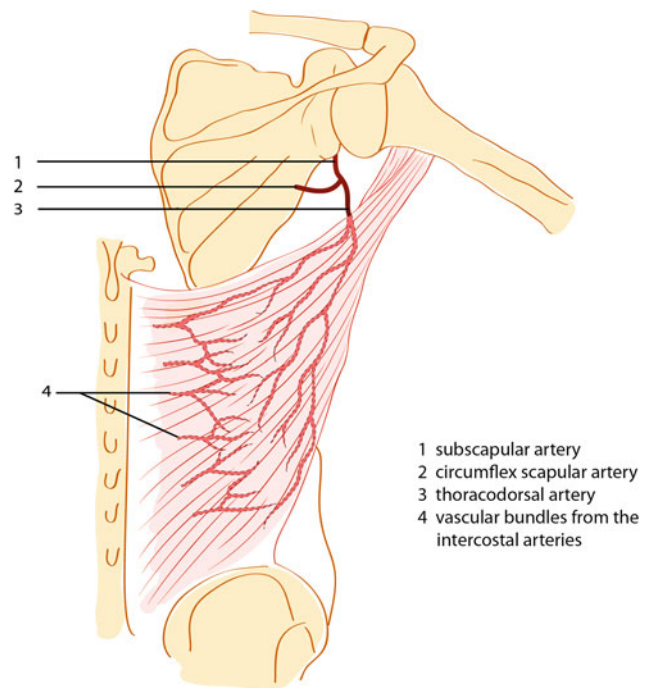


Fig. 2.6 Arterial supply to latissimus dorsi muscle

muscle is used for the protection of implants during mammary reconstructive procedures and also in aesthetic surgical procedures. Sometimes the implant covering is compromised when there is an anatomical variation as occurs when the inferior insertion of the muscle is in an upper part of the thoracic wall.

- The pectoralis minor muscle appears on the sternal fascia of the third, fourth, and fifth ribs and inserts in the coracoid process of the scapula. It is innervated by the medial pectoral nerve, which is a branch from the brachial plexus (C8-T1) [13]. It travels posteriorly to the axillary muscle and anteriorly to the axillary vein.
- The serratus anterior muscle originates on the surface of the upper eight ribs and inserts along the vertebral border of the scapula. The function of this muscle is to keep the scapula pressed against the thorax wall and it is innervated by the long thoracic nerve (Bell's nerve), originating from posterior branches of C5, C6, and C7 of the brachial plexus. The path of this nerve is posterior to the axillary vein and then emerges at the medial level of the subscapular fossa. It is important that this nerve is preserved during axillary dissection to avoid instability of the scapula, therefore reducing the strength of the shoulder, a condition known as winged scapula.
- The latissimus dorsi muscle originates on the spinous process and supraspinous ligaments of the seventh thoracic vertebra and on all sacral and lumbar vertebrae. It inserts in the bicipital sulcus of the humerus. The thoracodorsal nerve originating from the brachial plexus

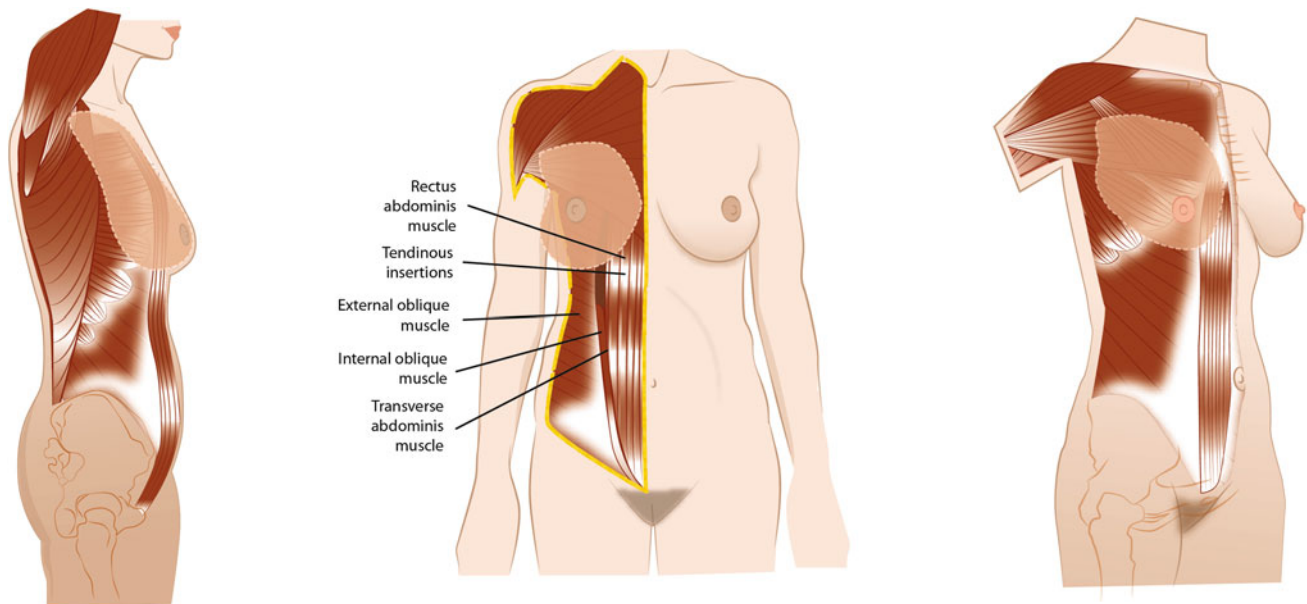


Fig. 2.7 Rectus abdominis muscle anatomy

rooted in C6, C7, and C8 innervates it. The nerve passes by the axilla and is contained in the axillary lymph nodes of the subscapular group. In the case of injury to this nerve, there is no motor disability; however, it is not possible to use this muscle for breast reconstructions. The arterial supply is shown in Fig. 2.6.

- The rectus abdominis muscle is the muscle that recovers the anterior wall of the abdomen. It inserts is the inferior margin of the fifth, sixth, and seventh costal cartilages. As this muscle goes down to the pubis, it becomes narrower and inserts into the body of the pubis inferiorly. It also has the so-called tendineae (areas of interruption of the muscle), which are usually four in number. One is positioned at the navel level, two are above this level, and one is below it. The muscle is enveloped by a fibrous fold that originates in the aponeurosis of the internal oblique muscle, external oblique muscle, and transverse abdominis muscle, which joins along with the medial line forming the linea alba. This is the inferior limit for the muscle dissection in TRAM flaps. The posterior face of this muscle lies on the subpectoral tissue. From bottom to top, its blood supply is from the inferior epigastric artery, which is a branch of the external iliac artery, and the blood supply of the superomedial portion is from the superior epigastric artery, which is a branch of the internal thoracic artery, originating at the subclavian artery. These two arteries produce a rich network of anastomoses among them (the choke system), therefore establishing communication between the subclavian artery and the external iliac artery. This anatomy is very important for breast reconstruction. This type of surgery

can be performed by using the rectus abdominis muscle either unilaterally or bilaterally together with the subcutaneous tissue and skin, tying off the inferior epigastric artery and rotating the flap through a tunnel previously prepared toward the mammary site; or simply by using subcutaneous tissue and abdominal skin and performing microanastomoses between perforating vessels and either internal mammary vessels or lateral thoracic vessels (Figs. 2.7, 2.8).

The IMF has been subject of special attention lately because of its importance to immediate reconstruction in SSM and nipple-sparing mastectomy. It is situated at the level of the fifth rib in a medial position and in its lateral portion it overlies the sixth intercostal space. It is an important anatomic landmark in breast surgery, because it defines the shape and structure of the breast, and is a boundary for reconstructive and aesthetic surgical procedures. From the onset of breast development, it anchors the inferior pole of the breast to the chest wall, and with age, the breast begins to sag or become ptotic relative to this point [14, 15]. The relationship between it and the pectoralis major muscle is also important with respect to breast implant support. It is located inferior to the inferior origin of the pectoralis major muscle [16]. Considerable attention should be paid to its role in creating a naturally appearing breast in different techniques. In augmentation mammoplasty, the IMF provides a relatively well hidden site for an incision to place a mammary implant and provides inferior support for subpectoral implants that is essential to prevent migration [18]. Its distance from the areola and its bilateral symmetry preservation are some points that must be

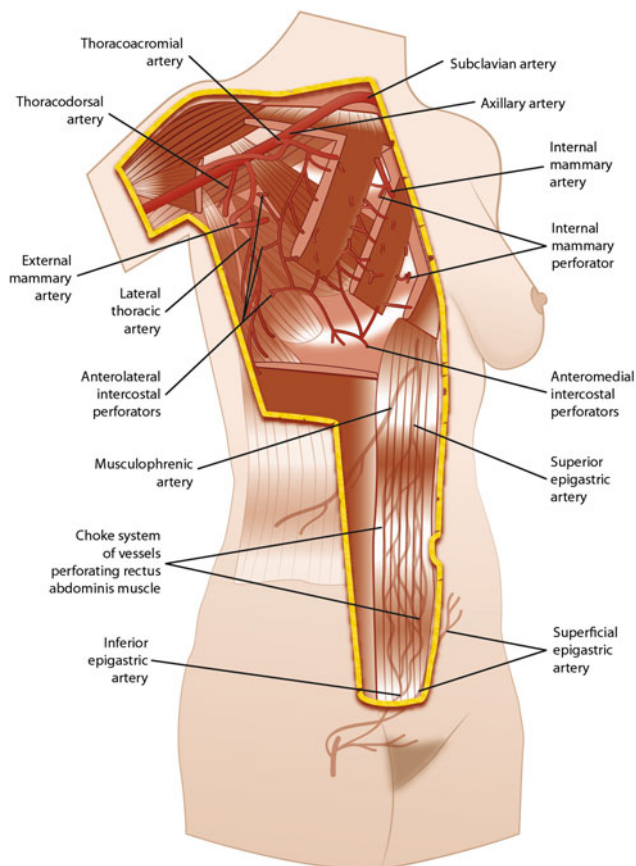


Fig. 2.8 Arterial supply to rectus abdominis muscle, and the choke system

observed for a satisfactory aesthetic–functional result. It represents a zone of adherence of the superficial fascial system as well as an increase in dermal collagen [14, 15, 17]. It has a ligament that originates at the periosteum of the fifth rib medially and the fascia between the fifth and the sixth rib laterally, inserting into the deep dermis [18]. However, the existence and origin of this ligament is not universally agreed upon by anatomists. Preserving it in mastectomies is still a subject of debate owing to the possibility of there being remaining mammary tissue at the site. Gui et al. [19] found that 28 % of their IMF specimens contained breast tissue and lymph nodes. However, aiming to explain this, Carlson et al. [20] showed that preserving it keeps <0.02 % of the total mammary tissue. If the IMF is breached, it must be repaired to reconstitute the natural breast crease at the time of breast reconstruction to maintain the correct breast implant position and achieve an optimal final aesthetic outcome [17, 19]. Chapter 34 is dedicated to IMF reconstruction.

2.5 Conclusions

Aesthetic–functional breast anatomy is essential to reconstructive breast cancer surgery. The spatial organization of the mammary ducts, the vascularization, and the innervation have relevant therapeutic implications in the era of SN and oncoplastic surgery, so the reconstructive breast surgeon must be aware of all of these important anatomic relationships.

References

- Urban CA (2008) New classification for oncoplastic procedures in surgical practice. *Breast* 17(4):321–322
- Chung AP, Sacchini V (2008) Nipple-sparing mastectomy: where are we now? *Surg Oncol* 17(4):261–266
- Lyman GH, Giuliano AE, Somerfield MR, Benson AB 3rd, Bodurka DC, Burstein HJ et al (2005) American society of clinical oncology guideline recommendations for sentinel lymph node biopsy in early-stage breast cancer. *J Clin Oncol* 23(30):7703–7720
- Giuliano AE, Hunt KK, Ballman KV, Beitsch PD, Whitworth PW, Blumencranz PW et al (2011) Axillary dissection vs no axillary dissection in women with invasive breast cancer and sentinel node metastasis. *JAMA* 305(6):569–575
- Djohan R, Gage E, Bernard S (2008) Breast reconstruction options following mastectomy. *Cleve Clin J Med.* 74(1):17–23
- Pandya S, Moore RG (2011) Breast development and anatomy. *Clin Obstet Gynecol* 54(1):91–95
- Westreich M (2009) Anthropomorphic measurement of the breast. In: Shiffman MA (ed) *Breast augmentation: principles and practice*. Springer, Berlin, pp 27–44
- Love SM, Barsky SH (2004) Anatomy of the nipple and breast ducts revised. *Cancer* 101(9):1947–1957
- Romrell LJ, Bland KI (1998) Anatomy of the breast, axilla, chest wall, and related metastatic sites. In: Bland KI, Copeland EM (eds) *The breast: comprehensive management of benign and malignant diseases*. W.B. Saunders, Philadelphia, pp 21–38
- Nicholson BT, Harvey JA, Cohen MA (2009) Nipple-areolar complex: normal anatomy and benign and malignant processes. *Radiographics* 29(2):509–523
- Van Deventer PV (2004) The blood supply to the nipple-areola complex of the human mammary gland. *Aesthetic Plast Surg* 28(6):393–398
- Suami H, Pan WR, Mann GB, Taylor GI (2008 Mar) The lymphatic anatomy of the breast and its implications for sentinel lymph node biopsy: a human cadaver study. *Ann Surg Oncol* 15(3):863–871
- Macchi V, Tiengo C, Porzionato A, Parenti A, Stecco C, Mazzoleni F et al (2007 Mar) Medial and lateral pectoral nerves: course and branches. *Clin Anat* 20(2):157–162
- Boutros S, Kattash M, Wienfeld A, Yuksel E, Baer S, Shenang S (1998) The intradermal anatomy of the inframammary fold. *Plast Reconstr Surg* 102(4):1030–1033

15. Muntan CD, Sundine MJ, Rink RD, Acland RD (2000) Inframammary fold: a histologic reappraisal. *Plast Reconstr Surg* 105(2):549–556
16. Nanigian BR, Wong GB, Khatri VP (2007) Inframammary crease: positional relationship to the pectoralis major muscle origin. *Aesthet Surg J* 27(5):509–512
17. Akhavani M, Sadri A, Ovens L, Floyd D (2011) The use of a template to accurately position the inframammary fold in breast reconstruction. *J Plast Reconstr Aesthet Surg* 64(10):259–261
18. Bayati S, Seckel BR (1995) Inframammary crease ligament. *Plast Reconstr Surg* 95(3):501–508
19. Gui GP, Behranwala KA, Abdullah N, Seet J, Osin P, Nerurkar A et al (2004) The inframammary fold: contents, clinical significance and implications for immediate breast reconstruction. *Br J Plast Surg* 57(2):146–149
20. Carlson GW, Grossl N, Lewis MM, Temple JR, Styblo TM (1996 Sep) Preservation of the inframammary fold: what are we leaving behind? *Plast Reconstr Surg* 98:447–450