

CHAPTER 1

Science of the Nail Apparatus

David A.R. de Berker¹ and Robert Baran²

¹Bristol Dermatology Centre, Bristol Royal Infirmary, Bristol, UK

²Nail Disease Center, Cannes; Gustave Roussy Cancer Institute, Villejuif, France

Gross anatomy and terminology, 1	Venous drainage, 19	Physical properties of nails, 35
Embryology, 3	Effects of altered vascular supply, 19	Strength, 35
Morphogenesis, 3	Nail fold vessels, 19	Permeability, 35
Tissue differentiation, 4	Glomus bodies, 20	Radiation penetration, 37
Factors in embryogenesis, 4	Nerve supply, 21	Imaging of the nail apparatus, 37
Regional anatomy, 5	Comparative anatomy and function, 21	Radiology, 37
Histological preparation, 5	The nail and other appendages, 22	Ultrasound, 37
Nail matrix and lunula, 7	Phylogenetic comparisons, 23	Profilometry, 38
Nail bed and hyponychium, 9	Physiology, 25	Dermoscopy (epiluminescence), 38
Nail folds, 11	Nail production, 25	Photography, 38
Nail plate, 15	Normal nail morphology, 27	Light, 40
Vascular supply, 18	Nail growth, 28	Other techniques, 41
Arterial supply, 18	Nail plate biochemical analysis, 31	

Gross anatomy and terminology

Knowledge of nail unit anatomy and terms is important for clinical and scientific work [1]. The nail is an opalescent window through to the vascular nail bed. It is held in place by the nail folds, origin at the matrix and attachment to the nail bed. It ends at a free edge distally, overlying the hyponychium. These structures are illustrated in Figures 1.1 and 1.2. Definitions of the components of the nail unit are as follows.

- **Nail plate (nail):** durable keratinized structure which continues growing throughout life.
- **Lateral nail folds:** the cutaneous folded structures providing the lateral borders to the nail.
- **Proximal nail fold (posterior nail fold):** cutaneous folded structure providing the visible proximal border of the nail, continuous with the cuticle. On the under-surface this becomes the dorsal matrix.
- **Cuticle (eponychium):** the layer of epidermis extending from the proximal nail fold and adhering to the dorsal aspect of the nail plate.
- **Nail matrix (nail root):** traditionally, this can be split into three parts [2]. The dorsal matrix is synonymous

with the ventral aspect of the proximal nail fold. The intermediate matrix (germinative matrix) is the epithelial structure starting at the point where the dorsal matrix folds back on itself to underlie the proximal nail. The ventral matrix is synonymous with the nail bed and starts at the border of the lunula, where the intermediate matrix stops. It is limited distally by the hyponychium.

- **Lunula (half moon):** the convex margin of the intermediate matrix seen through the nail. It is paler than the adjacent nail bed. It is most commonly visible on the thumbs and great toes. It may be concealed by the proximal nail fold.
- **Nail bed (ventral matrix, sterile matrix):** the vascular bed upon which the nail rests, extending from the lunula to the hyponychium. This is the major territory seen through the nail plate.
- **Onychodermal band:** the distal margin of the nail bed has a contrasting hue in comparison with the rest of the nail bed [3]. Normally, this is a transverse band of 1–1.5 mm of a deeper pink (Caucasian) or brown (Afro-Caribbean). Its colour, or presence, may vary

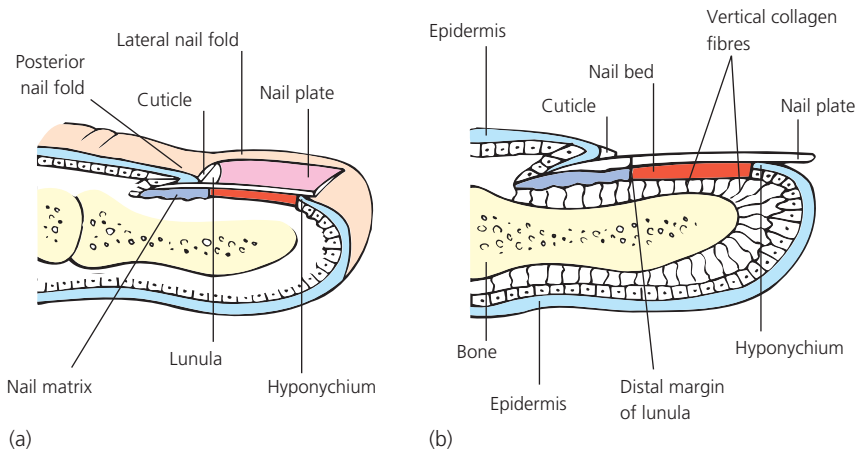


Figure 1.1 Longitudinal section of a digit showing the dorsal nail apparatus.

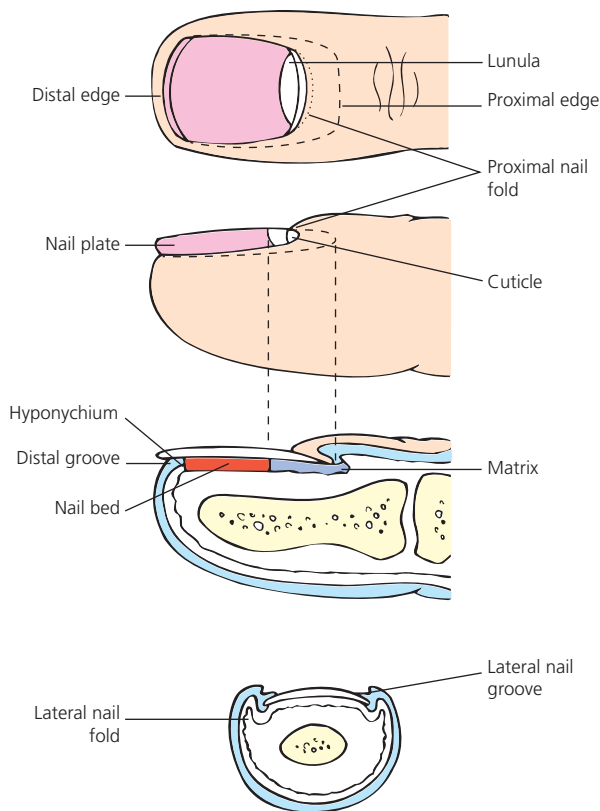
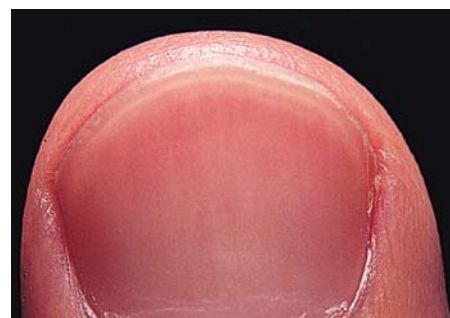
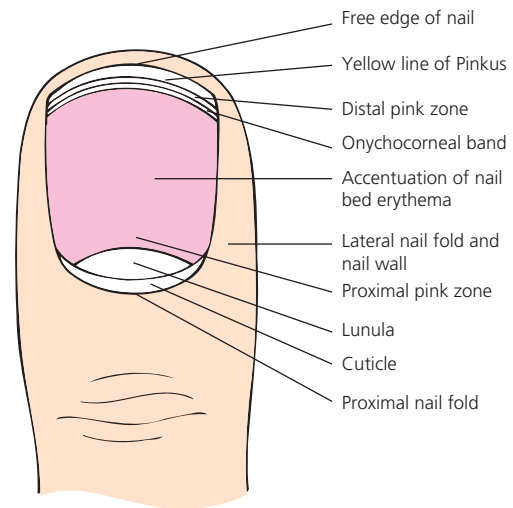


Figure 1.2 The tip of a digit showing the component parts of the nail apparatus.



(a)



(b)

Figure 1.3 (a) Onychodermal band. (b) Diagrammatic representation of the morphological features of the normal nail; detail of the distal physiological color bands is shown. Courtesy of T.S. Sonnex and W.A.D. Griffiths.

with disease or compression which influences the vascular supply (Fig. 1.3). Sonnex *et al.* [4] examined 1000 nails from thumbs and fingers in 100 subjects, alive and dead. In addition to clinical observation, they obtained histology from cadavers. Their findings are summarized in Table 1.1. The onychocorneal band represents the first barrier to penetration of materials beyond the nail plate. Disruption of this barrier by disease or trauma precipitates a range of further

events affecting the nail bed. The white appearance of the central band represents the transmission of light from the digit tip through the stratum corneum and up through the nail. If the digit is placed against a black surface, the band appears dark.

- **Hyponychium (contains the solenhorn):** the cutaneous margin underlying free nail, bordered distally by the distal groove.
- **Distal groove (limiting furrow):** a cutaneous ridge demarcating the border between subungual structures and the finger pulp.

Embryology

Morphogenesis

8–12 weeks

Individual digits are discernible from the 8th week of gestation [5]. The first embryonic element of the nail unit is

the nail anlage, present from 9 weeks as the epidermis overlying the dorsal tip of the digit. At 10 weeks, a distinct region can be seen and is described as the primary nail field. This almost overlies the tip of the terminal phalanx, with clear proximal and lateral grooves in addition to a well-defined distal groove. The prominence of this groove is partly due to the distal ridge, thrown up proximally, accentuating the contour. The primary nail field grows proximally by a wedge of germinative matrix cells extending back from the tip of the digit. These cells are proximal to both the distal groove and ridge. The spatial relationship of these two latter structures remains relatively constant as the former becomes the vestigial distal groove and the latter the hyponychium (Fig. 1.4).

13–14 weeks

Differential growth of the slowly developing primary nail field and surrounding tissue results in the emergence of overhanging proximal and lateral nail folds. Depending on the point of reference, the nail folds may be interpreted as overhanging [6] or the matrix as invaginating. By 13 weeks the nail field is well defined in the finger, with the matrix primordium underlying a proximal nail fold. By 14 weeks the nail plate is seen emerging from beneath the proximal nail fold, with elements arising from the lunula as well as more proximal matrix.

17 weeks to birth

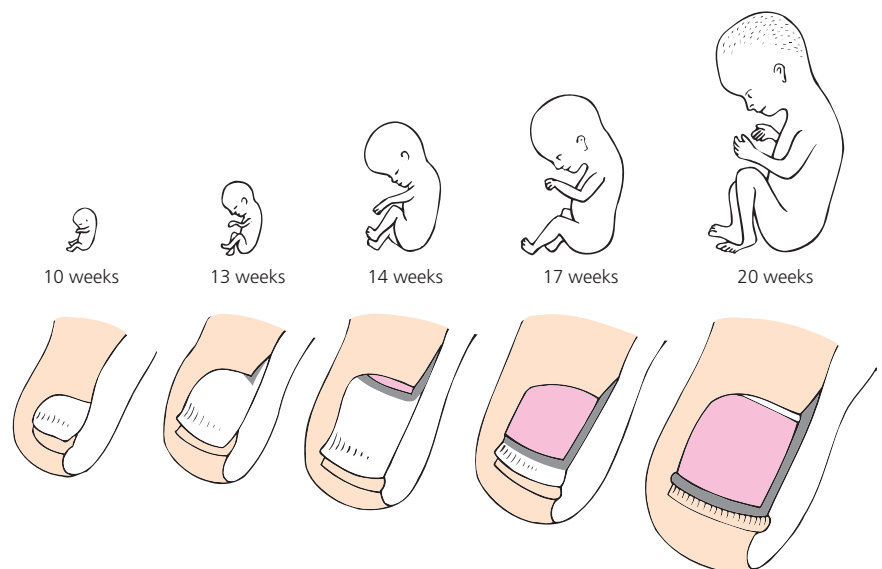
At 17 weeks, the nail plate covers most of the nail bed and the distal ridge has flattened. From 20 weeks, the nail unit and finger grow in tandem, with the nail plate abutting the distal ridge. This is now termed the hyponychium. The nail bed epithelium no longer produces keratohyalin, with a more parakeratotic appearance. By birth the nail plate

Table 1.1 Clinical appearance of distal zones of the nail bed.

Zone	Subzone	Appearance
Free edge	–	Clear gray
Onychocorneal band		
I	Distal pink zone	0.5–2 mm distal pink margin, may merge with free edge
II	Central white band	0.1–1 mm distal white band representing the point of attachment of the stratum corneum arising from the digit pulp
III	Proximal pink gradient	Merging with nail bed

Figure 1.4 Embryogenesis of the nail apparatus.

Ten weeks: the primary nail field can be seen with proximal, lateral and distal grooves. The latter is accentuated by a distal ridge. *Thirteen weeks:* a wedge of matrix primordium moves proximally, with the invagination of the proximal nail fold above. *Fourteen weeks:* the nail plate emerges. *Seventeen weeks:* the nail plate covers most of the nail bed and the distal ridge starts to flatten. *Twenty weeks:* the nail plate extends to the distal ridge, now termed hyponychium. Finger and nail grow roughly in tandem from now on. Fetuses are one-fifth of actual size.



extends to the distal groove, which becomes progressively less prominent. The nail may curve over the volar surface of the finger. It may also demonstrate koilonychia. This deformity is normal in the very young and a function of the thinness of the nail plate. It reverses with age.

Tissue differentiation

Keratins are filament-forming proteins of epithelial cells. They are found within the cytoplasm. There are 54 human keratins and their genes are divided into three categories:

- epithelial keratins/genes
- hair keratins/genes
- keratin pseudogenes.

Schweizer devised the reclassification of keratins according to the system described below to accommodate the changing knowledge of keratins in the context of the previous system (Table 1.2) [7].

The element of common ground between hair and nail biology is reflected in many shared keratins that lend physical characteristics to the tissue. Hence, although nail biology is not acknowledged in this scheme, where there is a designation of hair keratin, it is common for it also to be a nail keratin and for the higher level of sulfur amino acids in the keratin to afford a larger number of intramolecular cross-links and greater physical stability and strength.

Keratin synthesis can be identified in the nail unit from the earliest stages of its differentiation [8]. In 12- and 13-week embryos, the nail-matrix anlage is a thin epithelial wedge penetrating from the dorsal epidermis into the dermis. This wedge is thought to represent the "ventral matrix primordium." By week 15, hard keratins are seen throughout the nail bed and matrix. This could have significance concerning theories of nail embryogenesis and growth, where debate exists as to

the contribution made by the nail bed to nail growth [5,9–12]. However, at 22 weeks, the layer of hard keratin positive cells remains very thin in the nail bed, whereas it is considerably thickened in the matrix. In the adult nail, there have been reports of both the presence [13] and absence [8,14–16] of hard keratins in the nail bed.

Histological observation at 13 and 14 weeks reveals parakeratotic cells just distal to this nail plate primordium staining for disulfydryl groups. This contrasts to adjacent epithelium, suggesting the start of nail plate differentiation. This early differentiation represents matrix formation and Merkel cells have been detected in the matrix primordium of human fetuses between weeks 9 and 15 [17]. Merkel cells may play a role in the development of epidermal appendages and are detectable using monoclonal antibodies specific to keratin 20. Their role in ontogenesis would explain their disappearance from the nail matrix after week 22 [17]. However, this is not a universal finding, with an abundance of Merkel cells identified in the matrix of young adult and cadaver nail specimens in one study [18].

At the 13–22-week stage there is coincident increase in the expression of hard keratins and the development of keratohyalin granules.

By 25 weeks, most features of nail unit differentiation are complete. Changes may still occur in the chemical constitution of the nail plate after this date. A decrease in sulfur and aluminum and a rise in chlorine have been noted as features of full-term newborns in comparison with the nail plate of premature babies [19]. An elevated aluminum level may correspond to bone abnormalities which lead to osteopenia.

Factors in embryogenesis

The nail plate grows from the 15th week of gestation until death. Many factors act upon it in this time and influence its appearance. Because it is a rugged structure, growing over a cycle of 4–18 months, it provides a record of the effects of these influences. To consider the different formative mechanisms, it is important to distinguish between:

- embryogenesis
- regrowth
- growth.

There is overlap between all these processes, with the main clues concerning embryogenesis deriving from fetal studies and analysis of congenital abnormalities. Regrowth is the growth of the nail plate following its removal. This may be for therapeutic reasons or following accidental trauma with associated damage. Observation of this process adds to our understanding of both growth and embryogenesis. Growth is the continuous process of nail plate generation over a fully differentiated nail bed and hyponychium. Embryogenesis is the subject of this section.

Table 1.2 Keratins and their former designations (www.interfil.org/proteinsTypeInII.php).

Category	Number range
Human type I epithelial keratins	9–28
Human type I hair keratins	31–40
Non-human type I epithelial and hair keratins	41–70
Human type II epithelial keratins	1–8 and 71–80
Human type II hair keratins	81–86
Non-human type II epithelial and hair keratins	87–120
Type II keratin pseudogene	121–220
Type I keratin pseudogenes	221 →

In the chick limb bud formation, there is a complex interaction between mesoderm and ectoderm. Initially, the mesoderm induces the development of the apical ectodermal ridge (AER). The mesoderm then becomes dependent upon the AER for the creation of the limb. Removal of the AER results in a halt of mesodermal differentiation. Replacing the underlying mesoderm with mesoderm from another part of the limb primordium still results in normal differentiation [20]. However, the AER continues to be dependent upon the mesoderm, which must be of limb type. Replacement of limb mesoderm with somite mesoderm causes flattening of the AER. These morphogenetic interactions occur prior to cytodifferentiation [21]. In the human, cases of anonychia secondary to phenytoin [22] might implicate the drug at this stage, prior to 8 weeks. Drugs have been suggested as contributing to congenital nail dystrophies mainly affecting the index finger [23].

Subsequent work on limb bud biology has explored the significance of the transcription factor LIM1B in the mouse embryo limb formation. This factor is implicated in the dorsal/ventral polarity of the evolving limb and has been confirmed to have a similar role in humans. Loss of effective LIM1X function results in duplication of structures such that there might be a ventral ventral digit rather than dorsal ventral where the finger pulp is repeated on both sides of the digit [24]. The LIM1X system also acts on genes determining development of the eye and urogenital tract, which is the basis for involvement of all these systems in nail patella syndrome. In this pathology, the differentiation messages from the mesenchyme to the ectoderm appear to be communicated in a manner that might formally be described in observational limb bud experiments.

LMX1B is thought to be mediated through the spondin pathway where spondins are a family of proteins contributing to intracellular communication. In hereditary anonychia, it has been demonstrated that there is a defect in R-spondin 4 secretion where this protein would normally determine the activity of the Wnt/ β catenin signaling system that is thought in turn to play a part in the initiation of nail unit formation [25, 26]. R-spondin 2 is expressed in the AER in normal mouse limb development [27]. Mice bred to be deficient in this spondin have substantial congenital limb anomalies, with lack of phalangeal development and no nail unit [27]. Consistent with the model of mesenchyme inducing the overlying ectoderm, spondins have been identified in fibroblast cultures but not keratinocyte cultures [28].

Multiple other biological pathways appear relevant to the formation of a normal nail unit. Transgenic mice with changes to the *Akt* gene demonstrate absent nail and distal bone. Akt is a serine/threonine protein kinase implicated in cell signaling [29]. Although the spondins reside

in the mesenchyme and appear relevant to the interaction between mesenchyme and ectoderm, Akt is epithelial and is thought to play a part in the action of bone morphogenetic protein (BMP). BMP is part of the transforming growth factor (TGF)- β family of mediators. It is found in many different forms with a range of morphogenetic roles. In relation to the formation of the nail unit, it has been proposed that there is a two-way process whereby it is supportive of nail unit development, but equally that the nail unit plays a part in the regeneration of the distal phalanx when it is lost through trauma in infancy [30] and these processes may in part be mediated through BMP4.

Congenital abnormalities provide clinical examples of instances where the role of a BMP or similar factor appears central. Congenital onychodysplasia of the index fingers (COIF) is frequently associated with abnormalities of the terminal phalanges and interphalangeal joints [31]. The nail may be absent, small or composed of several small nails on the dorsal tip of the affected finger. The bony abnormality varies, with the most marked change being bifurcation of the terminal phalanx on lateral x-ray [32]. However, a bony abnormality is not mandatory in this condition or other conditions with ectopic nail [33]. A normal nail may overlie an abnormal bone on other than the index finger [34]. COIF appears to demonstrate an association between abnormalities of bone and nail, rather than the presence of a strict relationship. It may represent a fault of mesoderm/ectoderm interaction at the stage when these layers are mutually dependent. It has been suggested that a vascular abnormality may provide the common factor between pathology in the two embryonic layers [35]. This would also be consistent with the part played by BMP in vascular development in embryogenesis [36]. If this is the case, it appears likely that any vascular abnormality arises due to a defect of patterned embryogenesis rather than a random event, given that a form of COIF can occur in the big toe of individuals with involved fingers [37].

An interpretation based upon a mutual mesodermal and ectodermal fault would fit with the observation of two cases of congenital anonychia and hypoplastic nails combined with hypoplastic phalanges [38]. These cases were used as a foil for the suggestion of a mechanism of "bone-dependent nail formation." It might also be argued in reverse that the bone was dependent upon the nail.

Regional anatomy

Histological preparation

High-quality sections of the nail unit are difficult to obtain. Nails are very hard and tend to split or tear. In biopsies containing nail plate and soft subungual and

periungual tissue, the nail plate is often torn from the matrix and other adjacent structures by the microtome. Laboratories unused to nail histology will often have problems, contact the clinician for advice, be slow to provide a result and have sections of mixed quality. This is in large part due to the hardness of nail, which does not soften adequately with the normal decalcification processes used in bone histology, the other hard material laboratories are used to handling. Problems can be diminished using a range of techniques to soften the nail which may be less practical if there are soft tissue attachments requiring histological examination.

When obtaining a specimen for histology, it is useful to ensure that it is oriented. In samples with indicative structures such as a nail fold or the digit pulp, this may be relatively easy, although it can be valuable to ink the edge of the biopsy most closely related to the pathology. This is particularly true for the lateral longitudinal biopsy where typically the edge abutting the lateral nail fold will hold less information than the opposite inner edge. For punch biopsies or other small samples, it may be helpful to ink the upper surface so that sections are cut perpendicular to this edge and clear histological assessment is possible [39].

Nail softening techniques

Nail alone

There are several different techniques to soften the nail plate. Lewis [5] recommended routine fixation in 10% formalin and processing as usual. Earlier methods employed fixation with potassium bichromate, sodium sulfate or sodium bisulfite and water. The section is then decalcified with nitric acid and embedded in collodion. Alkiewicz and Pfister [40] recommended softening the nail with thioglycollate or hydrogen peroxide. Nail fragments are kept in 10% potassium thioglycollate at 37°C for 5 days or in 20–30% hydrogen peroxide for 5–6 days. The nail is then fixed by boiling in formalin for 1 min before cutting 10–15 mm sections.

Although softening of nail clippings for histology is not mandatory, it is possible and may be helpful. Suarez *et al.* [41] suggest soaking the clipping for 2 days in a mix of mercuric chloride, chromic acid, nitric acid and 95% alcohol. The specimen is then transferred to absolute alcohol, xylene and successive paraffin mixtures, sectioned at 4 mm and placed on gelatinized slides. An alternative method, described for preserving histological detail in the nail plate, entails fixation in a mix of 5% trichloroacetic acid and 10% formalin for the initial 24 h [42]. This is followed by a modified polyethylene glycol-pyroxylin embedding method. Ultra-thin sections can be provided by embedding the nail in plastic such as 2-hydroxyethyl methacrylate [43].

Nail and soft tissue

In nail biopsies containing soft tissue, more gentle methods of preparation are necessary. The specimen can be soaked in distilled water for a few hours before placing in formalin [44]. Twelve hours in 10% formalin followed by 3 days in 3% phenol prior to embedding is reported to achieve good results [45]. After routine fixation and embedding, permanent wave solution (of the type used in hairdressing), thioglycollate or 10% potassium hydroxide solution can be applied with a cotton swab to the surface of the paraffin block every two or three sections. Lewin *et al.* [46] suggest applying 1% aqueous polysorbate 40 to the cut surface of the block for 1 h at 4°C.

Sections will sometimes adhere to normal slides but when there is nail alone, the material tends to curl as it dries and may fall off. This means that it may be necessary to use gelatinized or 3-aminopropyltriethoxysilane (APES) slides. Given the difficulty of obtaining high-quality sections, it is worth cutting many at different levels to maximize the chance of getting what is needed.

Routine staining with hematoxylin and eosin is sufficient for most cases. Periodic acid-Schiff (PAS) and Grocott's silver stain can be used to demonstrate fungi; a blanchophore fluorochromation selectively delineates fungal walls [47]. More recently, Gomori methanamine silver stain has been advocated following pretreatment with chromic acid and sodium bisulfite [48]. Some of the more representative material in a nail sample for histology for fungus may be in the crumbling substance on the ventral aspect. This can be examined separately but requires a container such as a paper lens container to prevent dispersal of the material and to avoid problems with preparing sections [43]. Toluidine blue at pH 5 allows better visualization of the details of the nail plate [49, 50]. Fontana's argentaffin reaction demonstrates melanin. Hemoglobin is identified using a peroxidase reaction. Prussian blue and Perl stains are not helpful in the identification of blood in the nail as they are specific to the hemosiderin product of hemoglobin breakdown caused by macrophages, which does not occur in the nail [40, 51, 52].

Masson-Goldner's trichrome stain is very useful to study the keratinization process and Giemsa stain reveals slight changes in the nail keratin.

Standard techniques for microwave antigen retrieval for immunohistochemistry, routine polymerase chain reaction studies and TUNEL assays all appear feasible in combined soft tissue and nail specimens [425].

Polarization microscopy shows the regular arrangement of keratin filaments and birefringence is said to be absent in disorders of nail formation such as leuconychia.

Nail matrix and lunula

For simplicity, the nail matrix (syn. intermediate matrix) will be defined as the most proximal region of the nail bed extending to the lunula. This is commonly considered to be the source of the bulk of the nail plate, although further contributions may come from other parts of the nail unit (such as nail growth). Contrast with these other regions helps to characterize the matrix.

The matrix is vulnerable to surgical and accidental trauma; a longitudinal biopsy of greater than 3 mm width is likely to leave a permanent dystrophy [53] (Fig. 1.5). Once matrix damage has occurred, it is difficult to effectively repair it [54–56]. This accounts for the relatively small amount of histological information on normal nail matrix.

It is possible to make distinctions between distal and proximal matrix on functional grounds, given that 81% of cell numbers in the nail plate is provided by the proximal 50% of the nail matrix [57] and surgery to distal matrix is less likely to cause scarring than more proximal surgery. Clinically, the matrix is synonymous with the lunula, or half moon, which can be seen through the nail emerging from beneath the proximal nail fold as a pale convex structure. This is most prominent on the thumb, becoming less prominent in a gradient towards the little finger. It is rarely seen on the toes. The absence of a clinically identifiable lunula may mean that the vascular tone of the nail bed and matrix has obscured it or that the proximal nail fold extends so far along the nail plate that it lies over the entire matrix.

High-resolution magnetic resonance imaging identifies the matrix and dermal zones beneath. Drapé *et al.* [58] described a zone beneath the distal matrix where there is loose connective tissue and a dense microvascular network. It may be the presence of this network that accounts for the variable sign of red lunulae in some systemic conditions [59, 60]. However, the histological observations of Lewin suggested that there is diminished vascularity and increased dermal collagen beneath the matrix contributing

to the pallor which helps identify the area [61]. This has been confirmed in a more recent study utilizing injection of gelatinized Indian ink into amputation specimens [62]. The close association between the nail matrix and joint apparatus results in magnetic resonance imaging changes in tendon sheath and matrix coincidentally [63] and may demonstrate changes in matrix prior to the onset of any clinical nail disease [64].

The thinner epidermis of the nail bed may account for the contrast between the white and pink appearance of the lunula and bed, respectively [65]. Many suggestions have been made to account for the appearance of the lunula [49, 61, 65–68] (Box 1.1).

Macroscopically, the distal margin of the matrix is convex and is easily distinguished from the contiguous nail bed once the nail is removed, even if the difference is not clear prior to avulsion. The nail bed is a more deep red and has surface corrugations absent from the matrix. At the proximal margin of the matrix, the contour of the lunula is repeated. At the lateral apices, a subtle ligamentous attachment has been described, arising as a dorsal expansion of the lateral ligament of the distal interphalangeal joint [69]. Lack of balance between the symmetrical tension on these attachments may explain some forms of acquired and congenital malalignment [70].

Box 1.1 Possible causes for the pale appearance of the lunula

- The surface of the nail is smoother and more shiny proximally.
- The thicker epidermis of the lunula obscures the underlying vasculature.
- The nail attachment at the lunula is less firm, allowing greater refraction and reflection at the nail/soft tissue interface.
- The underlying dermis has fewer capillaries in it.
- The underlying dermis is of looser texture.
- The matrix epithelium in the lunula has more nuclei than the nail bed, making it appear parakeratotic with an altered color.

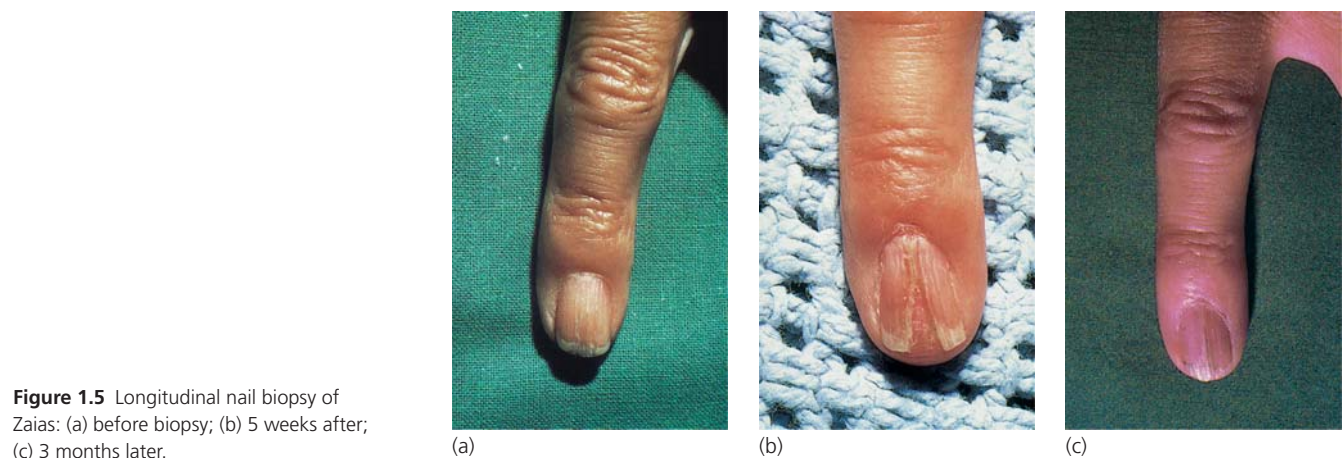


Figure 1.5 Longitudinal nail biopsy of Zaias: (a) before biopsy; (b) 5 weeks after; (c) 3 months later.

Routine histology

The cells of the nail matrix are distinct from the adjacent nail bed distally and the ventral surface of the nail fold, lying at an angle above. The nail matrix is the thickest area of stratified squamous epithelium in the midline of the nail unit, comparable with the hyponychium. There are long rete ridges characteristically descending at a slightly oblique angle, their tips pointing distally. Laterally, the matrix rete ridges are less marked, whereas those of the nail bed nail folds become prominent.

Unlike the overlying nail fold, but like the nail bed, the matrix has no granular layer (Fig. 1.6). The demarcation

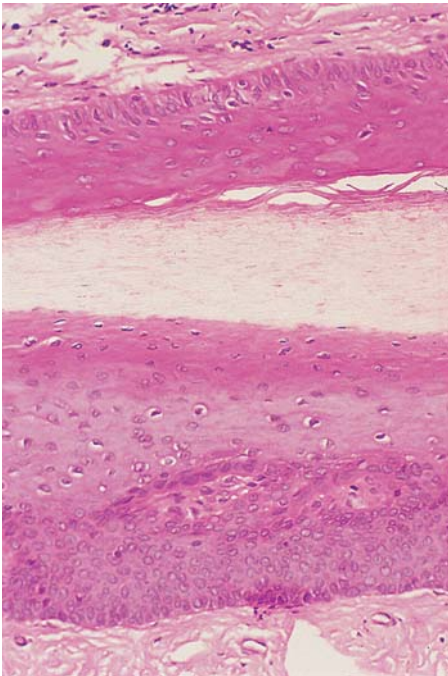


Figure 1.6 A granular layer is absent from the germinal matrix (*lower part*) and the ventral aspect of the proximal nail fold (*upper part*).

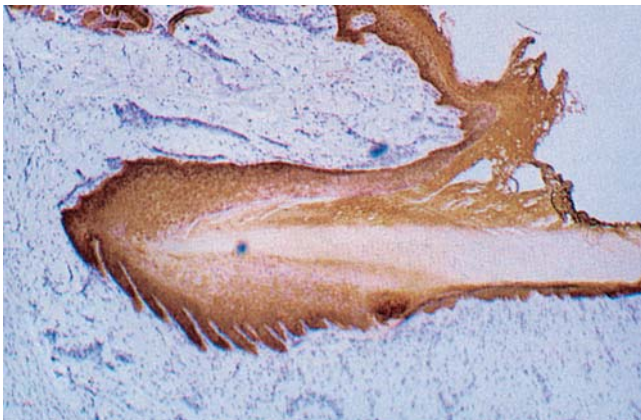


Figure 1.7 Keratin stain of the nail apparatus delineating the epithelial structures of the matrix and proximal nail fold.

between overlying nail fold and matrix is enhanced by the altered morphology of the rete ridges. At their junction at the apex of the matrix and origin of the nail, the first matrix epithelial ridge may have a bobbed appearance like a lopped sheep's tail. PAS staining is marked at both the distal and proximal margins of the intermediate matrix (Fig. 1.7). Distally, there is often a step reduction in the epithelial thickness at the transition of the matrix with the nail bed. This represents the edge of the lunula.

Nail is formed from the matrix as cells become larger and paler and eventually the nucleus disintegrates. There is progression with flattening, elongation and further pallor. Occasionally, retained shrunken or fragmented nuclei persist to be included into the nail plate. Lewis [5] called these "pertinax bodies." They can give an impression of the longitudinal progression of growth in the nail plate (Fig. 1.8).

Melanocytes are present in the matrix where they reach a density of up to 300/mm² [71–75]. This can also be expressed as number of melanocytes per linear millimeter of matrix epidermis examined. Figures for this are a mean of 7.5, median of 7.7 and range of 4–9 [76] (Table 1.3).

Dendritic cells are found in the epibasal layers and most prominent in the distal matrix [73–75]. This point can

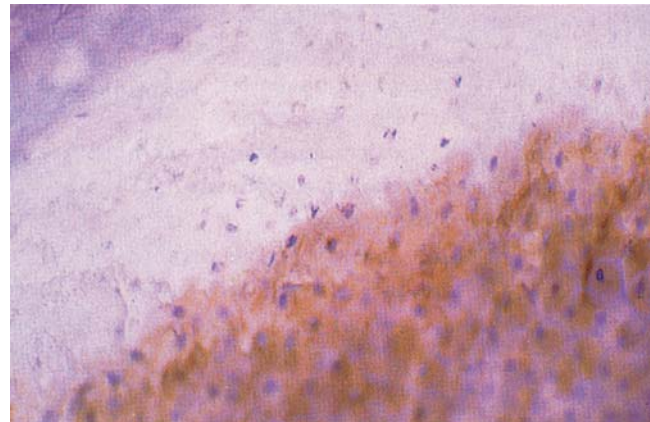


Figure 1.8 Pertinax bodies can be seen as the nuclear remnants within the nail plate.

Table 1.3 Number of melanocytes found per mm of matrix in normal and pathological states.

Pathology	Mean	Median	Range
Invasive melanoma	102	92.5	52–212
<i>In situ</i> melanoma	58.9	51	39–136
Melanotic macule	15.3	14	5–31
Normal control	7.7	7.5	4–9

Reproduced from Amin [76] with permission from Lippincott, Williams and Wilkins.

be refined in terms of the functional status of the melanocytes. Ortonne described melanocytes of the proximal matrix as being in a single compartment of largely dormant cells. Those in the distal matrix are in two compartments, with both a dormant and functionally differentiated population. Longitudinal melanonychia most commonly arises from pigment contributed to the nail plate by these differentiated distal melanocytes. Ortonne also defined a smaller population of nail bed melanocytes, with approximately 25% of the number found in the matrix and none of these were differentiated in terms of DOPA staining. This differs from the observations of de Berker *et al.* [74] where the nail bed was noted to lack melanocyte markers.

The suprabasal location of nail matrix melanocytes can lead to difficulties in the interpretation of histological specimens obtained to exclude dysplasia in instances of melanonychia, given that ascending melanocytes are a sign of dysplasia in normal epidermis. This complication may be related to the fact that the differentiation of melanocytes in the matrix is different from that found elsewhere, given that they typically do not produce pigment in Caucasians and they are detected by the antibody HMB-45, which recognizes melanoma cells and fetal melanocytes but not mature melanocytes [73]. Both HMB-45 and Melan-A are useful markers of nail matrix melanocytes. They are best supplemented with S100 as a means of increasing sensitivity to dermal melanocytes and, in particular, desmoplastic melanoma [77]. In spite of these difficulties in interpretation, melanoma is a relatively rare cause of subungual pigmentation, although it is usually considered necessary to exclude it histologically, particularly in white adults [73, 78].

Melanin in the nail plate is composed of granules derived from matrix melanocytes [9]. Longitudinal melanonychia may be a benign phenomenon, particularly in Afro-Caribbeans: 77% of black people will have a melanonychia by the age of 20 and almost 100% by 50 [79, 80]. The Japanese also have a high prevalence of longitudinal melanonychia, being present in 10–20% of adults [81]. In a study of 15 benign melanonychia cases in Japanese patients, they were found to arise from an increase in activity and number of DOPA-positive melanocytes in the matrix, not a melanocytic nevus [71]. A survey of fingers and toes of 2457 Chinese patients found none with melanonychia beneath the age of 20, 0.6% of those between 20 and 29, increasing to 1.7% in those over 50 [82]. A French study of Caucasians found a 1.4% prevalence in the community and 12.6% prevalence in hospitalized patients [83]. The difference may have in part reflected different clinical sensitivity amongst community and hospital clinicians. In all studies, where mentioned, the thumb and big toe are the most commonly affected digit. Longitudinal melanonychia in Caucasians is more sinister; Oropeza [84] stated that a subungual

pigmented lesion in this group has a higher chance of being malignant than benign.

There is only a thin layer of dermis dividing the matrix from the terminal phalanx. This has a rich vascular supply (see “Vascular supply” below) and an elastin and collagen infrastructure giving attachment to periosteum.

Electron microscopy

Transmission electron microscopy confirms that in many respects, matrix epithelium is similar to normal cutaneous epithelium [85–88]. The basal cells contain desmosomes and hemidesmosomes and interdigitate freely. Differentiating cells are rich in ribosomes and polysomes and contain more RNA than equivalent cutaneous epidermal cells. As cell differentiation proceeds towards the nail plate, there is an accumulation of cytoplasmic microfibrils (7.5–10 nm). These fibrils are haphazardly arranged within the cells up to the transitional zone. Beyond this, they become aligned with the axis of nail plate growth.

Membrane-coating granules (Odland bodies) are formed within the differentiating cells. They are discharged onto the cell surface in the transitional zone and have been thought to contribute to the thickness of the plasma membrane. They may also have a role in the firm adherence of the squamous cells within the nail plate, which is a notable characteristic [89]. The glycoprotein characteristics of cell membrane complexes isolated from nail plate may reflect the constituents of these granules [90].

Mitochondria are degraded during the transitional phase, whilst RNA-containing ribosomes are evident up to the stage of plasma membrane thickening. Vacuoles containing lipid and other products of cytolysis are seen at the transitional stage. Dorsal matrix cells start to show nuclear shrinkage at this point, whereas the nuclei in the matrix remain intact to a higher level.

Electron microscopy has been used to examine the nail plate in detail in fungal disease [91], alopecia areata [92], connective tissue diseases [93] and psoriasis [94].

Nail bed and hyponychium

The nail bed extends from the distal margin of the lunula to the hyponychium. It is also called the ventral matrix, depending on whether or not you believe that it contributes to the substance of the nail plate (see “Nail growth” below). Avulsion of the nail plate reveals a pattern of longitudinal epidermal ridges stretching to the lunula (Fig. 1.9). On the underside of the nail plate is a complementary set of ridges, which has led to the description of the nail being led up the nail bed as if on rails (Fig. 1.10). The small vessels of the nail bed are orientated in the same axis. This can be demonstrated by using corrosion casting from cadaver digits [95] and is

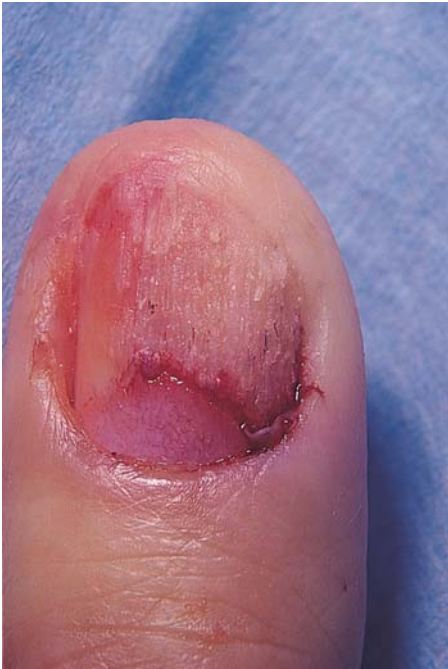

Figure 1.9 The epidermis of the nail bed has longitudinal ridges visible after nail avulsion.

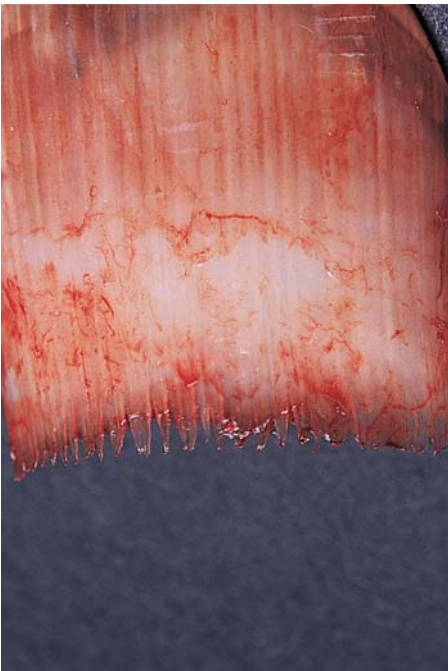


Figure 1.10 The undersurface of the nail plate shows longitudinal ridging which matches that seen on the nail bed. This pattern is lost at the margin of the lunula, where the nail is in continuity with the matrix from which it arises.

clinically manifested by splinter hemorrhages (Figs 1.11, 1.12), where heme is deposited on the undersurface of the nail plate and grows out with it. The free edge of a nail loses the ridges, suggesting that they are softer than

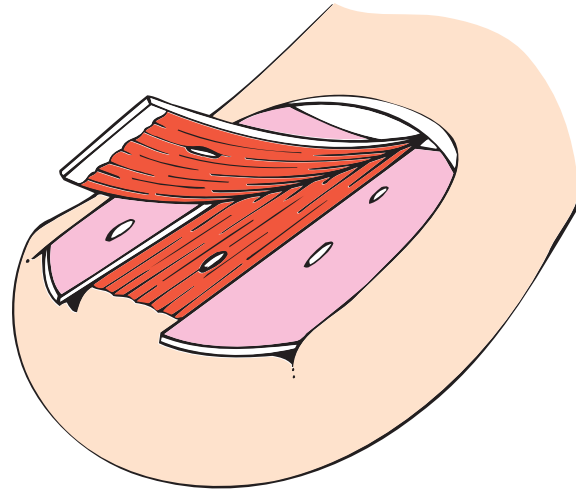


Figure 1.11 The appearance of splinter hemorrhages. Heme from longitudinal nail bed vessels is deposited on the underside of the nail plate. This grows out in the shape of a splinter.

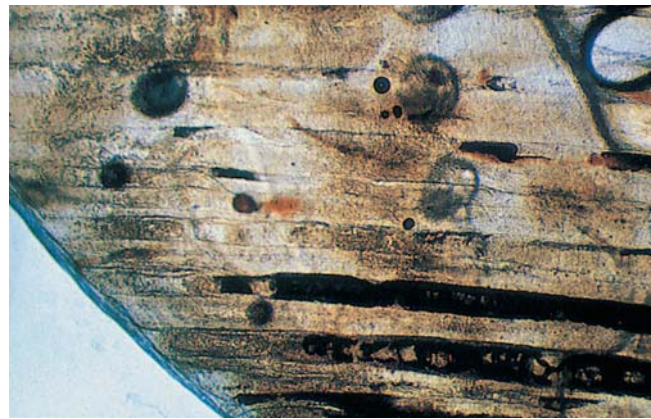

Figure 1.12 The undersurface of the nail has dark-stained blood in the longitudinal grooves corresponding to splinter hemorrhages.

the main nail plate structure. The nail bed also loses these ridges shortly after loss of the overlying nail. It is likely that the ridges are generated at the margin of the lunula on the ventral surface of the nail to be imprinted upon the nail bed.

The epidermis of the nail bed is thin over the bulk of its territory. It becomes thicker at the nail folds where it develops rete ridges. It has no granular layer except in disease states. The dermis is sparse, with little fat, firm collagenous adherence to the underlying periosteum and no sebaceous or follicular appendages [61]. Sweat ducts can be seen at the distal margin of the nail bed using *in vivo* magnification (Fig. 1.13) [96].

The hyponychium lies between the distal ridge and the nail plate and represents a space as much as a surface. Perrin [97] has described an analog of the hair

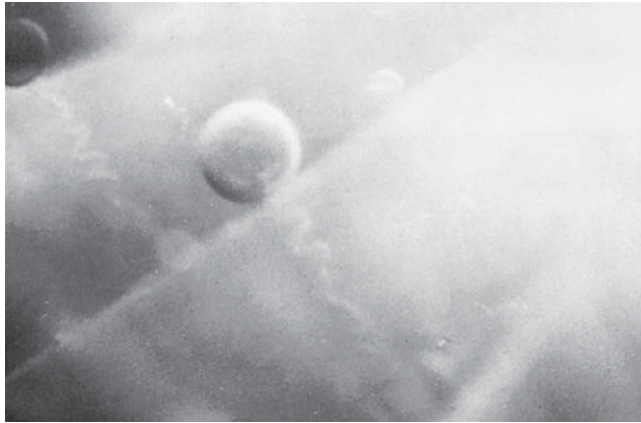


Figure 1.13 Sweat pores in the distal nail bed. Reproduced from Maricq [96] with permission from Wiley-Blackwell.

follicle isthmus at the junction of the hyponychium and nail bed, referred to as the nail isthmus, leading on to the nail infundibulum, which he proposed would replace the term hyponychium. The distal ridge (see “Factors in embryogenesis” above) is seen from the 10th week of gestation onwards. The hyponychium and onychocorneal band may be the focus or origin of subungual hyperkeratosis in some diseases such as pityriasis rubra pilaris (see Table 1.8) or pachyonychia congenita. In these instances, and in some elderly people, it can be thought of as the solenhorn described by Pinkus [98].

Pterygium inversum unguis is a further condition characterized by changes in the distal nail bed and hyponychium [99]. There is tough, fibrotic tissue tethering the free edge of the nail plate to the underlying soft structures. It is found in both congenital [100] and acquired forms [101]. The etiology is not clear. Patterson proposed that it was a combination of a genetic predisposition and microvascular ischemia.

The hyponychium and overhanging free nail provide a crevice which is a reservoir for microbes, relevant in surgery and the dissemination of infection. After 10 min of scrubbing the fingers with povidone-iodine, nail clippings were cultured for bacteria, yeasts and molds [102]. In 19 out of 20 patients, *Staphylococcus epidermidis* was isolated, seven patients had an additional bacteria, eight had molds and three had yeasts. These findings could have significance for both surgeons and patients. However, in a randomized trial of chlorhexidine scrub used with or without a nail brush, the nail brush did statistically diminish the number of colony-forming units obtained from the scrubbed hand [103].

The hand-to-mouth transfer of bacteria is suggested by the high incidence of *Helicobacter pylori* beneath the nails of those who are seropositive for antibodies and have oral carriage. Dowsett *et al.* [104] found that 58% of those with

tongue *H. pylori* had it beneath the index fingernail, representing a significant ($P=0.002$) association.

Nail folds

The proximal and lateral nail folds give purchase to the nail plate by enclosing more than 75% of its periphery. They also provide a physical seal against the penetration of materials to vulnerable subungual and proximal regions.

The epidermal structure of the lateral nail folds is unremarkable, and comparable with normal skin. There is a tendency to hyperkeratosis, sometimes associated with trauma. When the trauma arises from the ingrowth of the nail, considerable soft tissue hypertrophy can result, with repeated infection (such as ingrowing nails).

The proximal nail fold has three parts. Its upper aspect is normal glabrous skin, providing no direct influence upon the nail plate. At the point where its distal margin meets the nail plate, it forms the cuticle (eponychium). In health, the cuticle adheres firmly to the dorsal aspect of the nail plate, achieving a seal. Its disruption may be associated with systemic disorders (collagen vascular) or local dermatoses. In the latter, it may be the avenue for contact allergens or microbes. The ventral aspect of the proximal nail fold is apposed to the dorsal aspect of the nail. It contrasts with the adjacent matrix by being thinner, with shorter rete ridges, and having a granular layer. Keratins expressed in the proximal nail fold may differ on its dorsal and ventral aspects and can contrast with expression elsewhere in the nail unit [15] (see “Nail growth” below).

The proximal nail fold has significance in four main areas.

- It may contribute to the generation of the nail plate through a putative dorsal matrix on its ventral aspect.
- It may influence the direction of growth of the nail plate by directing it obliquely over the nail bed.
- Nail fold microvasculature can provide useful information in some pathological conditions.
- When inflamed, it can influence nail plate morphology as seen in eczema, psoriasis, habit tic deformity and paronychia.

The first two issues are dealt with in the section on nail growth (see “Nail growth” below), the latter under vasculature (see “Vascular supply” below) and “The Nail in Dermatological Disease” (see Chapter 6).

Immunohistochemistry of periungual tissues

Keratins

The most extensive immunohistological investigations of the nail unit have utilized keratin antibodies. The nail plate [14, 105], human embryonic nail unit [8, 14, 106], accessory digit nail unit [107, 108] and adult nail unit [15, 47, 106] have all been examined (Table 1.4).

Table 1.4 Keratins in the nail unit.

Type II keratins	Type I keratins	Nail fold	Nail bed	Matrix
K1	K10	+	-	+
K5	K14	+	+	-
K6a		-	+	+
K6b	K16	-	+	+
	K17	-	-	+
K81 (Hb1)	K31 (Ha1)	-	-	+
K85 (Hb5)	K32 (Ha2)	-	-	+
K86 (Hb6)	K34 (Ha4)	-	-	+
	K38 (Ha8)	-	-	+
Other keratins not found or not tested for in the nail unit				
K6c (K6e/h)	K15			
K2 (K2e)	K9			
K3	K12			
K4	K13			
K7	K18			
K8	K19			
K71 (K6irs1)	K20			
K72 (K6irs2)	K23			
K73 (K6irs3)	K24			
K74 (K6irs4)	K25 (K25irs1)			
K75 (K6hf)	K26 (K25irs2)			
K76 (K2p)	K27 (K25irs3)			
K77 (K1b)	K28 (K25irs4)			
K78 (K5b)	K33a (Ha3-I)			
K79 (K6l)	K33b (Ha3-II)			
K80 (Kb20)	K35 (Ha5)			
K82 (Hb2)	K36 (Ha6)			
K83 (Hb3)	K37 (Ha7)			
K84 (Hb4)	K39 (Ka35)			
	K40 (Ka36)			

Using monospecific antibodies, de Berker *et al.* [15, 107] detected keratins 1 and 10 in a suprabasal location in the matrix and noted their absence from the nail bed (Fig. 1.14) (see “Nail growth” and “Nail plate” below). Keratins 1 and 10 are “soft” epithelial keratins found suprabasally in normal skin [109] and characteristic of cornification with terminal keratinocyte differentiation. Their absence from

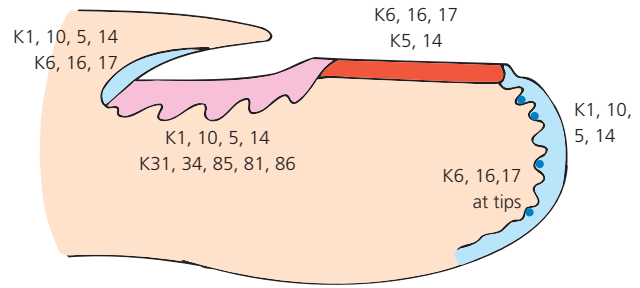


Figure 1.14 Distribution of keratins in the human periungual and subungual tissues.

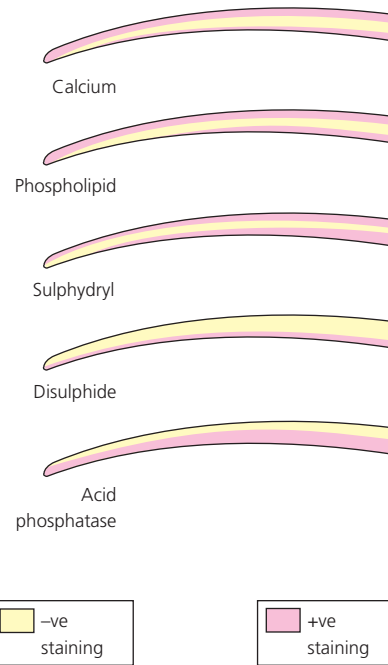


Figure 1.15 The histochemistry of the human nail plate. Nail plates were sectioned and stained. Index, calcium; middle, phospholipid; ring, sulfydryl; little, disulfide; thumb, acid phosphatase. Reproduced from Jarrett and Spearman [138] with permission from the American Medical Association.

normal nail bed is reversed in disease where nail bed cornification is often seen, alongside development of a granular layer and expression of keratins 1 and 10 [110]. The development of a granular layer in subungual tissues can be interpreted as a pathological sign in nail histology, seen in a range of diseases and probably associated with changes in keratin expression [111].

Ha-1 (K31), a “hard” keratin, is found in the matrix. Keratin 7 has been found at other sites in the nail unit and hair follicle, whereas Ha-1, detected by the monoclonal antikeratin antibody LH TRIC 1, is limited to the matrix of the nail (Fig. 1.15) and the germinal matrix of the hair follicle [16, 107]. Other hard hair/nail keratins have been highlighted as limited to the matrix where K85 (hHb5), K34 (hHa4), K81 (hHb1) and K86 (hHb6) have all been found

within the conventional boundaries of the matrix. Keratin 19 is probably not found in the adult matrix [8, 15, 47]. However, Moll *et al.* [8] did detect keratin 19 at this site in 15-week embryo nail units. Keratin 19 is also found in the outer root sheath of the hair follicle and lingual papilla [14].

The colocalization of hard and soft keratins within single cells of the matrix has been observed by several workers in bovine hoof [112] and human nail [15, 113, 114], suggesting that these cells are contributing both forms of keratin to the nail plate. This dual differentiation continues into *in vitro* culture of bovine hoof matrix cells [113]. Culture of human nail matrix confirms the persistence of hard keratin expression [115, 116].

Markers for keratins 8 and 20 are thought to be specific to Merkel cells in the epidermis. Positive immunostaining for these keratins has been noted by Lacour *et al.* [106] in adult nail matrix and de Berker *et al.* [15] in infant accessory digits. Some workers have failed to detect Merkel cells and while it seems likely that they are present in fetal and young adult matrix, it may be that the cells are less common or absent as people age [117].

The nail bed appears to have a distinct identity with respect to keratin expression. Keratins 6, 16 and, to a lesser degree, 17 are all found in the nail bed and are largely absent from the matrix [15]. This finding has gained clinical significance with the characterization of the underlying fault in some variants of pachyonychia congenita where abnormalities of nail bed keratin lead to a grossly thickened nail plate. Mutations in the gene for keratin 17 have been reported in a large Scottish kindred with the PC-2, or Jackson-Lawlor, phenotype [118, 119]. There is a cross-over with steatocystoma multiplex where the same mutation of keratin 17 may cause this phenotype which appears to be independent of the specific keratin 17 mutation [120–122]. Mutations in the gene coding for K6b produce a phenotype seen with K17 gene mutations [123]. Mutations in the K6a [124] and K16 [119] genes have been reported in PC-1, originally described as the Jadassohn-Lewandsky variant of pachyonychia congenita.

Expression of keratins 6, 16 and 17 extend beyond the nail bed onto the digit pulp and are thought to match the physical characteristics of this skin which is adapted to high degrees of physical stress [125]. In particular, expression of keratin 17 is found at the base of epidermal ridges, which might also support the idea that this keratin is associated with stem cell function.

It is important to recognize that the hard keratins responsible for the characteristics of nail tissue are the product of an interaction between underlying mesenchyme fibroblasts and the overlying epithelium. Hard nail keratins can be induced both *in vivo* and *in vitro* using nail matrix mesenchyme and non-nail epithelium [126, 127]. Induced expression of hard keratin is not the same as producing a nail, as the product of these experiments

can be a poorly organized structure only recognizable as nail in immunohistochemical terms [128]. The specific nature of the nail mesenchyme may correspond to the presence of nail mesenchyme versican, where versican is a chondroitin sulfate proteoglycan and a member of the lecticans family [129].

Non-keratin immunohistochemistry

Haneke [47] has provided a review of other important immunohistochemically detectable antigens. Involucrin is a protein necessary for the formation of the cellular envelope in keratinizing epithelia. It is strongly positive in the upper two-thirds of the matrix and elsewhere in the nail unit [130] and weakly detected in the suprabasal layers. Pancornulin and sciellin are also detected in the matrix [130]. The antibody HHF35 is considered specific to actin. It has been found to show a strong membranous staining and weak cytoplasmic staining of matrix cells [47].

In the dermis, vimentin was strongly positive in fibroblasts and vascular endothelial cells. Vimentin and desmin were expressed in the smooth muscle wall of some vessels. S100 stain, for cells of neural crest origin, revealed perivascular nerves, glomus bodies and Meissner's corpuscles distally.

Filaggrin could not be demonstrated in the matrix in Haneke's work or by electron microscopy [14]. However, Manabe and O'Guin [131] have detected the coexistence of trichohyalin and filaggrin in monkey nail, located in the area they term the "dorsal matrix" which is likely to correspond to the most proximal aspect of the human nail matrix as it merges with the undersurface of the proximal nail fold. Kitahara and Ogawa [114] have identified filaggrin in the human nail in the same location and O'Keefe *et al.* [132] have found trichohyalin in the "ventral matrix" of human nail, which is synonymous with the nail bed. Manabe noted that these two proteins coexist with keratins 6 and 16, which are more characteristic of nail bed than matrix. It is argued that filaggrin and trichohyalin may stabilize the intermediate filament network of K6 and K16, which are normally associated with unstable or hyperproliferative states. Where pathological mutations of the filaggrin gene and those for keratin 16 coexist, the phenotype may be more severe than in the parent with the original isolated keratin gene mutation [133].

The plasminogen activator inhibitor (PAI) type 2 has been detected in the nail bed and matrix where it has been argued that it may have a role in protecting against programmed cell death [134]. The basement membrane zone of the entire nail unit has been examined, employing a wide range of monoclonal and polyclonal antibodies [108]. Collagen VII, fibronectin, chondroitin sulfate and tenascin were among the antigens detected.

Table 1.5 Analysis of nail unit basement membrane zone using monoclonal and polyclonal antibodies.

	Digit 1			Digit 2					Digit 3		
	Nail apparatus			Nail apparatus							
	Fold	Matrix	Bed	HN	Proximal phalangeal skin	Fold	Matrix	Bed	HN	Split skin	Intact skin
Monoclonal antibody											
LH7:2	+	+	+	+	+	+	+	+	+	Epi	+
L3d	+	+	+	+	+	+	+	+	+	Epi	+
Co1 IV	+	+	+	+	+	+	+	+	+	Epi	+
GB3	+	+	+	+	+	+	+	+	+	Epi	+
LH24	+	+	+	+	+	+	+	+	+	Epi	+
LH39	+	+	+	+	+	+	+	+	+	Epi	+
GDA	+	+	+	+	+	+	+	+	+	Epi	+
Tenascin	+	+	+	+	+	+	+	+	+	Epi	+
a6	+	+	+	+	+	+	+	+	+	Epi	+
G71	+	+	+	+	+	+	+	+	+	Epi	+
Polyclonal antibody											
Fibronectin	-	-	-	-	-	-	-	-	-	-	-
Laminin	+	+	+	+	+	+	+	+	+	Derm	+
BP 220 kDa	+	+	+	+	+	+	+	+	+	Epi	+
EBA 250 kDa	+	+	+	+	+	+	+	+	+	Derm	+
LAD 285 kDa	+	+	+	+	+	+	+	+	+	Epi	+
LAD 7kDa	+	+	+	+	+	+	+	+	+	Derm	+

Derm, dermis; Epi, epithelium; HN, hyponychium.

All except tenascin were present in a quantity and pattern indistinguishable from normal skin. Tenascin was absent from the nail bed, which was attributed to the fact that the dermal papillae are altered or considered absent (Table 1.5).

Nail plate

The nail plate is composed of compacted keratinized epithelial cells. It covers the nail bed and intermediate matrix and is curved in both the longitudinal and transverse axes. This allows it to be embedded in nail folds at its proximal and lateral margins, which provide strong attachment and make the free edge a useful tool. This feature is more marked in the toes than the fingers. In the great toe, the lateral margins of the matrix and nail extend almost halfway around the terminal phalanx. This provides strength appropriate to the foot (Fig. 1.16). The nail appears as a layered structure when examined histologically with silver stain [5], with ultrasound [135], using optical coherence tomography [136] or scanning electron microscopy [137]. The different orientation of keratin fibrils within these layers appears to lend characteristics of both toughness and flexibility.

Lewis [5] described a silver stain that delineates the nail plate zones. Three regions of nail plate have been histochemically defined [138] (see Fig. 1.15). The dorsal plate has a relatively high calcium, phospholipid and sulfhydryl group content. It has little acid phosphatase activity and is physically hard. The phospholipid content may provide some water resistance. The intermediate nail plate has a high acid phosphatase activity, probably corresponding to the number of retained nuclear remnants. There is a high number of disulfide bonds and low content of bound sulfhydryl groups, phospholipid and calcium. Controversy suggests that the ventral nail plate may be a variable entity [139]. Jarrett

and Spearman [138] described it as a layer only one or two cells thick. These cells are eosinophilic and move both upwards and forward with nail growth. With respect to calcium, phospholipid and sulfhydryl groups, it is the same as the dorsal nail plate. It shares a high acid phosphatase and frequency of disulfide bonds with the intermediate nail plate.

Ultrasound examination of *in vivo* and avulsed nail plate suggests that it has the physical characteristics of a bilamellar structure [140]. There is a superficial dry compartment and a deep humid one. This has been given as evidence against the existence of a ventral matrix contribution to the nail plate. Synchrotron x-ray microdiffraction has been used to identify a trilamellar structure, where the dorsal and ventral fibers run transversely and the central fibers run in the longitudinal axis of the nail plate, occupying 70% of nail plate thickness. This lamination enhances nail resistance to tear and fracture forces in multiple axes [141].

The upper surface of the nail plate is smooth and may have a variable number of longitudinal ridges that change with age. These ridges are sufficiently specific to allow forensic identification and the distinction between identical twins [142]. Lyonization studies suggest that there is a sustained pattern of X-inactivation within the progenitor cells of single longitudinal nail ridges [143]. The ventral surface also has longitudinal ridges that correspond to complementary ridges on the upper aspect of the nail bed (see "Nail bed and hyponychium" above) to which it is bonded (Fig. 1.17). These nail ridges may be best examined using polarized light. They can also be used for forensic identification [144], as may blood groups from fragments of nail plate [145].

The nail plate gains thickness and density as it grows distally [12] according to analysis of surgical specimens. *In vivo* ultrasound suggests that there may be an 8.8%

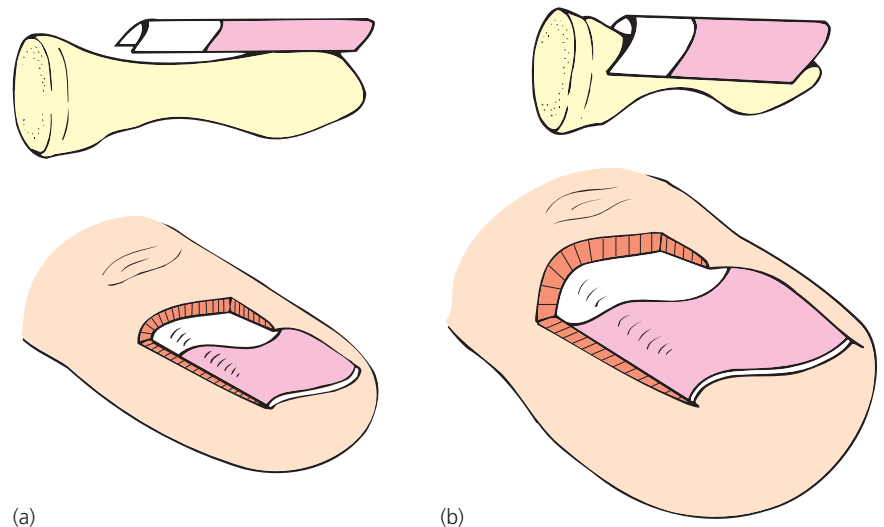


Figure 1.16 Nail plate association with soft tissue and bone in the finger and toe. (a) In the finger, the nail plate has modest transverse curvature and shallow association with soft tissues. (b) In the great toe, the nail plate has more marked transverse curvature and deep soft tissue association. This makes it appropriate to the foot but also accounts for the tendency to ingrow and the need for deep lateral extirpation at lateral matricectomy.




Figure 1.17 Scanning electron micrograph of the nail bed demonstrating longitudinal ridges.

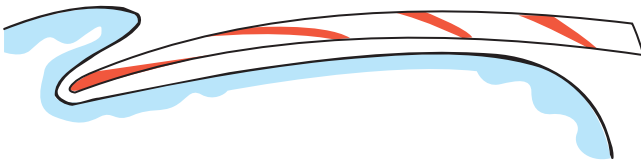


Figure 1.18 Shaded areas represent 7-day periods of nail growth, separated by 1 month with transition of nail from horizontal to oblique axis over 4 months.

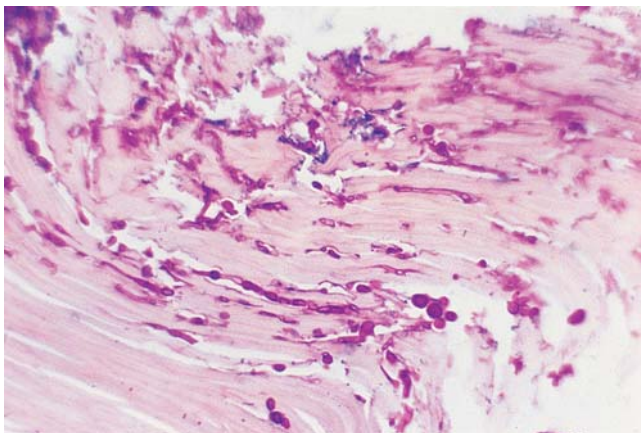


Figure 1.19 Fungal spores and hyphae can be seen in the stained section of a nail clipping taken from a nail with onychomycosis.

reduction in thickness distally [146]. A thick nail plate may imply a long intermediate matrix. This stems from the process whereby the longitudinal axis of the intermediate matrix becomes the vertical axis of the nail plate (Fig. 1.18). Other factors, like linear rate of nail growth [147], vascular supply, subungual hyperkeratosis and drugs, also influence thickness.

In clinical practice, histology of the nail plate may be useful in the identification of fungal infections in culture-negative specimens [41, 47] (Fig. 1.19). It may also be used to identify the dorsoventral location of melanin in

the nail clipping of a longitudinal melanonychia and hence allow prediction of the site of melanocyte activity in the intermediate matrix [148, 149]. Sonnex *et al.* [4] describe the histology of transverse white lines in the nail.

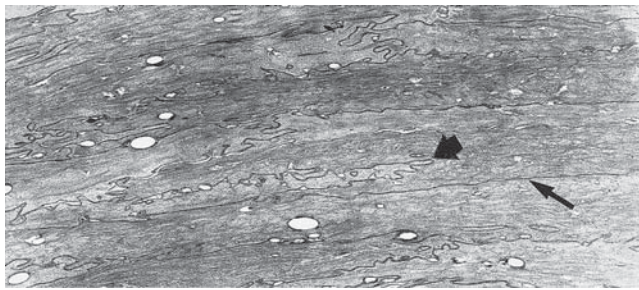
Germann *et al.* [150] utilized a form of tape-stripping in conjunction with light microscopy to examine dorsal nail plate corneocyte morphology in disease and health. They found that conditions of rapid nail growth (psoriasis and infancy) resulted in smaller cell size. Nail keratin protein has been sampled and quantified using a similar tape-stripping method followed by colorimetric quantification [151].

Electron microscopy

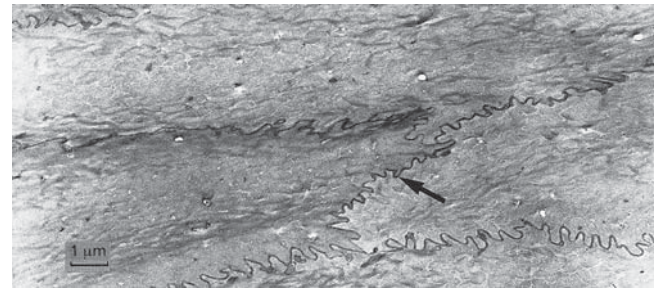
Scanning electron microscopy has added to our understanding of onychoschizia [152, 153] as well as basic nail plate structure [154, 155]. In the normal nail, corneocytes can be seen adherent to the dorsal aspect of the nail plate. In cross-section, the compaction of the lamellar structure is visible. Both these features can be seen to be disrupted in onychoschizia following repeated immersion and drying of the nail plates. Scanning electron microscopy has also been used for assessing the location of fungal invasion into the nail plate [156, 157] although the lack of differential staining seen in routine light microscopy may mean that the latter is usually more useful.

Transmission electron microscopy has been used to identify the relationship between the corneocytes of the nail plate [89]. Using Thierry's tissue-processing techniques, material for the following description has been provided. Cell membranes and intercellular junctions are easily discernible (Fig. 1.20). Even though at low magnification one can differentiate the dorsal and intermediate layers of the nail plate, the exact boundary is unclear using transmission electron microscopy. Cells on the dorsal aspect ($34 \times 60 \times 2.2 \mu\text{m}$) are half as thick as ventral cells ($40 \times 50 \times 5.5 \mu\text{m}$), with a gradation of sizes in between. In the dorsal nail plate, large intercellular spaces are present corresponding to ampullar dilations (Figs 1.21, 1.22). These gradually diminish in the deeper layers and are absent in the ventral region. At this site, cells are joined by complete folds, membranes of adjacent cells appearing to penetrate each other to form "anchoring knots."

Corneocytes of the dorsal nail plate are joined laterally by infrequent deep interdigitations. The plasma membranes between adjacent cell layers are more discretely indented, often with no invaginations (see Fig. 1.20). In the deeper parts of the nail plate, the interdigitations are more numerous but more shallow (see Fig. 1.20). No tight or gap junctions are seen in either of the major nail layers in this series [89] although they were identified previously

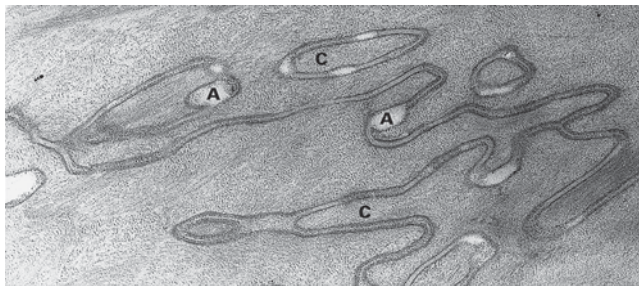


(a)

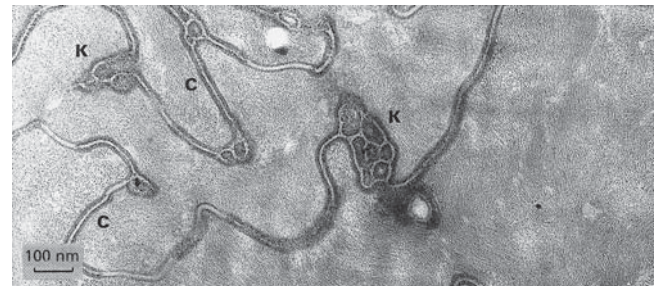

(b)

Figure 1.20 (a) Transmission electron micrograph of the upper part of the nail plate. The corneocytes are flattened and joined laterally by infrequent deep interdigitations (*broad arrow*). (b) The cell membranes between adjacent cell layers are discretely indented and in parts without invaginations: Thiery's technique. Courtesy of G. Achten.

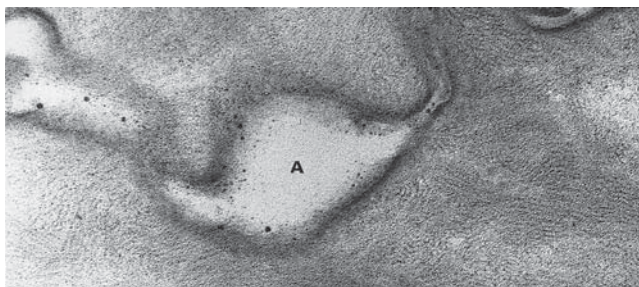


(a)

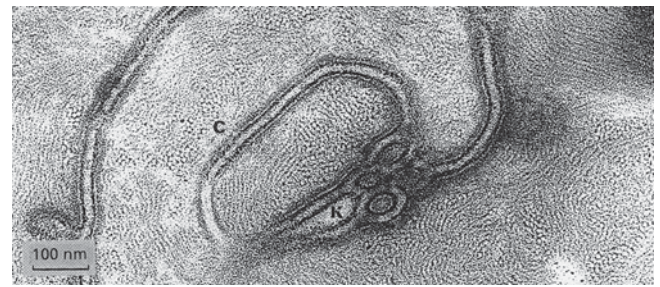

(b)

Figure 1.21 (a) Upper part of the nail plate showing ampullar dilations (A). (b) Lower part of the nail plate showing anchoring knots (K). The only cell-to-cell coupling observed (C) is a desmosome. Courtesy of G. Achten.



(a)



(b)

Figure 1.22 (a,b) Upper part of the nail plate as shown in Fig. 1.20, in greater detail. Courtesy of G. Achten.

by Forslind and Thyresson [154]. The intercellular material is homogeneous and separated from the cell membrane by two thin electron-dense lines. The space between the cell membranes varies from 25 nm to 35 nm (see Figs 1.20, 1.22). No complete desmosomal structures are seen.

Nail bed cells show considerable infolding and interdigitation at their junction with the nail plate cells (Fig. 1.23). They are polygonal and show no specific alignment. They are between 6 and 20 μm across and show neither tight nor gap junctions. They do, however, have desmosomal connections of the type seen in normal epidermis (Fig. 1.24).

Cryoelectron microscopy allows examination of fractured intracellular components in great detail without the artefacts normally associated with the chemical processing and coating of traditional electron microscopy (EM) techniques. Using this approach, the trichocyte intermediate filaments have been examined in rat vibrissae. Although these may differ from human nail in some respects, they will share the designation of hard keratins and so allow some transferable observations. The main observation was that the classic keratin fibril structure is the same, but a further arrangement of satellite proteins "decorates" the keratin. These proteins are suspected of being high sulfur amino acid proteins lending the keratin

some of its rugged character [158], possibly through enhancing cross-linking between keratins and increasing their stability [159].

Using different preparation techniques, other workers have demonstrated other anatomical details. On the

cytoplasmic side of the cell membranes of nail plate cells lies a layer of protein particles [85, 86, 160]. Other staining techniques suggest that the single type of intercellular bond described by Parent *et al.* [89] may be a spot desmosome [161].

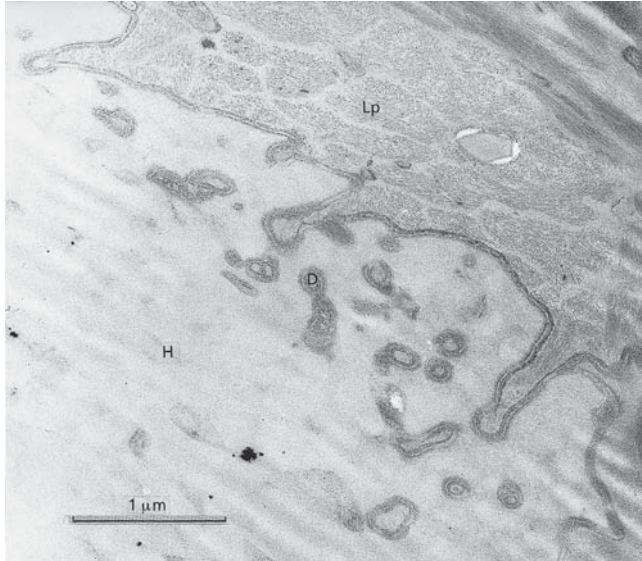


Figure 1.23 Corneocytes of the lowest part of the nail plate (Lp) sending out numerous digitations (D) penetrating the hyponychial nail bed cells (H). Courtesy of G. Achten.

Vascular supply

Arterial supply

The vascular supply of the finger is considered in detail here. Many of the anatomical principles may be extended to the anatomy of the foot and toe, whilst details can be sought elsewhere [6].

The radial and ulnar arteries supply deep and superficial palmar arcades that act as large anastomoses between the two vessels. From these arcades extend branches aligned with the phalanges. Four arteries supply each digit, two on either side. The dorsal digital arteries are small and arise as branches of the radial artery. They undertake anastomoses with the superficial and deep palmar arches and the palmar digital vessels before passing distally into the finger. The palmar digital arteries provide the main blood supply to the fingers. They receive contributions from the deep and superficial palmar arcades. Although paired, one is normally dominant

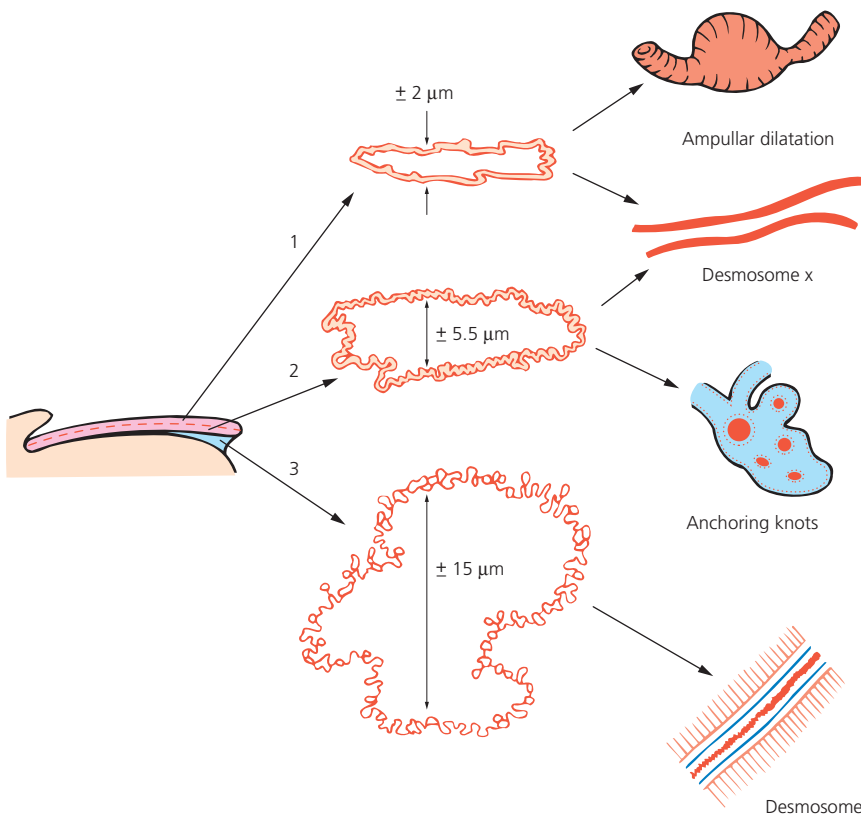


Figure 1.24 Intercellular junctions of the three parts of the nail: 1, upper plate; 2, lower plate; 3, hyponychial ventral nail with desmosome as seen by Thiery's technique. Courtesy of G. Achten.

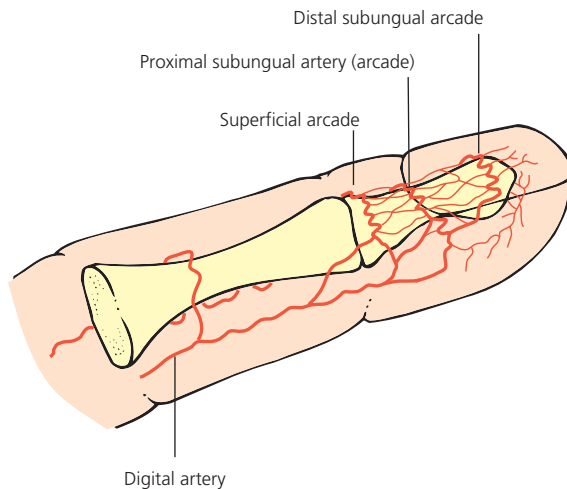


Figure 1.25 Arterial supply of the distal finger.

[162]. They anastomose via dorsal and palmar arches around the distal phalanx. The palmar arch is located in a protected position, beneath the maximal padding of the finger pulp and tucked into a recess behind the protruberant phalangeal boss (Fig. 1.25). This is of functional value as it protects against occlusion of the blood supply when the fingers exert maintained grip.

The dorsal nail fold arch (superficial arcade) lies just distal to the distal interphalangeal joint. It supplies the nail fold and extensor tendon insertion. It is tortuous, with numerous branches to the intermediate nail matrix. Its transverse passage across the finger can be roughly located by pushing proximally on the free edge of the nail plate. This produces a faint crease about 5 mm proximal to the cuticle and is both the cul de sac of the proximal nail fold and the line of the dorsal nail fold arch.

The subungual region is supplied by distal and proximal subungual arcades, arising in turn from an anastomosis of the palmar arch and the dorsal nail fold arch. Helpful studies on adults and fetuses have been performed by Flint [163], Wolfram-Gabel and Sick [62] and Sangiorgi [95]. The latter made use of corrosion casting on cadaver digits to demonstrate the complex microvasculature.

The tortuosity of the main vessels in the finger is a notable feature. Vessels may turn through 270° and resemble a coiled spring [162]. Functionally, this can be interpreted as protection against occlusion by kinking in an articulated longitudinal structure.

Venous drainage

Venous drainage of the finger is by deep and superficial systems. The deep system corresponds to the arterial supply. Superficially, there exist the dorsal and palmar digital veins, which are in a prominent branching network, particularly on the dorsal aspect. However, in the microsurgical tech-

niques needed to restore amputations, it appears that distally, the palmar superficial veins are largest [164].

Although the arterial supply to the nail unit is substantial, the matrix will tolerate only limited trauma before scarring [53]. A longitudinal biopsy of greater than 3 mm is likely to leave a permanent dystrophy. Equally, it appears to need a precise, not just abundant, blood supply. Non-vascularized split-thickness nail bed grafting is moderately successful for the nail bed, but not for intermediate matrix [55]. This is in the presence of otherwise adequate local blood supply at sites of previous trauma. Toenail matrix grafts can be made successfully if they are transplanted with associated soft tissue and a venous pedicle [54]. The local arterial supply is then anastomosed through this pedicle.

Effects of altered vascular supply

Impaired arterial supply can have a considerable effect upon the finger pulp and nail unit. Lynn *et al.* [165] claimed that there was almost complete correlation between occluded arteriographic findings and the presence of paronychia infection or ulceration, ridged brittle fingernails or phlyctenular gangrene. Samman and Strickland [166] reviewed the nail dystrophies of 41 patients with features of peripheral vascular disease. In this uncontrolled study, they observed that onycholysis, Beau's lines, thin brittle nails and yellow discoloration were all attributable to ischemia in the absence of other causes. It has also been suggested that congenital onychodysplasias may result from digital ischemia *in utero* [35]. Immobilization might be associated with diminished local blood supply and has been noted to reduce nail growth [167]. Conversely, the increased growth associated with arteriovenous shunts may reflect the role of greater blood flow [168]. Clubbing constitutes a change in both the nail and nail bed. It is believed that it arises secondary to neurovascular pathology. Postmortem studies suggest that it is due to increased blood flow with vasodilation rather than vessel hyperplasia [169].

Nail fold vessels

The nail fold capillary network [170] is seen easily with a $\times 4$ magnifying lens, dermatoscope [171] or ophthalmoscope. The latter should be set at +40 and the lens held very close to a drop of oil on the nail fold. The network is similar to the normal cutaneous plexus in health, except that the capillary loops are more horizontal and visible throughout their length. The loops are in tiers of uniform size, with peaks equidistant from the base of the cuticle (Fig. 1.26) [172]. The venous arm is more dilated and tortuous than the arterial arm. There is a wide range of morphologies within the normal population [173]. Features in some disorders may be sufficiently gross to be useful without magnification, erythema and hemorrhages being the most obvious.

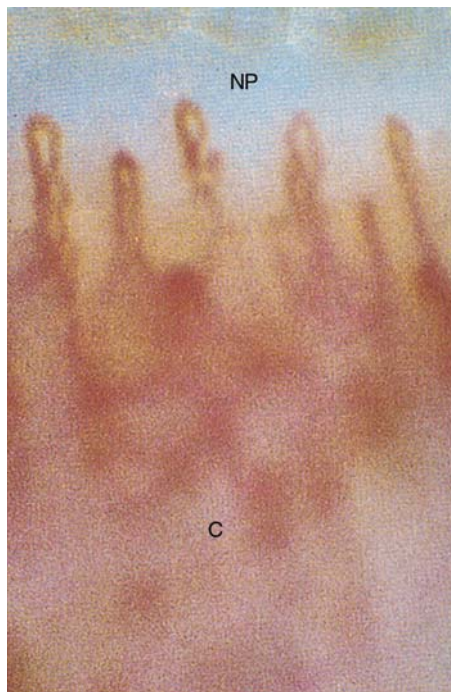


Figure 1.26 Capillary loops visible in the proximal nail fold. NP, nail plate; C, cuticle.

In the first 10 years of life, the pattern of nail fold vessels is immature [174]. Microscopy of small vessels in adulthood can be of diagnostic value in some connective tissue diseases [175, 176]. Pathological features include venous plexus visibility, density of capillary population, avascular fields, hemorrhages, giant capillaries and cessation of blood flow following cooling. When determined quantitatively, using television microscopy, Studer found it possible to distinguish between systemic and disseminated cutaneous lupus erythematosus, and between localized and systemic sclerosis [177]. In patients with undifferentiated connective tissue disease, it may be possible to predict which will progress to systemic sclerosis by undertaking quantitative analysis of nail fold vessel dimensions. The larger the vessels, the more likely that the condition is going to progress [178]. The mechanism of dilated vessel evolution may in part arise from impaired fibrinolysis, macroglobulinemia and cryoglobulinemia [172].

Fibrinogen may increase in subjects in renal failure on continuous ambulatory peritoneal dialysis. This has been proposed as a cause for the changes seen in nail fold vessels of such patients in proportion to abnormalities of urea and uric acid clearances [179]. Nail fold vessel changes may also occur in psoriasis and appear to correlate with nail pitting, onycholysis and periungual psoriatic plaques [180]. However, it can be imagined that clinical or subclinical elements of cutaneous psoriasis may represent the underlying change in vessel pattern.

The capillary networks in the normal nail fold of toes and fingers have been compared using videomicroscopy. This has revealed a greater density of capillaries in the toenail fold but with a reduced rate of flow [181]. The exact pattern of an individual's nail fold vessels can be used as an identifying characteristic [182].

Intravenous bolus doses of Na-fluorescein dye have been followed through nail fold microscopy [183]. There is rapid and uniform leakage from the capillaries in normal subjects to within 10 μm of the capillaries. It is suggested that a sheath of collagen may prevent diffusion beyond this point. The same procedure has been followed in patients with rheumatoid arthritis, demonstrating decreased flow rates and abnormal flow patterns, but no change in vessel leakage [184]. Static nail fold microscopy has been used for the investigation of Raynaud phenomenon [185]. It is possible to assess vascular toxicity affecting nail fold vessels following chemotherapy, using the same method [186]. A small number of laboratories are also able to employ *in vivo* capillary pressure measurement for nail fold vessels [187]. Video studies can be used to measure red cell velocity in nail fold capillaries [188] which has been used as a means of quantifying vascular damage in subjects with systemic sclerosis [189]. Systemic sclerosis and other microvascular disorders can be usefully assessed using laser Doppler, which can be combined with videocapillaroscopy for further detail [190].

Ultimately, histological information on the vessels and tissue of the nail folds may be helpful. The technique and benefits of nail fold biopsy have been described [191]. Amyloid deposits, subintimal hyalinosis and severe dermal fibrosis are cited as useful supplementary information yielded by biopsy.

Glomus bodies

A glomus is defined as a ball, tuft or cluster, a small conglomeration or plexus of cavernous blood vessels. In the skin it is an end-organ apparatus in which there is an arteriovenous anastomosis bypassing the intermediary capillary bed. This anastomosis includes the afferent artery and the Sucquet–Hoyer canal. The latter is surrounded by structures including cuboidal epithelioid cells and cells possibly of smooth muscle or pericyte origin (Zimmerman type). These are surrounded by a rich nerve supply and then the efferent vein which connects with the venous system outside the glomus capsule.

The nail bed is richly supplied with glomus bodies and their presence in histological specimens should be interpreted in this context, rather than assuming that their abundance has some pathological significance. These are neurovascular bodies which act as arteriovenous anastomoses (AVA). AVAs are connections between the arterial

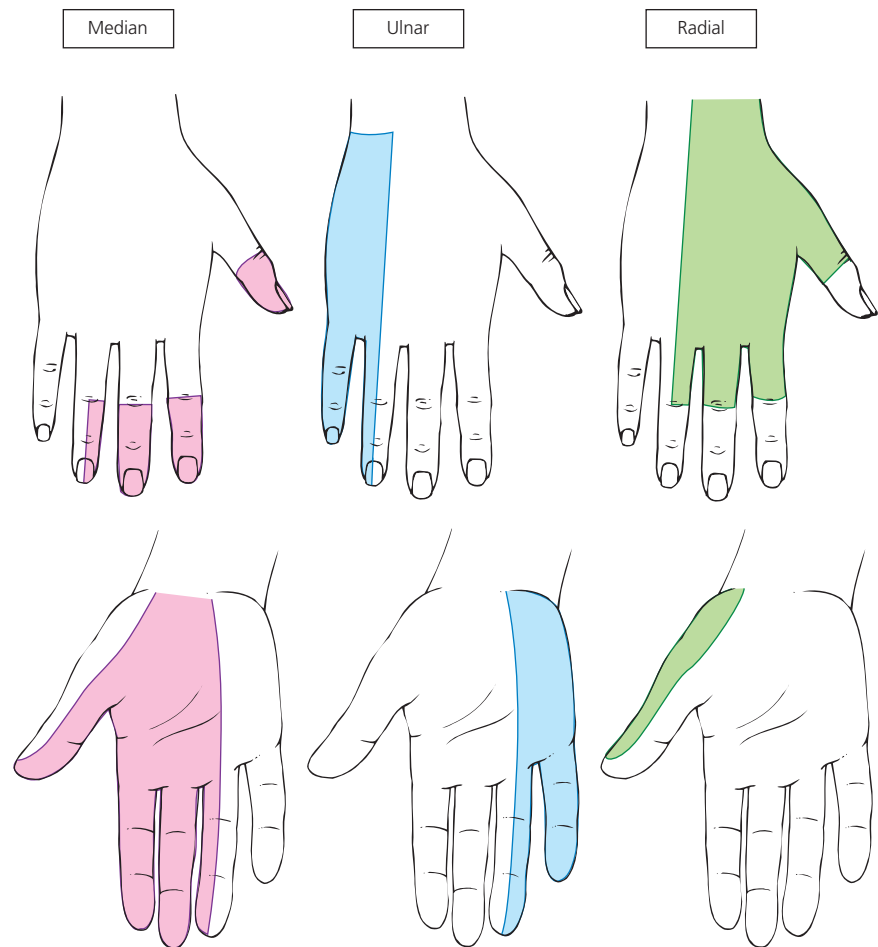


Figure 1.27 Sensory supply of the hand.

and venous side of the circulation with no intervening capillaries. Each glomus body is an encapsulated oval organ 300 μm long composed of a tortuous vessel uniting an artery and venule, a nerve supply and a capsule. It contains many modified large muscle cells, resembling epithelioid cells, and cholinergic nerves. Digital nail beds contain 93–501 glomus bodies per cm^3 . They lie parallel to the capillary reservoirs which they bypass. They are able to contract asynchronously with their associated arterioles such that in the cold, arterioles constrict and glomus bodies dilate. They can thus serve as regulators of capillary circulation, acquiring the name “the peripheral heart of Masson” [192]. They are particularly important in the preservation of blood supply to the peripheries in cold conditions.

Nerve supply

The periungual soft tissues are innervated by dorsal branches of paired digital nerves. Wilgis and Maxwell [193] stated that the digital nerve is composed of three major fascicles supplying the digit tip, with the main branch passing under the nail bed and innervating both nail bed and

matrix [194]. Winkelmann [195] showed many nerve endings adjacent to the epithelial surface, mainly in the nail folds. Serial dissections of cadaver hands demonstrate that there is often dual sensory innervation of the nail unit on the dorsal aspect of the digit which is relevant when attempting anesthesia with ring block [196] (Fig. 1.27).

Comparative anatomy and function

The comparative anatomy of the nail unit can be considered from two aspects. There is the comparison of the nail with other ectodermal structures and most particularly hair and its follicle. The nail can also be viewed in an evolutionary setting alongside the hoof and claw. In this respect, the functional qualities of the nail or its equivalent are exemplified by the morphological differences in different species.

The human nail can be considered to have many mechanical and social functions, the most prominent of which are:

- fine manipulation
- scratching

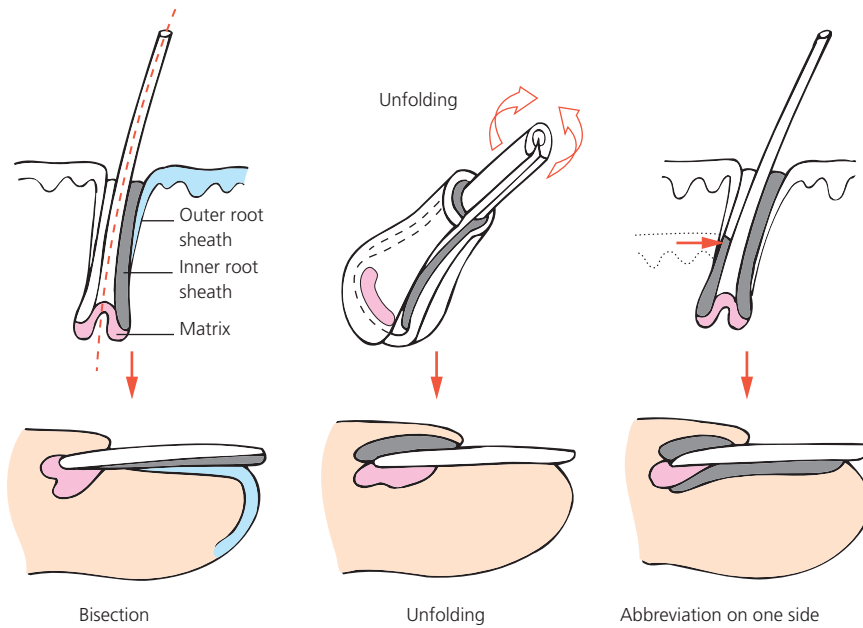


Figure 1.28 Models of hair follicle/nail unit homology.

- physical protection of the extremity
- as a vehicle for cosmetics and esthetic manipulation.

In comparison with other species, the first three functions have evolved with detailed physical modifications in the form of the hoof, claw and nail.

The nail and other appendages

An appendage is formed through the interaction of mesoderm and ectoderm, which in differentiated states usually means the interaction between dermis and epidermis. Those appendages most closely related to nail include hair and tooth. There are many shared aspects of different appendages, illustrated by diseases, morphology and analysis of the biological constituents.

Congenital abnormalities of hair, tooth and nail coexist in several conditions, underlining their common ground. Ectodermal dysplasias represent a group of disorders in which these appendages, as well as eccrine sweat glands, may be affected in association with skin changes.

In some conditions, only two of the appendages seem to be affected, such as the hair and nail changes described by Barbareschi *et al.* [197] or tooth and nail changes in the hypodontia and nail dysplasia syndrome (Witkop tooth and nail syndrome) [198, 199]. Alternatively, the same genetic defect, such as a mutation in the gene for keratin 17, may underlie two separate diseases where the nail is abnormal in one phenotype and the hair follicle in the other [200]. Presumably an additional factor determines which of the possible phenotypes prevails.

While diseases illustrate interrelationships between appendages, further common ground can be defined in terms of morphology. Achten [201] noted that the nail unit was comparable in some respects to a hair follicle, sec-

tioned longitudinally and laid on its side (Fig. 1.28). Perrin has also described the area between the nail bed and hyponychium as the nail isthmus, to emphasize the resemblance to the isthmus of the hair follicle [202]. The hair bulb was considered analogous to the intermediate nail matrix and the cortex to the nail plate. As a model to stimulate thought, this idea is helpful. It also encourages the consideration of other manipulations of the hair follicle that might fit the analogy more tightly. The nail unit could be seen, as in Figure 1.28, as an unfolded form of the hair follicle, producing a hair with no cortex, just hard cuticle. Scanning electron microscopy of the nail confirms that its structure is more similar to compacted cuticular cells than cortical fibers. A third model could represent the nail unit as a form of follicle abbreviated on one side, providing a modified form of outer root sheath to mold and direct nail growth in the manner of the proximal nail fold (see Fig. 1.28). The matrix and other epithelial components of tooth can be seen in a similar comparative light and even the lingual papilla, which shares some keratin expression with the nail, shows some morphological similarities with the nail and hair follicle [131].

In pachyonychia congenita where alopecia is found, transverse sections of scalp follicles reveal dyskeratosis of the outer root sheath, attracting comparisons with the nail bed [203]. In some diseases immunological focus is shared between nail matrix and hair follicle, as in lichen planus and alopecia areata. This suggests common ground in immunological identity, which could be related to specific keratins. Ito [204] described a pattern of relative immune privilege in the proximal nail matrix similar to that seen in the hair follicle which might normally play a part in blocking the autoimmune attention of white cells. Defects

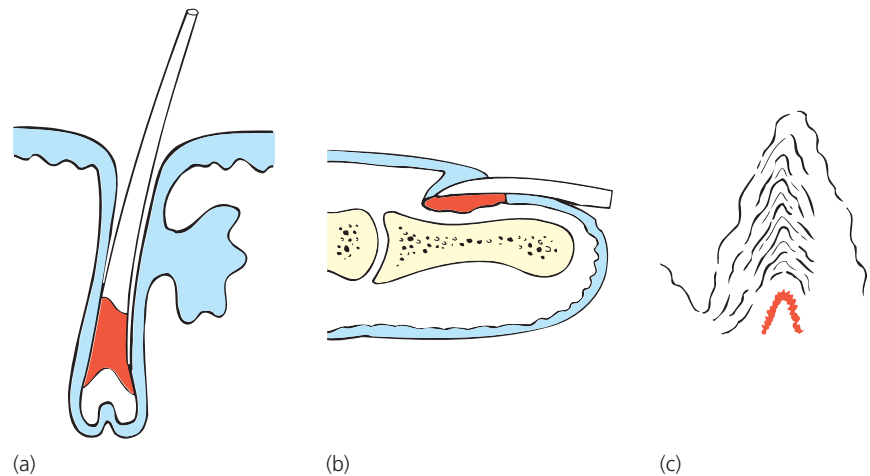


Figure 1.29 Localization of immunoreactivity of the hard keratin Ha-1 in (a) the anagen hair follicle ($\times 200$), (b) the nail unit ($\times 10$) and (c) the human lingual papilla ($\times 500$). After Westgate *et al.* [16] with permission from Wiley-Blackwell.

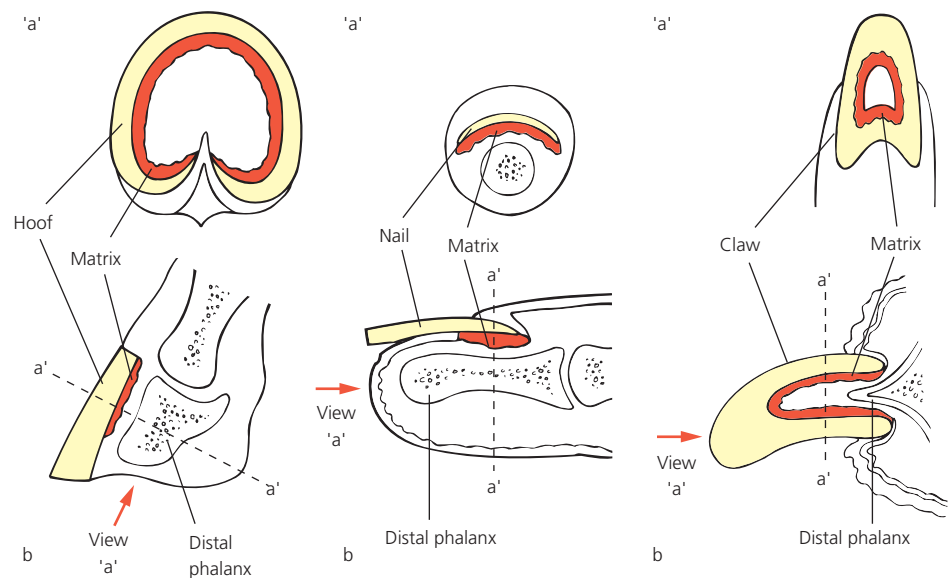


Figure 1.30 Comparison of hoof, nail and claw and their matrix (red) origins.

in this could open the way to a common path and manifestation of disease (Fig. 1.29).

The character of the nail plate and hair has led to their use in assays of circulating metabolites. They both lend themselves to this because they are long-lasting structures that may afford historical information. Additionally, their protein constituents bind metabolites and they provide accessible specimens. This allows both hair and nail to be used in the detection of systemic metabolites which may have disappeared from the blood many weeks previously (see “Exogenous materials in nail analysis” below).

Phylogenetic comparisons

The structure of claws and hooves and their evolutionary relationship to the human nail have been well reviewed [205]. In higher primates, nails have developed with the acquisition of manual dexterity. Other mammals do not

possess such flattened claws from which nails have evolved (Fig. 1.30).

The lowest evolutionary level at which claws are seen is in the amphibia [206]. The matrix contributes the greatest mass to the nail plate in humans and other primates, with a lesser contribution from the dorsal and nail bed matrices. Claws are formed from an extensive germinal matrix, which occupies the territory of the nail bed in primates [207]. It is sometimes described as comprising a dorsal and ventral component [208], where differential growth of these components is responsible for the curve. The orientation of the matrix and hence growth of nail may be influenced by the shape of the underlying phalanx [207]. It is postulated that their sharp tip is produced by a dominant midline matrix.

Claws are significantly more three-dimensional than nails and this is achieved by the coronal distribution of

matrix tissue around the terminal phalanx. If this is recognized, the comparisons between other hard keratinized animal appendages such as horns and beaks become obvious. All these structures share physical and biochemical attributes specific to their biological character and function. In some respects, the upper beak has more in common with the morphology of the nail than do claws and comparisons have been made in both structure and constituents between beak and claw [209]. The disorders of claws presenting to one university veterinary service demonstrated a preponderance of trauma and bacterial infection [210] (Table 1.6). This differs from dermatological experience in humans where complaints are usually attributable to dermatoses such as psoriasis or eczema or to fungal infection.

Claws and talons are harder than nails, probably because of the content of calcium as crystalline hydroxyapatite within keratinocytes (cf. human nails)

Table 1.6 Proportion of diagnoses of dogs with disorders of the claws from a study of 196 affected dogs.

Diagnosis	% of cases
Bacterial paronychia	35.5
Trauma	22
Neoplasia	14
Fungal	4
Lupoid	4
Bullous disorder	4
Demodicosis	1
Systemic illness	0.5
Idiopathic	15

Adapted from Scott and Miller [210] with permission from Lingua.

[211]. A study of onychomadesis (nail shedding) in dogs looked at mineral constituents of normal claws, human nails and the hooves of cows and pigs [212]. It appears that there is no particular pattern of homology between different species in this respect (Table 1.7).

Keratin immunohistochemistry for epithelial and hair/nail keratins has made it easier to identify the types of keratins found in animal appendages. Such studies illustrate substantial homology between the canine claw and human nail [213] and, to a lesser extent, similarities with the reptilian claw [214]. The anatomy of the equine hoof allows comparison with human nails but there are also substantial differences, including the presence of some keratins, K42 and K124, not found in human tissue [215]. In some instances, animal mutants have helped corroborate the role of a specific keratin in the human phenotype. Mice with mutation of the gene expressing K75 (K6hf) demonstrate features similar to humans with pachyonychia congenita where the human K75 gene is also known to be at fault [216].

Orientation of keratin microfibrils may contribute to their strength. Fourier-transform Raman spectroscopy shows that bird and reptile claws are made up mainly of β -sheeted keratin in contrast to the predominantly α -helical keratin conformation of human nail keratin [217].

Claws and nails have more in common with each other than they do with hooves. However, the bovine hoof has provided a useful source of research tissue for experiments on colocalization of hard and soft keratin expression in matrix cells and the characteristics of matrix cells in tissue culture [113]. Hooves have evolved to provide a "bulky claw" for weight bearing and locomotion over hard ground [218]. It is interesting that among the prosimians, tarsiers have nails on all digits apart from the second and third digits of the hindlimb which bear claws [205]. In hooves, the nail fold and root have been displaced backwards with a forwards extension of the nail bed. The hard "soft plate" under hooves

Table 1.7 Mineral content (expressed as mg/kg, standard error in parentheses).

Mineral	Dog claw	Porcine hoof	Bovine hoof	Human nail
Calcium	771 (83)	1699 (50)	1481 (25)	671 (806)
Magnesium	238 (21)	220 (10)	300 (11)	100 (121)
Iron	268 (31)	73 (8)	17 (1.1)	29 (64)
Potassium	430 (53)	1050 (30)	785 (53)	–
Sodium	676 (50)	–	523 (16)	2400 (1800)
Copper	6.3 (0.5)	4.6 (0.13)	8.3 (0.3)	29 (89)
Zinc	129 (5)	160 (4)	128 (1.7)	106 (154)

Adapted from Harvey and Markwell [212] with permission from Wiley-Blackwell.

is produced from an area equivalent to the subungual part of the claw. In some animals, cloven hooves have only developed on the digits that touch the floor. In horses, the single large hoof is produced from the third digit. The typical hoof shape is due to a deep, backwardly placed root matrix with the ventral plate formed from the subungual epidermis. The microfibrils in hooves are from 25 to 100nm in diameter. The orientation of the fibrils is along the main axis of the hoof, similar to the hair cortex.

Physiology

Nail production

Definition of the nail matrix

In the first section, we have attempted to define the matrix in anatomical terms, assisted by histology and immunohistochemistry illustrating regional differentiation within the nail unit and in particular with respect to keratin expression. These measures provide indirect information on aspects of nail production and help us to address the central question of which tissues produce nail plate and which simply support and surround it. There is considerable biological and clinical relevance to this point, given that the focus of embryogenesis, damage repair and disease processes are better understood if the exact location of nail formation is established.

The location or existence of nail matrix tumors is often poorly defined because there is a lack of awareness of the site and pivotal role of nail matrix disturbance in the creation of abnormal nail morphology. Equally, diagnostic biopsies or sampling can be misdirected if the likely source of nail abnormalities is not recognized at the outset; a clear prognosis following surgery or trauma cannot be given unless the clinician understands the relative contributions of the nail matrix and nail bed.

In spite of the importance of the question, controversy remains as to the relative contributions of the three putative nail matrices to the nail plate. The three contenders are the dorsal, intermediate and ventral matrices (Fig. 1.31). The first is part of the proximal nail fold, the last is the nail bed. Lewis [5] claimed that the nail plate demonstrated a three-layer structure on silver staining and that each layer derived from one of the possible matrices. This remains one of the indirect histological methods of defining the matrix which have been supplemented by more direct measures of nail plate production.

Markers of matrix and nail bed proliferation

Zaias and Alvarez [11] disagreed with Lewis on the basis of *in vivo* autoradiographic work on squirrel monkeys, where dynamic aspects of the process were being examined. Tritiated thymidine injected into experimental animals was only incorporated into classic matrix (or intermediate matrix, to use Lewis's terminology). Norton used human subjects in further autoradiographic studies

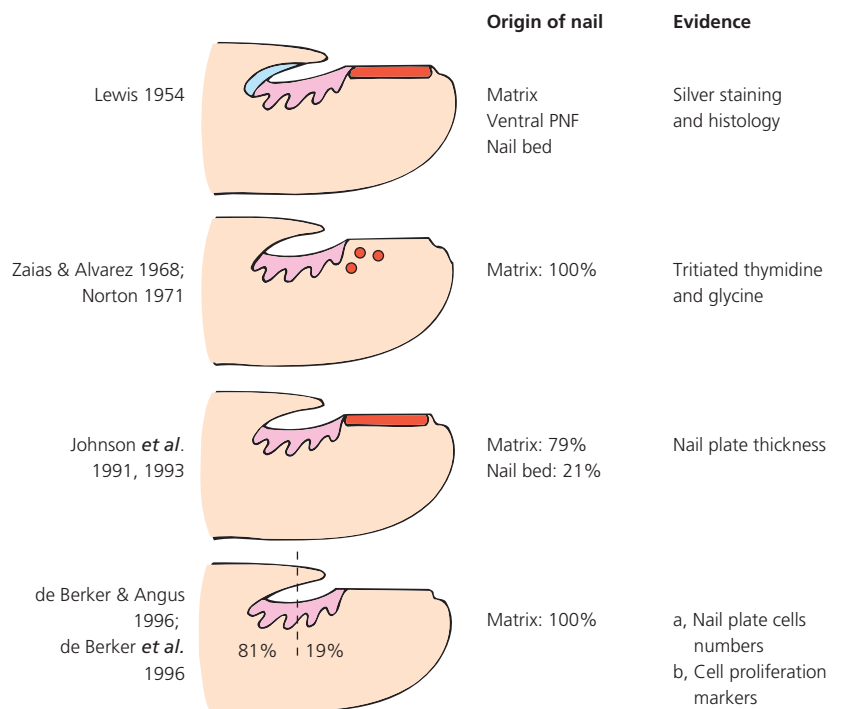


Figure 1.31 Theories of nail plate origin.

[219]. Although there was some incorporation of radiolabeled glycine in the area of the nail bed, it was in a poorly defined location, making clear statements impossible.

Immunohistochemical techniques allow us to examine proliferation markers in human tissue, without the drawbacks of autoradiography. Antibodies to proliferating cell nuclear antigen and to the antigen K1-67 associated with cell cycling have been used on longitudinal sections of healthy and diseased nail units [202, 220]. Both markers demonstrate labeling indices in excess of 20% for the nail matrix, in contrast with 1% or less for the nail bed in healthy tissue. The differences are less marked according to Perrin [202], with an index of 21% in the matrix and 5% in the nail bed. In psoriatic nail and onychomycosis, the labeling index of nail bed rises to >29%. While these indices do not directly measure nail plate production, a very low index for normal nail bed is consistent with other studies suggesting that the nail bed is an insignificant player in normal nail production. The situation may change in disease and the definition of nail plate becomes difficult when substantial subungual hyperkeratosis produces a ventral nail of indeterminate character [139].

Nail plate indicators of matrix location

Johnson *et al.* [12, 221] dismissed the evidence of Zaias, claiming that the methodology was flawed. They examined nail growth by the measurement of change in nail thickness along a proximal to distal longitudinal axis. They demonstrated that 21% of nail plate thickness in traumatically lost big toenails was gained as the nail grew over the nail bed. This was taken as evidence of nail bed contribution to the nail plate.

A similar study developed this observation with histology of the nail plate taken at fixed reference points along the longitudinal nail axis and comparing nail plate thickness at these sites with numbers of corneocytes in the dorsoventral axis of the nail [57]. The result of this was to confirm the observation that the nail plate thickens over the nail bed but that this is not matched by an increase in nail cells. In fact, the number of cells reduces by 10%, but this was not of statistical significance. These combined studies may be reconciled if we propose that the shape of cells within the big toenail becomes altered with compaction as the nail grows. This is likely where clinical experience shows that the nail develops transverse rippling where there is habitual distal trauma.

If the loss of nail cell numbers along the nail bed is a genuine observation, it might suggest that cells are being shed from the nail surface. This is compatible with the status of nail plate as a modified form of stratum corneum. Heikkilä *et al.* [222] provide evidence in support of this where nail growth was measured by making indentations on the nail surface and measuring the change

in the volume of these grooves as they reach the free edge. There was a reduction of volume by 30–35%, which was taken as evidence of a nail bed contribution to the nail plate. However, this interpretation is less believable than the possibility that the nail is losing cells from the surface, and histology of grooves in a similar study shows that this is likely to be the case [223].

Flow cytometry of matrix cells

Haneke and Kiesewetter (unpublished data) have performed flow cytometry on matrix cells obtained during surgical lateral matrixectomy for ingrowing nail. This demonstrated that 94% of the matrix cells were in G0/1 phase, 3.4% in S phase and 2% in G2+M phase. The corresponding values for matrix connective tissue cells were 96.6% for G0/1, 2.3% for S and 1.1% for G2+M phases. The differences between matrix cells and associated connective tissue were statistically significant. This suggests that the percentage of cells in the phase of DNA synthesis and mitosis (S plus G2+M phases) in the nail matrix is much lower than that of hair matrix cells and equals that of the cells in the hair root sheath. However, the values may have been underestimated in this experiment if the matrixectomies failed to sample the most basal matrix cells, as can happen in this operation. Also, this technique was not applied to distinguish nail bed from matrix and does not directly address the issue of which tissues are primarily involved in nail plate production.

Clinical markers of matrix location

The clearest demonstration of nail generation is the effect of digit amputation at different levels. Trauma within the lunula is more likely to cause irreparable nail changes than that of the nail bed [224]. This observation is true for adults and children alike, although the likelihood of normal regrowth is greater in children with similar trauma [225]. Longitudinal biopsies of the entire nail unit within the midzone of the nail are said to cause a chronic split if the width of the biopsy exceeds 3 mm [53]. However, there are several factors in addition to the width of the biopsy that can contribute to scarring with longitudinal biopsies and smaller biopsies in the midzone can also give long-term problems.

In some circumstances, most commonly old age, there is a pattern of subungual hyperkeratosis associated with nail thickening which gives the impression of a nail bed contribution to the nail plate. Historically, this has been referred to as the solenhorn (Fig. 1.32) and considered a germinal element of the hyponychium. Samman considered this issue in the context of a patient with pustular psoriasis [139] and concluded that the ventral nail is a movable feast, manifesting itself in certain pathological circumstances.

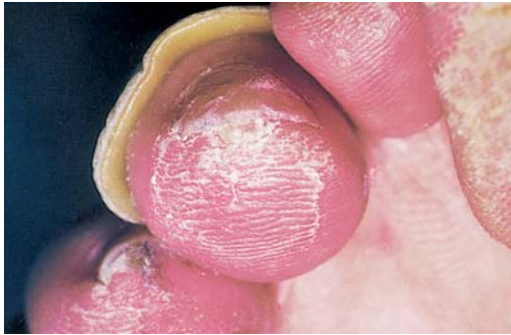

Figure 1.32 Vestigial solenhorn seen as focal subungual hyperkeratosis.

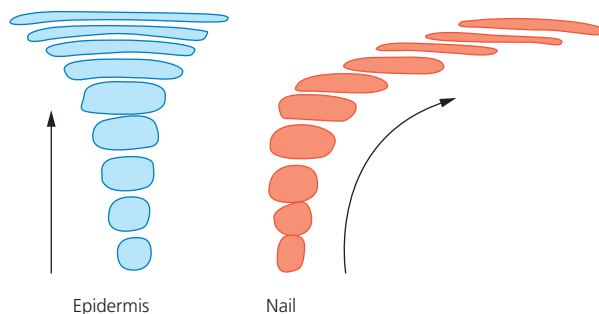


Figure 1.33 Change in shape and direction of the cells within the epidermis and the nail matrix.

Normal nail morphology

The main issues in normal nail morphology are: why is it flat and why is the free edge rounded and not pointed? Factors influencing nail plate thickness are dealt with earlier (see “Nail plate” above).

Why does the nail grow out straight?

The first question was addressed in an article by Kligman [226] entitled “Why do nails grow out instead of up?.” His hypothesis was that the proximal nail fold acts to mold the nail as it moves away from the matrix, giving an oblique growth path. From observing other keratinizing epithelia, he noted that growth is normally parallel to the axis of keratinization. From this, he considered it anomalous that nails grow out along the nail bed and not upwards (Fig. 1.33). A patient with the nervous habit of chewing off the proximal nail fold did not provide an adequate experiment to demonstrate its function. However, when given the opportunity to autograft 5mm matrix punch biopsies from digit to forearm, nail tissue was seen to grow upwards like a cutaneous horn. This was presented as proof of the hypothesis.

Baran was in disagreement [227] and presented evidence from surgical experience in the removal of the proximal nail fold and the lack of subsequent change in the nail. He also challenged the validity of Kligman’s experiment on the basis that the underlying terminal

phalanx has a great influence upon nail growth [38] and this was lost in transplanting the graft to the arm.

Since this debate, bone morphogenetic protein has emerged as part of the TGF- β family of mediators. It is found in many different forms with a range of morphogenetic roles. In relation to the formation of the nail unit, it has been proposed that there is a two-way process whereby it is supportive of nail unit development, but equally that the nail unit plays a part in the regeneration of the distal phalanx when it is lost through trauma in infancy [30] and these processes may in part be mediated through BMP4.

Further examples of ectopic nail growth still leave room for disagreement [228] and the relevance of acquired bone and nail changes occurring in tandem has its own literature. Carpal tunnel syndrome can result in abnormal nails alongside acroosteolysis and ischemic skin lesions [229]. The reversal of many of the skin and nail features on treatment of the carpal tunnel compression suggests a neurovascular origin to both nail and bone changes in this pattern of acroosteolysis. Where the etiology of the osteolysis is termed idiopathic, there are also nail changes [230]. It seems unlikely that these cases represent a specific influence of bone upon nail formation, but rather that both structures are responding to some undefined agent. There is a wide range of primary disorders in which secondary osteolysis and altered nails are recognized complications [230].

All the models demonstrating the influence of the different periungual tissues and bone upon the nail are flawed. Those above do not acknowledge the adherent quality of the nail bed as an influential factor, or the guiding influence of the lateral nail being embedded in the lateral nail folds. The role of the nail bed becomes manifest in psoriasis affecting the toes where the combination of subungual hyperkeratosis and trauma can produce upward-growing nails in the presence of an apparently normal proximal nail fold. It is reasonable with our present knowledge to consider horizontal nail growth as being attributable to more than one part of the nail unit (Fig. 1.34).

What determines the contour of the free edge?

The second issue is why are nails rounded and not pointed? This has generally been accepted as being a function of the shape of the lunula, as illustrated in Figure 1.35. The mechanism of this is seen in Figure 1.34. Given that nails are growing continuously throughout life, it is possible to argue that we rarely see the true free edge but rather observe the eroded or manicured outline. However, there are two instances when we see the genuine free edge: at birth and with regrowth following avulsion (Fig. 1.36). These appear to follow the margin of the lunula. Finally, the nail bed may have some role in

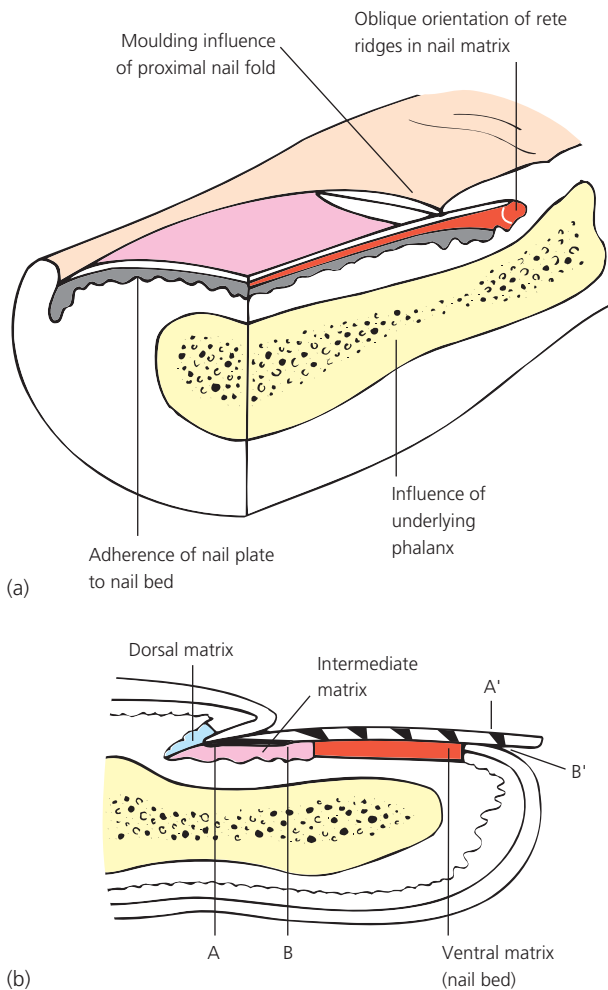


Figure 1.34 Why do nails grow out instead of up? (a) (i) Guiding restraint of proximal nail fold; (ii) inductive influence of underlying phalanx; (iii) containment by lateral nail folds; (iv) adherence to nail bed. (b) Generation of nail plate marked at monthly intervals. The horizontal axis of the intermediate axis is transformed into an oblique axis. Proximal matrix, A, generates dorsal nail A'. Distal intermediate matrix, B, generates ventral nail B'.

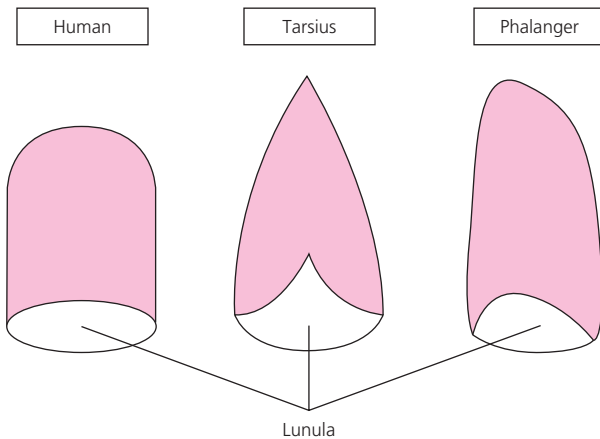


Figure 1.35 Relationship of lunula to nail tip shape.

determining the shape of the free edge. Trauma to the nail bed can result in nail plate dystrophies, giving the free edge a scalloped contour. This can be corrected with nail bed grafts [55].

Nail growth

Measurement

The literature on nail growth has relied on quantification. A range of methods has been employed, mostly requiring the imprint of a fixed reference mark on the nail and measuring its change in location relative to a fixed structure separate from the nail after a study period. Gilchrist and Dudley Buxton [231] made a transverse scratch about 2 mm from the most distal margin of the lunula. This distance was then measured using a rule and magnifier. Changes in the distance with time provided a record of growth rate. There have been variants of this, with the scratch being made at the convex apogee of the lunula and subsequent measurements made with reference to the lunula [232] or alternatively, making a scratch a fixed 3 mm from the cuticle and noting the change with time [233] (Fig. 1.37). The precision of these methods was increased by the introduction of magnified photographs before and after, and comparison of the photographs [234]. This was modified further by Sibinga [235] who increased the photographic magnification from a factor of 6 to 35. This made it possible to conduct studies of nail growth over a period as short as 1 month.

Babcock [234] understood the problems in the methods involving the lunula and cuticle as reference points, as they both might conceivably change during the study. The method suggested for overcoming this was inventive, but unacceptable these days for ethical reasons. The nail was marked with a deep scratch which was then filled with bismuth amalgam. This made it radiopaque and allowed comparison with the underlying bony reference points on x-ray. A follow-up x-ray, after refilling the scratch with amalgam, allowed growth estimation. The concern over variation in the non-nail plate reference point can be partly surmounted by using two reference points and possibly halving the error. This can be done by making a scratch or laser incision [236] at the tip of the lunula and measuring the distance to the distal limit of the nail plate attachment, visible through the nail plate. Subsequent measurements are made from both the lunula and the edge of nail plate attachment. Their sum should always be equal as a way of verifying the method (Fig. 1.38).

Surface imaging of the nail, exploiting natural irregularities, can be used in lieu of marks placed by the observer. This has been reported by de Doncker and Piérard [237] in a study of nail growth during itraconazole therapy. The

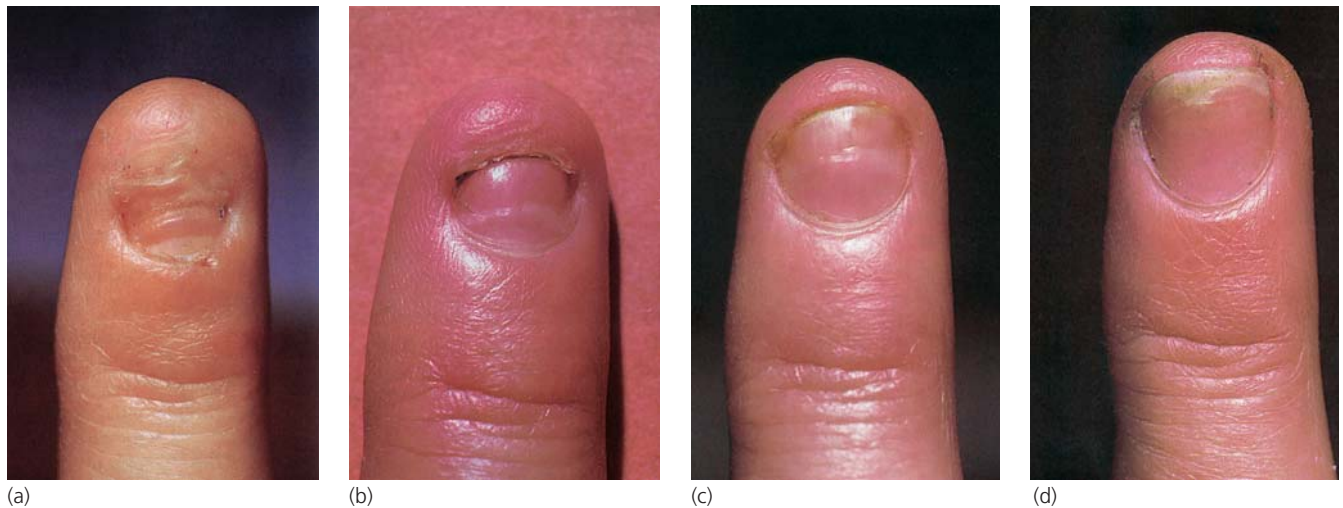


Figure 1.36 (a–d) Regrowth of the fingernail following traumatic avulsion. The free edge is parallel to the lunula.

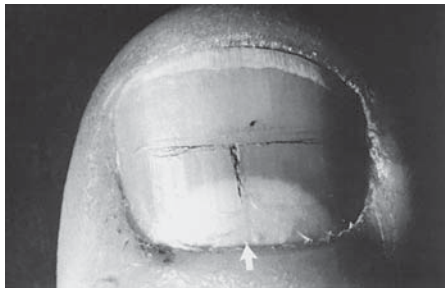


Figure 1.37 T-shaped mark etched on nail for nail growth measurement. Arrow points to posterior nail fold reference point. Note the absence of a cuticle. Reproduced from Dawber [233] with permission from Wiley-Blackwell.

technique was not pushed to its full potential, as only clippings and not the entire *in vivo* nail plate were assessed. It was thought that longitudinal nail growth increased during therapy because surface beading became more spaced apart.

All these methods involve estimation of linear growth. As a measure of total matrix activity, this could be misleading. Hamilton sought to measure volume by the following equation [238]:

$$\text{Volume} = \text{thickness (mm)} \times \text{breadth (mm)} \\ \times \text{length grown per day}$$

Johnson also tried to measure volumetric growth with respect to linear growth, ignoring time [12]. This entailed the measurement of thickness and mass at different points in the avulsed nail plate. The method presumed that linear measurements in the longitudinal axis of the nail plate were proportional to time and that no element of compaction complicated the issue.

Attempts to measure volume take on particular significance in disease states provoking Beau's lines. In a condition where the bulk of the nail is manifestly affected, measurement of linear growth alone may give misleading results (Fig. 1.39).

Measurement of longitudinal rate of growth may have some bearing on interpretation of studies where the concentration of incorporated elements of compounds is being evaluated. The relevance of the nail growth rate depends on the relative influence of solubility of the compound in the nail and the rate of transfer to the nail. If the rate of nail growth is high and the solubility is low, then it may be a determinant. However, in most instances, it is likely that solubility will be sufficient to allow equilibration between the nail and nail bed before the nail grows out. This may not fully apply to a thick nail, where there may be a limit to the diffusion of the compound upwards through a thick nail. These considerations are covered in the topic of measurement of fluoride in nail as part of studies to look at public health policies of fluoridation for dental care [239, 240].

Physiological factors and nail growth

Most studies concern fingernails, whose rate of growth can vary between 1.9 and 4.4 mm/month [235]. A reasonable guide is 3 mm/month or 0.1 mm/day. Toenails are estimated to grow around 1 mm/month. A recent study of healthy students on a US campus reported values of 3.5 mm/month for fingernails and 1.6 mm for toenails [241]. The authors concluded that this represented a genuine increase over historical controls and may correspond to other biometric increases over the last 30 years. Population studies on nail growth have given the general findings that there is little marked seasonal change and nails are unaffected by mild

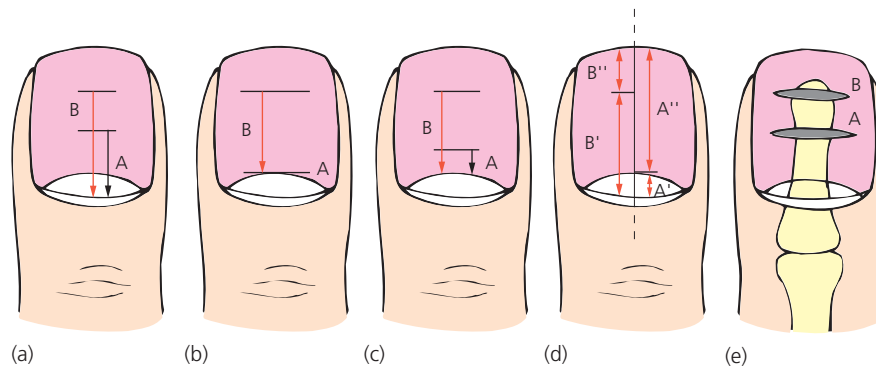


Figure 1.38 Methods of nail growth measurement. (a) Reference point, cuticle. Growth = $B - A$. Reproduced from Dawber [233] with permission from Wiley-Blackwell. (b) Reference point, lunula. Growth = $B - A$. Reproduced from Hillman [232] with permission from Wayne State University Press. (c) Reference point, lunula. Growth = $B - A$. Reproduced from Gilchrist [231] with permission from Wiley-Blackwell. (d) Reference point, cuticle and nail attachment margin distally. Growth = $(B' - A') + (A'' - B'')$. (e) Reference point, bone. Seen on x-ray with bismuth amalgam in transverse scratch in nail. Growth measured as movement of scratch from A to B and change in relation to radiological reference points on underlying bone.

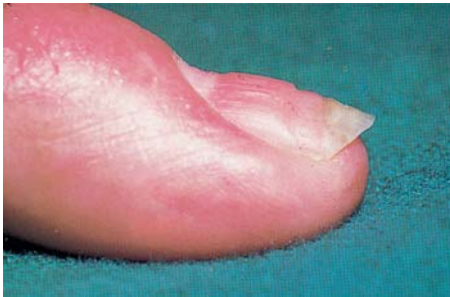

Figure 1.39 Side view of a nail with Beau's line, indicating the change in nail bulk.

intercurrent illnesses [232, 235]. The height or weight of the individual made no significant difference [232, 242]. Gender has been thought to make a small difference in early adulthood, with men having significantly ($P < 0.001$) faster linear nail growth up to the age of 19 [238]. They continue to do so with gradually diminishing significance levels, up to the age of 69, when there is a cross-over and women's nails grow faster than males. However, this pattern may have changed, with apparent equivalence between men and women with more recent analysis [241]. There is rough agreement from Hillman in an earlier study, although he found that the cross-over age was around 40 [232]. However, males continued to have a greater rate of nail growth throughout life if volume was measured and not length [238]. Children under 14 have faster growth than adults.

Pregnancy may increase the rate of nail growth [242] and poor nutrition may retard it [231].

Temperature is an influence with unclear effects. Bean [243] kept a slightly idiosyncratic record of his own fingernail growth by making a scratch at the free

edge of his cuticle on the first day of each month for 35 years. His record showed a gradual slowing with age. It initially showed a seasonal variation, with heightened growth in the warm months. This variation became less marked with age, combining with a move from Iowa to Texas where seasonal contrasts are reduced. Other studies to determine the influence of temperature have compared nail growth rates for people in temperate and polar conditions. An original study in 1958 [244] found that nail growth was significantly retarded by living in the Arctic. Subsequent studies from the Antarctic found that there was no change in nail growth [245, 246]. These studies are not scientific and it is unclear whether they are commenting on the improvement in thermal insulation since 1958 or nail physiology.

Nail growth in disease [247]

Systemic disease

Insufficient numbers of seriously ill people have been followed as part of a larger study to give good statistical evidence concerning the influence of disease on nail growth. There is plenty of evidence from small numbers that some severe systemic upsets disturb nail formation. The observations of Justin Honoré Simon Beau in 1836 [248] detailed the development of transverse depressions upon the nails of people surviving typhoid. The form of nail growth interference represented by Beau's lines is seen in many conditions (see "Beau's lines" in Chapter 2). Yellow nail syndrome can be manifested as a systemic illness of the respiratory system and nails or be seen mainly limited to the nails. In the latter, the clinical features of thickening with yellow discoloration correspond to a reduction in rate of longitudinal growth. But this can be

compensated for in some instances by an increase in nail thickness, with the consequent observation that “the nail that grows half as fast grows twice as thick” [249]. This may not be applicable to all situations, as it has been noted that biotin may reduce nail fragility and at the same time increase both the thickness and rate of longitudinal growth [250]. Severe illness in the form of mumps has been noted to bring linear growth to a standstill [235]. Other acute infections are quite variable, with 10 cases of acute febrile tuberculosis failing to have significant effect [235]. In the same study, chronic nephrosis produced exceptionally slow nail growth. Paradoxically, these authors also found that cadavers appeared to continue the growth of their nails in the 10 days postmortem during which they were assessed. The effect of death was less marked than that of mumps, something adults with mumps might agree with.

Local disease

Local diseases can influence nail growth. Dawber *et al.* [251] noted that onycholysis was associated with increased nail growth. This was true whether it was related to psoriasis or idiopathic. It is interesting that psoriasis may also produce Beau’s lines and so reduce the bulk of the nail. It is not even clear whether Beau’s lines represent a reduction in linear growth. They have been noted after retinoid therapy and yet this group of drugs has been noted to increase nail growth in psoriasis [252]. The surface morphology of the nail in a Beau’s line reflects a change in rate of nail plate production in different zones in the matrix and a loss of coordination with longitudinal growth; it is a product of pathology in space and time. Perhaps a nail that is growing faster is unable to accumulate bulk. Other systemic psoriasis treatments may reduce the rate of nail growth [253] (Fig. 1.40).

Trauma may increase nail growth, onychophagia [241] and wrist fractures being the most common examples. Details of nail and local hair growth have been recorded in instances of reflex sympathetic dystrophy where Beau’s lines and hypertrichosis on the dorsum of wrist, arm and hand may coincide. It is not clear whether the nail changes represent increased or decreased growth in these circumstances. Hypertrichosis indicates an extension of anagen, such that hairs that might normally fall out at 5 mm or less become longer and may gain a greater diameter. It does not necessarily mean that the hairs are growing faster and so, in common with Beau’s lines, it represents a change in the pattern of appendage growth rather than a simple alteration of rate.

Immobility alone may result in a reduction in the rate of nail growth and while this factor prevails after wrist fracture, reflex sympathetic dystrophy entails significant changes in blood supply that may have their own effects. Studies of right/left comparison with onych-

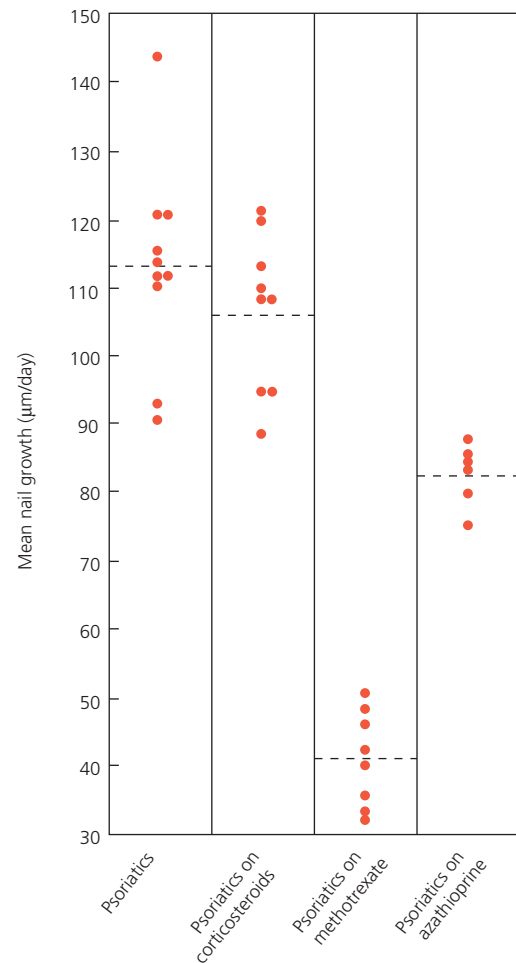


Figure 1.40 Effect of therapy on nail growth in psoriasis. Reproduced from Dawber [253] with permission from Wiley-Blackwell.

mycosis of the toenail indicate that there is a reduction in the longitudinal rate of growth of the toenail while it is infected with fungus, which normalizes on cure [236]. In some instances this has been attributed to the effects of the drug itself, terbinafine [254] and itraconazole [237].

Table 1.8 includes influences upon nail growth that are reported, but not always of statistical significance.

Nail plate biochemical analysis

Methods of analysis

A great range of methods has been used to analyze the organic and inorganic content of nails. Table 1.9 gives a guide, indicating how particular methods are appropriate for different constituents. Nail proteins are structural, but the other components are usually deposited within the nail as part of a normal or pathological process reflecting the biological environment of the nail, which in turn will reflect the

Table 1.8 Factors determining rate of nail growth.

Faster	Slower	Reference
Environment		
Daytime	Night	
Summer	Winter/cold	[243, 400]
Physiological		
Pregnancy	1st day of life	[242, 401]
Right hand/dominant	Left hand/non-dominant	
Youth	Old age	[238]
Middle finger	Thumb and little finger	[168, 402]
Men	Women	[238, 402]
Disease		
Psoriasis	Finger immobilization	[403, 404]
Pitting	Fever	[233, 235]
Normal nails	Beau's lines	[233, 248]
Onycholysis		[251]
Pityriasis rubra pilaris	Onychomycosis	[155, 236, 253]
Hyperthyroidism		[168]
AV shunts	Yellow nail syndrome	[168, 249]
	Relapsing polychondritis	[405]
Medication		
Etretinate	Etretinate	[406]
Levodopa		[407]
Calcium/vitamin D, biotin		[250]
Benoxaprofen, terbinafine, itraconazole	Methotrexate, azathioprine	[155, 237, 253, 254, 408]

AV, arteriovenous.

external environment of the individual. Interpretation of the concentration of biomarkers in nail may require knowledge of the rate of growth of the nail, although the contribution of this variable is not always easy to calculate [255].

The virtue of nail as a medium for analysis is the manner in which it evens out short-term variations. Consequently, urine may be a good measure for a short-term exposure in the previous 24 h, hair over previous months depending on length, but nail may be useful for periods of over a year where toenails are used. For longer periods still, dental material can be used [256]. These figures are likely to be subject to the length of the hair, the site of nail sampling (toe versus finger) and the age of the subject.

Nail proteins

From Table 1.9 on analytical methods, it is clear that a considerable number of endogenous and exogenous materi-

als can be sought in the nail plate. The protein mesh into which the elements fit is made primarily of the intracellular protein keratin. The highly ordered structure of the proteins in the nail plate helps explain the degree of chemical and physical resistance in contrast to the characteristics of skin. The proteins of hair and nail alike have extensive folding maintained by extremely stable disulfide bonds. Although these bonds can also be found to a lesser extent in the stratum corneum of normal skin, they have a different geometry in the two sites as demonstrated by Raman spectroscopy. This is expressed as gauche-gauche-gauche for hair and nail and gauche-gauche-trans for stratum corneum [257]. The latter is less stable. The altered geometry of disulfide bonds and the extreme folding of protein molecules in hair and nail result in a different degree of hydration. The looser structure of skin allows more free water, whereas the structure

Table 1.9 Nail constituents and means of nail analysis.

Method	Constituent	Reference
Structural and mineral constituents or exogenous materials		
Raman spectroscopy	Water, proteins and lipid, gender	[409, 410]
Immunohistochemistry	Keratin, human papilloma virus	[411, 412]
Polymerase chain reaction	Forensic, paternity, fungal	[413–415]
Electron microscopy	Cystine	[137]
X-ray diffraction	Changes indicative of malignancy, histology	[141, 416]
Flow injection hydride generation	Arsenic	[284]
Gas chromatography	Amphetamine, cocaine	[290, 292, 293]
Mass fragmentography	Metamphetamine	[201]
Atomic absorption spectrometry	Arsenic, Cd, Cu, Mn, Ni, Pb	[417, 418]
Colorimetry	Surface nail proteins	[151]
Biological markers		
High performance liquid chromatography	Furosin (glycosylated keratin), terbinafine, amino acids	[269, 419, 420]
Microscopy	Melanocyte populations and pathology, lipid: triglyceride	[421, 272]
Adsorption differential pulse voltametry	Nickel and occupational exposure with allergy	[289]
Enzymic assay	Steroid sulfatase and X-linked ichthyosis	[270]
Neutron activation analysis	Heavy metals and heart disease, selenium and inflammatory processes, copper and melanoma	[422–424]

of hair and nail allows very little. This contrasting degree of hydration means that skin is capable of sustaining metabolic processes not seen in nail [257]. Keratins and the associated proteins fall into the following categories:

- low sulfur proteins (40–60 kDa)
- high sulfur proteins (10–25 kDa)
- high glycine/tyrosine proteins (6–9 kDa).

It is believed that the low sulfur keratins form 10 nm filaments and the latter two groups of proteins form an interfilamentous matrix. The diversity of keratins within humans and between different species lies in the permutations of these three proteins [258] and the diversity of the keratins themselves. Over 30 high sulfur proteins have been identified in human nail by polyacrylamide gel electrophoresis [259].

Nail plate keratin fibrils appear orientated in a plane parallel to the surface and in the transverse axis [260]. They fall roughly into an 80:20 split between “hard” hair type (trichocyte) keratin and “soft” epithelial keratin [105]. These two variants are similar in many respects and share an x-ray diffraction pattern of α -helices in a coiled conformation, also confirmed using Raman spectroscopy [257]. Hard keratins split into the classic association of acidic and basic pairs, with extensive amino acid homolo-

gies with the epithelial forms [261]. In spite of regions of homology, the “hard” and “soft” keratins are distinguishable by immunohistochemistry [14, 16, 105]. The relative resilience of the two groups of keratins is also reflected by their solubility in 2-mercaptoethanol. At 50 mmol/L concentrations, only epithelial “soft” keratins are extracted from nail clippings. The concentration needs to be raised to 200 mmol/L before significant quantities of “hard” keratin dissolve [262].

The main lipid of nail is cholesterol. The total fat content is 0.1–1%, contrasting with the 10% found in the stratum corneum. The water content is less than that of skin, being 7–12% compared with 15–25%.

Biomarkers in nail

X-ray diffraction is one of the best tried methods of elemental nail analysis. Much of the initial work was done by Forslind [260] who observed that the hardness of the nail plate is unlikely to be due to calcium, which the analogy with bone has suggested. Detailed resumés of normal nail mineral content have been made [263].

Much interest has been demonstrated in the analysis of nails as a source of information concerning health. A significant increase in the nail content of Na, Mg and P

was noted in a survey of 50 patients with cirrhosis [264]. In a comparison of term and preterm infants, a decrease in aluminum and sulfur was found in term deliveries. The high aluminum content in preterm infants was considered of possible relevance to the osteopenia observed in this group [19]. Copper and iron have been observed at higher levels in the nails of male 6–11 year olds in comparison with females [265]. This in turn has been reviewed in connection with autism and seen alongside increases of lead and other metals [266]. Iron levels in the general population were found to be equal in men and women, but higher in children and highest in the neonate [267].

In some respects, nail analysis can be compared with a blood test, but involving the examination of a less labile source of information. Analysis of chloride in nail clippings of a juvenile control population and those suffering cystic fibrosis revealed a significant increase of chloride, by a factor of 5, in the latter. This has led to the suggestion of “screening nail by mail” for inaccessible regions, where sending nails would be relatively easy.

The glycosylated globin molecule, used for estimation of long-term diabetic control, has been used as a model in studies measuring nail furosine in diabetes mellitus. The nail fructose-lysine content is raised in this disease and has shown a correlation with the severity of diabetic retinopathy and neuropathy [268]. Nail furosine levels have also shown a good correlation with fasting glucose and may even compete with glycosylated hemoglobin as an indicator of long-term diabetic control [269].

Steroid sulfatase and its substrate, cholesterol sulfate, have been assayed in the nails of children being screened for X-linked ichthyosis and found to have adequate sensitivity and accuracy to be useful [264, 270, 271]. Sudan IV-positive material in nails has been measured as a guide to serum triglycerides [272].

Selenium is a trace element critical for the activity of glutathione peroxidase, which may protect DNA and other cellular molecules against oxidative damage. High concentrations are seen to protect against the action of certain carcinogens in some animal models and consequently its role in human cancers has been explored. Analysis of the selenium levels of different rat tissues suggests that blood selenium may be the best indirect measure of liver selenium while nail selenium may best reflect whole-body levels and the level in skeletal and heart muscle [273]. Nail selenium levels in those being screened for oral cancer [274] and carcinoma of the breast [264, 275] showed no significant differences between affected and control patients. However, in a prospective study, toenail selenium levels had a weak predictive value for the development of advanced prostate cancer, where low levels of selenium predisposed to this malignancy [276]. Examination of a wide range of trace elements in the nails

of women with breast cancer failed to show any difference from normal controls [277] and analysis of nail for zinc showed no significant difference between pellagra patients with low serum zinc and normal controls [278].

Nail clippings can be used as a source of DNA which, after amplification by the polymerase chain reaction, is of forensic use. Early work required 20–30 mg of nail [279] but this figure has decreased to 5 mg, where good-quality nail can be obtained from cadavers of more than 6 months death yielding DNA adequate for forensic identification [280].

Exogenous materials in nail analysis

Exogenous materials can be considered in two groups: environmental and ingested substances. In the first category, cadmium, copper, lead and zinc were examined in the hair and nails of young children [281]. This was done to gauge the exposure to these substances sustained in rural and industrialized areas of Germany. Both hair and nail reflected the different environments, although the multiple correlation coefficient was higher for hair than nails. Similar work with lead and cadmium in 200 Kenyan children demonstrated that the level of heavy metals in their fingernails correlated more to the location of their school than to their home [282]. Where comparable studies are done with adult disease and control groups, it has been shown that those with coronary heart disease and hypertension have significantly higher levels of chromium and zinc and lower iron than healthy matched controls [283]. It remains difficult to lend a clear interpretation to these results in terms of their biological significance and whether they are observations of cause or effect.

Water taken from wells in arsenic-rich rock has resulted in arsenic poisoning on a major scale in West Bengal, India, over the last 10 years. About 50% of ingested arsenic is excreted in the urine, smaller amounts in the feces, hair and nails. Nail analysis has been used in the Bengal population as well as in other populations suffering arsenic poisoning. Levels were estimated using flow injection hydride generation atomic absorption spectroscopy which allows analysis using very small samples and enables comparisons between different tissues. The Bengal experience suggests that there are similar concentrations in hair and nail, with a trend towards higher concentrations in the latter [284]. During an episode of arsenic poisoning in Alaska, the level of arsenic in nail was four times that found in hair [285]. A study in New Hampshire, USA, found that in subjects drinking from arsenic-rich wells, there was a doubling of toenail arsenic for a 10-fold rise in water arsenic content [286].

The features of arsenic poisoning were different in Alaska and Bengal, with far more cutaneous and systemic signs of toxicity in the Bengal population in spite

of similar levels in body tissues. This was attributed to coexistent dietary deficiencies and ill health in the Bengalis. In affluent North American communities, higher toenail arsenic has been associated with prolongation of the QT interval on electrocardiograph [287]. This could be due to an effect on the flux of calcium currents in cardiac cell membranes and clinically could contribute to disease. Risk of coronary heart disease is found to be correlated with nicotine concentration in toenail samples as revealed in a substantial cohort followed between 1984 and 1998 [288].

In many countries fluoride is added to drinking water as a public health measure. In forensic terms, it can be a means of identifying whether the person originated from a fluorinated district or not, where hair, nail and teeth can all be measured for fluoride content to reveal exposures of different temporal profile [239].

Nickel analysis has been performed to establish occupational exposure [289].

The use of forensic nail drug analysis has been reported by the Japanese where over 20,000 people were arrested for the abuse of methamphetamine in 1987 [290, 291]. It was found that the drug entered the nail via both the matrix and nail bed. Chronic drug abusers could be distinguished from those with a single recent ingestion by scraping the undersurface of the nail before analysis. This would remove the nail bed contribution and the drug it contained in the “one-off” abuser.

Simultaneous hair and nail analysis has been performed to compare the capacity of the tissues to reflect chronic drug abuse in those taking cocaine [292] and amphetamines [293]. Miller *et al.* [292] found that concentrations of cocaine and its derivatives were higher in hair than in nail, whereas Cirimele *et al.* [293] found that the concentrations of amphetamines and its metabolites were similar in both tissues. Analysis of nail clippings from the newborn by gas chromatography-mass spectroscopy can provide evidence of exposure to cocaine during embryogenesis. Given the point of nail formation, it is likely that the levels will reflect exposure after the 14th week [294]. Inclusion of the antifungal terbinafine via the nail bed has also been observed [295]. Access of the drug to the nail plate via the nail bed may be one of the important factors allowing effective therapy to be delivered in less time than it takes to grow a nail [296, 297]. *In vitro* models for the uptake and delivery of terbinafine by nail plate have been employed to examine aspects of this process [298].

Following single large doses of methamphetamine, it can be detected by mass fragmentography in saliva up to 2 days later, hair up to 18 days and in nail for the next 45 days [291]. Chloroquine [299] has also been measured in nail clippings for research purposes up to a year after ingestion.

Physical properties of nails

Strength

The strength and physical character of the nail plate are attributable to both its constituents and design. The features of design worthy of note are the double curvature, in transverse and longitudinal axes, and the flexibility of the ventral plate compared with the dorsal aspect. The first provides rigidity, whereas the latter allows moderate flexion deformity and slightly less extension. The most proximal component of the matrix provides the corneocytes of the dorsal nail surface. These usually provide a shiny surface. When the matrix is altered by disease or the nail surface subject to trauma, this shine is lost.

Measuring nail strength

Several techniques have been developed to study the physical properties of nails [300–302]. Maloney’s studies showed changes of tensile, flexural and tearing strength with age, sex and the digit from which the nail derived. Finlay devised a “nail flexometer” able to repeatedly flex longitudinal nail sections through 90°, recording the number it took to fracture the nail. In this way, the strength could be quantified. He noted that the immersion of nails in water for an hour increased their weight by 21%. It also made them significantly more flexible. After 2 h, the flexibility was still increasing, whilst the water content reached a plateau. Analysis of *in vivo* nail by Raman spectroscopy suggests that after soaking in water for 10 min, the α -helical protein conformation is made more loose, with greater spacing between proteins as water occupies the interstices. However, this change is seen only in distal nail, with proximal nail already manifesting a high degree of hydration before immersion [303]. Farren [137] has used simple cutting tests, measuring the force needed to cut nail plate with scissors. He noted that it takes 50% more force to cut a nail longitudinally than transversely and attributes this to the trilaminar structure of nail with orientation of keratin fibrils that favors longitudinal over transverse strength.

Mineral oil has no effect on flexibility, although it can act to maintain some of the flexibility imbued by water. This principle is applied in the treatment of onychoschizia, where repeated hydration and drying of the nail plate results in splitting at the free edge [153]. Zaun [304] has used a method of assessment of brittleness that relies on the swelling properties of nail, employing the technique before and after therapy for brittle nails. Splitting can be partially overcome by applications of emollient after soaking the nails in water. The use of nail varnish can also decrease water loss [305].

Permeability

Nail permeability is relevant to topical drugs on the dorsal surface and systemic drugs from the ventral surface.

The principal characteristic of nail with respect to drug penetration is that it behaves more like a hydrophilic gel membrane than a lipophilic membrane such as the stratum corneum. Transonychial water loss can be measured *in vivo* [306] but drug penetration assay is more complicated. The simplest method is to use cadaver nails. Doing this, the permeability coefficient for water has been estimated at 16.5×10^3 cm/h and that for ethanol at 5.8×10^3 cm/h [307]. This demonstrates that the hydrated nail is more permeable to water than to alcohol and behaves like a hydrogel of high ionic strength to polar and semipolar alcohols. Looking at nail permeability in states of different relative humidity demonstrates that diffusivity of nail increases logarithmically, with an overall increase of 400 times from dryness to complete hydration [308]. Combining alcohols with water may increase the permeation by the alcohol. The addition of N-acetyl-L-cysteine or mercaptoethanol to an aqueous solvent has been found to enhance the penetration of nail samples by the antifungal tolnaftate [309]. Human nail can be substituted in such studies using an *in vitro* model for the assessment of drug penetration employing a keratin membrane prepared from bovine [310], sheep [311] and porcine hooves [312, 313].

The nail is 1000 times more permeable to water than is skin [314, 315] and consequently drugs required to diffuse through the nail should normally have a high degree of water solubility [316]. In spite of this, there is possibly a parallel lipid pathway that allows permeation of hydrophobic molecules [317] and lipid vehicles are of value because they stick better to the nail surface [310, 316].

Molecular size, expressed as weight, is a further factor determining the penetration of nail by a drug. Larger molecules penetrate less well. In the field of topical antimycotics, this allows prediction of efficacy when the combined characteristics of water solubility, molecular size and minimum inhibitory concentration for antifungal activity are allowed for in a complex calculation [318]. In this manner, drugs such as ciclopirox and amorolfine can be predicted to be of some value. However, more hydrophobic molecules, such as the imidazoles, itraconazole and ketoconazole, are barely able to diffuse into nail, even when it is pretreated with topical keratolytics such as papain, urea and salicylic acid [319]. The main pharmacological sphere of attempting nail penetration by drug is for the treatment of fungal nail disease. It is of note that *in vitro* work with normal and onychomycotic nails showed little difference in nail drug penetration between the two [320].

The dense matrix of keratin and associated proteins is considered an obstacle to dimethyl sulfoxide (DMSO) penetration in the nail plate, contrasting with its easier access through skin [317]. However, it appears to facilitate the penetration of some topical antimycotics [321]. When amorolfine is applied to nail, its penetration is enhanced

by pretreatment with DMSO and the penetration is further enhanced if methylene chloride is used as a vehicle for the antifungal in preference to ethanol [322]. Some medicated lacquers are also able to penetrate sufficiently to be of clinical use, particularly if their access is increased by abrading the dorsal surface of the nail plate [323, 324]. The concentration gradient, and hence diffusion, can be increased further by facilitating solution of the reagents, such as miconazole, by lowering the pH [325]. Using a solvent that evaporates will have the same effect [326].

Iontophoresis of chemical across a concentration gradient of drug of 50–100 mM has also been attempted with some success [327]. The problem mainly related to the practicality of the process and flux of sodium, potassium, chloride and water (transonychial water loss [TOWL]) through the nail under iontophoretic influence in comparison with normal passive flow [328].

Recent studies with common antifungal agents have been encouraging [329, 330], where variables of pH [331, 332] and penetration enhancers such as DMSO [333], mannitol [334] and low molecular weight polyethylene glycols [335] have been assessed. The clinical relevance of the technique relies on movement of drug, usually terbinafine, across two boundaries. First, drug entry into the nail needs to be enhanced in order to be effective within the nail. However, possibly even more important is the further stage of the drug leaving the nail and entering the subungual tissues to kill fungus at this sequestered site. The subungual tissues are very variable in their apposition to the nail and in their character. There may be onycholysis, with no contact between nail and nail bed, thick keratin between the two or a layer of loosely compacted material and squames with secondary bacterial or yeast infection. Although rate of drug flow from nail into an *in vitro* chamber can be measured [336], it is not the same as demonstrating a clinical effect in the heterogeneous settings that prevail with onychomycosis.

There is also exchange of chemicals between nail and the internal environment and it is likely that the nail has different characteristics of drug penetration on the dorsal and ventral surfaces [337]. The significance of this is mainly with respect to inclusion of circulating materials into the nail rather than the other way around, although in a study of topical application of sodium pyrithione, Mayer *et al.* [338] found microscopic amounts in the systemic circulation. Munro and Shuster [297] and Matthieu *et al.* [296] have shown that drugs can penetrate rapidly into the distal nail via the nail bed. Other drugs may be found in the nail, which makes the nail a useful source of information concerning the ingestion of some illicit drugs or environmental pollutants (see Table 1.9).

Nail has been compared with other keratinous tissues, such as hair, hoof and skin, to determine how well it provides a model of *in vitro* infection by fungi [339]. This

reveals that nail is relatively resistant to such infection and hair, feathers and horn were more easily penetrated.

Radiation penetration

The permeability of the nail plate to radiation has both advantages and drawbacks. It is the basis for treating 20-nail dystrophy with topical PUVA [340] and also the cause of photoonycholysis. This may be in association with photosensitizing drugs [341]. Benign longitudinal melanonychia can complicate phototherapy for psoriasis [342].

Chronic x-irradiation is associated with carcinoma *in situ* and invasive squamous cell carcinoma [343]. The polydactylous form of Bowen disease is commonly related to some source of radiation [344]. Parker and Diffey [345] have investigated the transmission of light through the toenails of cadavers. Examining wavelengths between 300 and 600 nm, it appears that transmission at the shorter wavelength is minimal. This corresponds to UVB. If the nail plate is acting as a sunscreen it is fortuitous, but the character of the toenails studied may not be the same as fingernails, which are more commonly exposed.

A double-blind study of superficial radiotherapy in psoriatic nail dystrophy has demonstrated a definite, albeit temporary benefit [346]. A similar temporary benefit has been demonstrated with electron beam therapy [347]. Both of these studies might suggest that the different forms of radiation are penetrating nail, although treatment of periungual psoriasis can have a secondary beneficial effect on subungual tissues.

The nail is also permeable to electric direct current which has been examined in dry and hydrated settings *in vitro* and *in vivo*. The passage of current with a voltage of 0.5–9 V does not cause any physical alteration to the nail and provides a baseline for the delivery of medication using iontophoresis. At higher voltages there is a perception by the patient when *in vivo* [348] and in the setting of phosphate buffer hydration, the nail resistance can drop after 2 h.

Imaging of the nail apparatus

Radiology

X-ray reveals little of the soft structures of the nail unit under normal circumstances. It has been used to measure nail bed thickness in a study of clubbing, revealing a statistical increase in the thickness of the clubbed fingernail bed over normal controls [349]. Benign space-occupying lesions may compress the underlying bone with corresponding upward convexity in the nail. Osteoid osteoma may be manifest through a characteristic nidus, although x-ray is not sufficient to rule out this pathology and may be supplemented with bone scan [350]. Chondroid tumors may act as a soft tissue tumor external to the bone or be detected as a lucency within the bone. Pincer nail deform-

ity [351] or trauma, including nail biting [352], can be associated with radiologically detectable osteomyelitis. Most isolated nail dystrophies should be x-rayed prior to surgical exploration. Clues to an exostosis, bone cyst, acroosteolysis or psoriatic arthropathy might be found. Locally invasive [353] or metastatic [354] malignancy can be revealed localized to the distal phalanx. In invasive subungual squamous cell carcinoma, up to 55% of patients will have radiological evidence of involvement of the underlying phalanx [355].

Glomus tumors may demonstrate particular radiological features. Mathis and Schulz [356] reviewed 15 such tumors on the digit and found that nine had characteristic changes of bony erosion. This was smooth and concave in most cases, but occasionally had a punched-out appearance on the phalangeal tuft. Van Geertruyden [357] noted bone erosion or alteration in 36% of 51 cases of subungual glomus. Supplementation of routine x-rays with arteriography may reveal a star-shaped telangiectatic zone [358] but generally, ultrasound or magnetic resonance imaging is thought to be more useful in delineating and characterizing the tumor [359].

Magnetic resonance imaging (MRI) (see Chapters 3 and 13) is an effective method of locating tumors, particularly where there is diagnostic difficulty [360–362]. It can be used in a range of periungual neoplasms [363] although it is most useful when the tumor contrasts with surrounding tissues with respect to density, fluid or fat content. The most marked example of this is with mucoid cysts [364] but even normal soft tissues can be differentiated and an *in vivo* anatomical assessment made using MRI [365]. This can be a useful means of identifying the inflammatory changes of psoriatic arthritis where it has consequences for the soft tissue element of the nail unit and consequently affects nail growth and appearance [366] and remains the gold standard for glomus tumors of the nail unit [367].

Ultrasound

Ultrasound has been used in the nail unit both as a research tool and to aid clinical diagnosis [368]. Finlay *et al.* [146] used 20 MHz pulse echo ultrasound to measure nail thickness *in vivo*, proximally and distally. The latter measurement correlated well with a micrometer gauge measurement of the free edge. Pulse transmission time was reduced by 8.8% distally, in comparison to the proximal measurement. This implies that the nail becomes thinner as it emerges, which is contrary to findings on avulsed nails (see “Nail growth” above). They also found that the nails ranked in thickness sequentially around the hand, with the thumb being top and the little finger bottom.

Jemec’s study of cadaver nails, *in situ* and avulsed, showed that nail dessication destroyed the correlation between ultrasound thickness measurements and screw

gauge [140]. This could have significance in quantification when the water content of nails can vary by 10%.

Clinically, high-frequency ultrasound has been used in the diagnosis of glomus tumors [369]. Fornage examined 12 patients and could depict the tumor in nine. The resolution of his transducer meant that lesions smaller than 3 mm could not be seen [369]. Matsunaga used a more sensitive modified probe with color Doppler to enhance localization, which has also been corroborated with histological findings [370].

Evolution of ultrasound with high variable frequency transducers (>15 MHz) and very sensitive vascular tools (>11 MHz) allows the combination of morphological imaging with vascular flow afforded by color Doppler. This enables mapping of structural changes alongside inflammatory processes in diseases of the digit such as psoriasis and systemic sclerosis, or in infarctive processes [371].

Profilometry

Profilometry is the technique of measuring the profile of a surface. It can be used on skin to measure wrinkling with actinic damage [372, 373] and teeth to examine the integrity of enamel and the characteristics of plaque [374]. It has also been used on nail surfaces to assess dystrophies where characteristic profiles are reported for the clinical features of pitting, grooves and trachyonychia [375]. Having established the method, it is then possible to use it as a measure of disease activity and nail growth, as attempted with a study of psoriatic trachyonychia during low-dose cyclosporine therapy [376] and the rate of nail growth during itraconazole treatment [237].

Dermoscopy (epiluminescence)

Dermoscopy is a method of microscopic examination using reflected light. In the clinical setting this is conveniently provided by a hand-held dermatoscope. A dissection microscope is a laboratory alternative. The dermatoscope affords only low magnification ($\times 10$) although this can be increased with the use of computer-linked mole mapping tools. Video dermoscopy has been used in psoriasis to provide a more complete record of the state of the pathology [377]. Illumination is provided from a light source within the instrument with an incident angle of 20° . Typically this is a light-emitting diode (LED), creating no heat. The source may be polarized. Mineral oil, ultrasound gel or alcohol hand cleansing gel is used at the skin surface to reduce the fraction of incident light reflected from the nail or stratum corneum and to increase the component that reveals intraepidermal or subungual detail in addition to some features of the papillary dermis. Gewirtzman demonstrated the value of gel on the nail unit, as the thickness of film that can be created

accommodates the curvature and irregularities of the appendage [378].

Dermoscopy is an established method for the examination of pigmented lesions of the skin [379] but its use for nail pathology has not been widely considered [380]. For the nail, it has also been used to help differentiation between benign and potentially malignant pigmented pathology [381] where this process can extend into a peroperative activity with direct dermoscopy of the nail bed and matrix after removal of the nail plate [382]. The main objective is to distinguish benign from malignant, where the malignant diagnosis is usually melanoma [383]. However, the technique is also very useful as a means of differentiating subungual heme from melanin [384, 385], where heme may be seen as a lake beneath the nail from an episode of bleeding or be more in the form of small hemorrhages or bruising from less overt trauma or connective tissue pathology. Where a melanocytic lesion is found, it can also be possible to predict the position of the pathology within the longitudinal axis of the matrix through examination of the free edge. A layer of pigment in the upper half of the nail plate is consistent with pathology in the proximal half of the matrix; lower edge pigmentation is consistent with a lesion in the distal half of the matrix [386]. Dermoscopy is also useful in evaluation of nail fold vessels and splinter hemorrhages, inflammatory diseases such as psoriasis and lupus [387] and infection and parasitic infestation [388]. It may also help in the assessment of benign tumors [389, 390].

Examples of dermoscopy findings in a range of pigmented nail unit lesions

Ungual melanoma

See Figures 1.41–1.44.

Ungual nevus

See Figure 1.45.

Ungual lentigo

See Figures 1.46–1.48.

Drug-induced nail pigmentation

See Figure 1.49.

Photography

Many sophisticated systems are available for taking good photographs of the nail unit. While their function might be sophisticated, their operation should be simple. It is not possible to deal with complicated equipment and tend to patients at the same time. The essentials are a 1:1 macrolens, with a further magnifying filter if greater detail within the nail unit is desired. This can be part of a

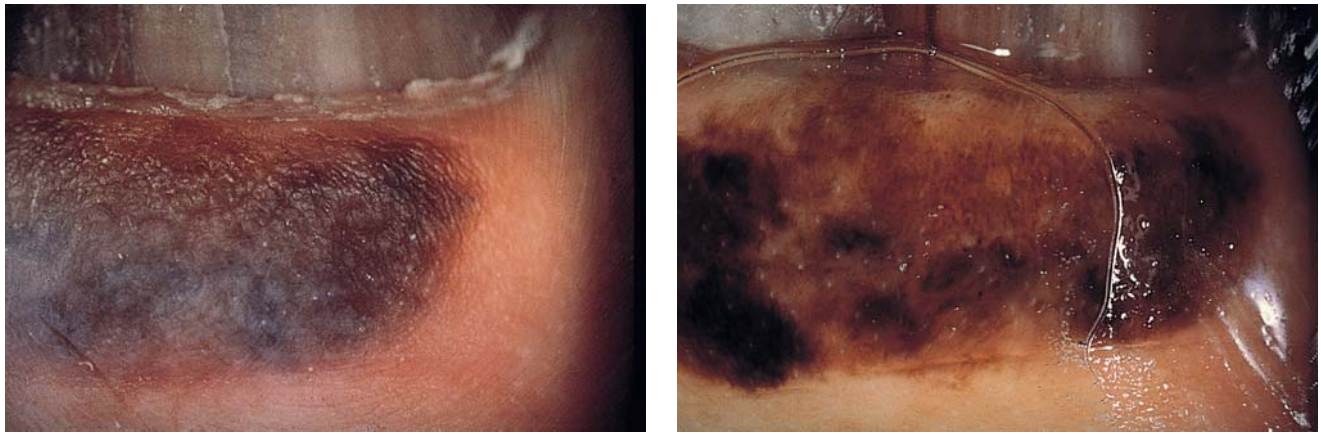


Figure 1.41 Melanoma of the proximal nail fold: polymorphic pigment with asymmetric disposition of a dark ink spot, irregular network, blue-gray areas. (a) Without gel. (b) With gel. Courtesy of L. Thomas.

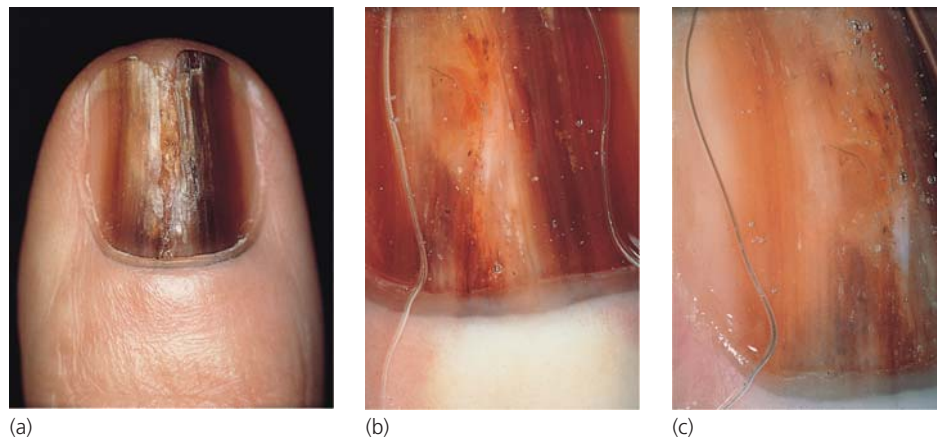


Figure 1.42 (a) Uneven pigment in the nail plate forming heterochrome parallel lines. (b) Pseudo-Hutchinson's sign through translucent cuticle. In the lateral portion of the nail plate (c), heterochrome linear disposition of pigmentation is more visible. Courtesy of L. Thomas.

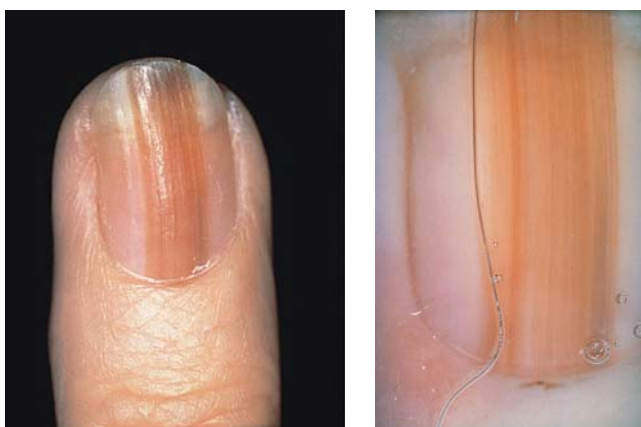

Figure 1.43 Hutchinson's sign (a) may be more clearly revealed when using dermoscopy (b). Courtesy of L. Thomas.

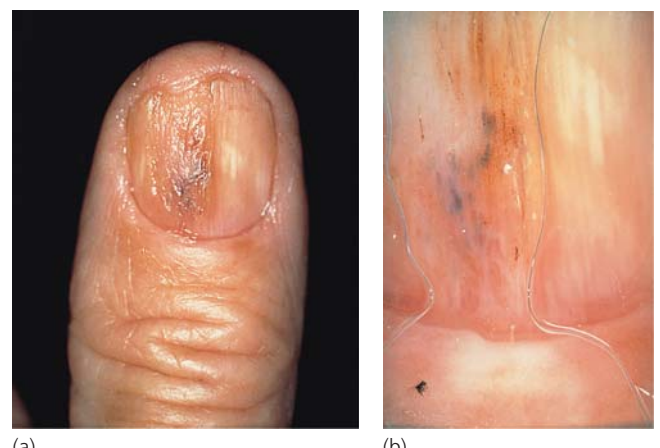

Figure 1.44 A destructive neoplasm of the nail bed and matrix appears initially to be without pigment (a), but this is demonstrated (b) using epiluminescence. Courtesy of L. Thomas.

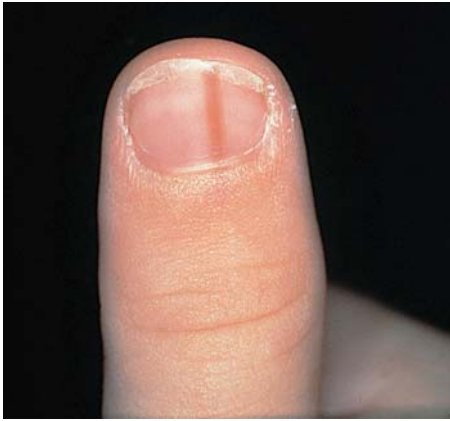

Figure 1.45 Acquired longitudinal melanonychia in an 8-year-old male child, which has relatively homogeneous pigment using dermoscopy, with a clinical diagnosis of a benign nevus. Courtesy of L. Thomas.

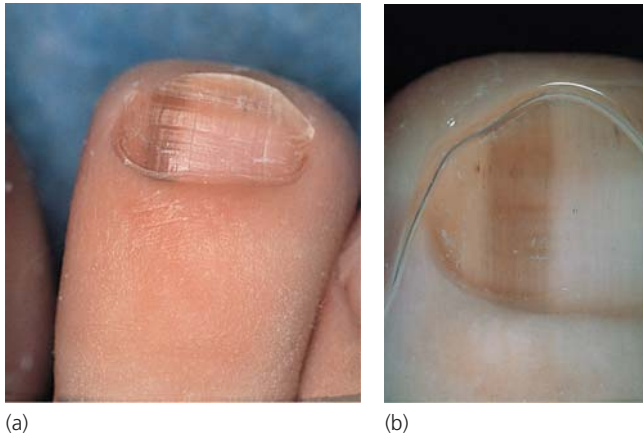


Figure 1.46 Recently discovered toenail longitudinal pigmentation in a 35-year-old male patient. Examination of other nails, mucous membranes and skin was otherwise normal, dermoscopy demonstrates homogeneous longitudinal grayish pigmentation of the nail plate. No clear parallel lines are seen. Histology confirms lentigo. (a) Without gel. (b) With gel. Courtesy of L. Thomas.

zoom or supplemented by a further 50 mm lens. If you have a mobile system, a hand-held flash is necessary and superior to a ring flash. It gives greater flexibility than the ring flash and allows oblique lighting if needed. However, in general, the light should be directed from the tip of the finger up the limb to avoid shadows.

Most clinicians will have access to high-quality digital photography. A digital single lens reflex (SLR) camera enables considerably more flexibility than the smaller automatic or semi-automatic cameras. Both types will often allow video capture and some will allow use with a dermoscope. This normally requires a dedicated adapter, specific to the camera. Depth of field is sometimes difficult to capture in digital images and relies on setting the camera in manual mode or aperture priority to have a long lens focal distance, or “f-stop.” A long focal distance

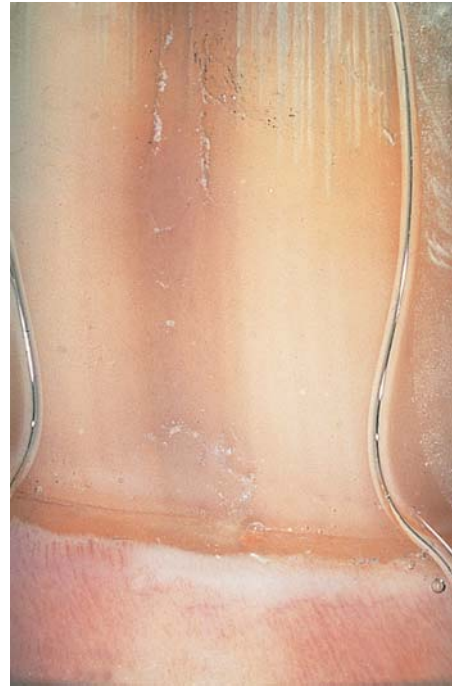

Figure 1.47 Lentigo. Courtesy of L. Thomas.

is associated with a small aperture, which will result in a reduction in light entering the camera. This can be offset to some extent by raising the ISO (ASA), but it should be appreciated that the higher the ISO, the more grainy an image becomes even though it enables the camera to shoot in low light. Consequently it is always best to use the flash which will enable photographs with high resolution and consistent exposure to be taken at an ISO of about 100, with a long f-stop (e.g. >22). With this configuration on a digital SLR, it is possible to avoid the use of backcloths for a homogeneous background, and instead rely on infinity. For instance, in a consulting room with a digit held for photography with the above settings, if there is 3 m space between the digit and the far wall and it is not of a bright or reflective nature, it will become homogeneously black. This avoids the common problem of colors or dust debris distracting from the content of the photograph.

Video systems have been used as a research tool for nail morphometry [391]. End-on and lateral views can be transferred to a computer for calculation of dimensions and to provide reference measurements.

Light

A good pocket torch is useful in the diagnostic transillumination of a myxoid cyst. The dermoscope may also be used. Transillumination should also be used to distinguish between intrinsic nail plate chromonychia and surface changes. Wood’s light may enhance the color changes induced by tetracycline and give a yellow fluorescence.

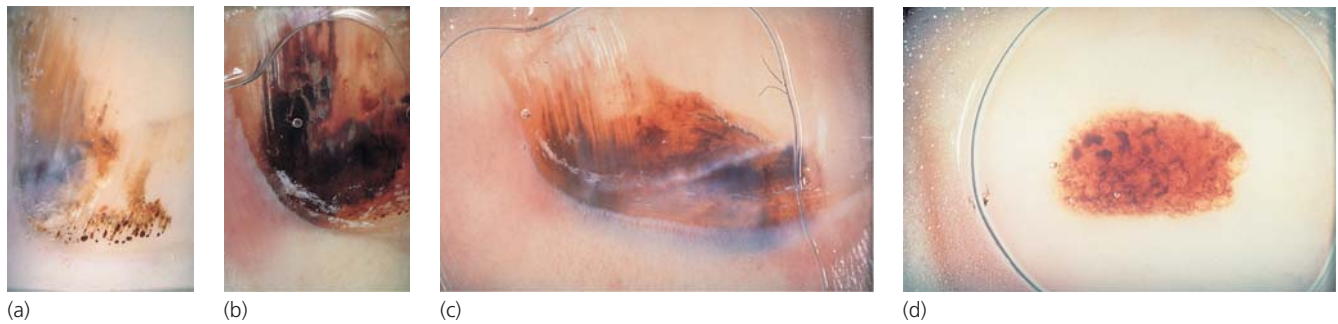

Figure 1.48 (a–d) Subungual hemorrhage has some longitudinal orientation because of the pattern of nail bed vessels and the longitudinal ridging of the underside of the nail plate. However, there are additional irregular elements that appear as “lakes” of heme, which is not seen with melanocytic pathology. Courtesy of L. Thomas.

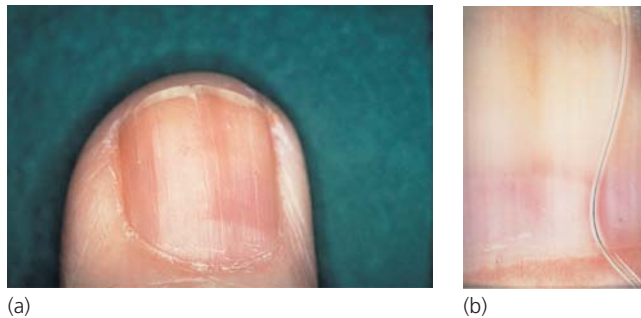


Figure 1.49 (a) Acquired longitudinal melanonychia involving several finger- and toenails in a 72-year-old male patient treated for 4 years with hydroxyurea for chronic lymphocytic leukemia. (b) The band is homogeneous and gray. Courtesy of L. Thomas.

Desmethylchlortetracycline appears reddish and *Pseudomonas* yellowish-green.

Polarized light can be helpful in the examination of the underside of nails. This is done with the aid of a light microscope to identify the longitudinal ridge pattern [144].

Other techniques

Laser Doppler can be used to assess the blood flow in the nail unit and is typically combined with ultrasound (see above). Optical coherence tomography produces a series of cross-sectional images down to a depth of 1–2 mm, separated by 15 μm . It has some potential for examining periungual tissues, but has been little explored as a technique [392]. Confocal microscopy is in a similar category, where light penetrates the unsectioned tissue to give three-dimensional information and has been used to examine the normal nail plate [393]. It has been used in the measurement of nail plate thickness *in vivo* [136] and piloted as a means of establishing the diagnosis of onychomycosis when undertaken alongside nail plate mycology and histology [394]. Although this work demonstrated alteration of the nail plate consistent with nail fungal infection, it was not adequately controlled against pathology of similar appearance.

Thermography measures radiating warmth indicative of superficial perfusion which in turn reflects neurovascular reactivity. Its main function has been as a possible indicator of cardiac risk [395] but there is potential for measurement of the vascular supply of the nail unit and the nail fold or pulp in particular.

Older techniques for the assessment of shape, and clubbing in particular, include brass templates [396], shadowgraphs [397], plaster casts and planimetry [398] and plethysmography [399].

References

- Haneke E. (2006) Surgical anatomy of the nail apparatus. *Dermatol Clin* **24**: 291–6.
- Lewis BL. (1954) Microscopic studies of fetal and mature nail and surrounding soft tissue. *AMA Arch Derm Syphilol* **70**: 733–47.
- Terry RB. (1955) The onychodermal band in health and disease. *Lancet* **268**: 179–81.
- Sonnex TS, Griffiths WAD, Nicol WJ. (1991) The nature and significance of the transverse white band of human nails. *Semin Dermatol* **10**: 12–16.
- Lewis BL. (1954) Microscopic studies of fetal and mature nail and surrounding soft tissue. *AMA Arch Derm Syphilol* **70**: 733–47.
- Warwick R, Williams PL (eds). (1973) *Gray's Anatomy*, 35th edn. Harlow: Longman.
- Schweizer J, Bowden PE, Coulombe PA *et al.* (2006) New consensus nomenclature for mammalian keratins. *J Cell Biol* **174**: 169–74.
- Moll I, Heid HW, Franke WW, Moll R. (1988) Patterns of expression of trichocytic and epithelial cytokeratins in mammalian tissues. *Differentiation* **39**: 167–84.
- Zaias N. (1963) Embryology of the human nail. *Arch Dermatol* **87**: 37–53.
- Hashimoto K, Gross BG, Nelson R, Lever WF. (1966) The ultrastructure of the skin of human embryos. III. The formation of the nail in 16–18 week old embryos. *J Invest Dermatol* **47**: 205–17.
- Zaias N, Alvarez J. (1968) The formation of the primate nail plate. An autoradiographic study in the squirrel monkey. *J Invest Dermatol* **51**: 120–36.
- Johnson M, Comaish JS, Shuster S. (1991) Nail is produced by the normal nail bed: a controversy resolved. *Br J Dermatol* **125**: 27–9.
- Baden HP, Kubilus J. (1984) A comparative study of the immunologic properties of hoof and nail fibrous proteins. *J Invest Dermatol* **83**: 327–31.
- Heid HW, Moll I, Franke WW. (1988) Patterns of trichocytic and epithelial cytokeratins in mammalian tissues. II. Concomitant and

- mutually exclusive synthesis of trichocytic and epithelial cyto-keratins in diverse human and bovine tissues. *Differentiation* **37**: 215–30.
- 15 De Berker D, Wojnarowska F, Sviland L, Westgate GE, Dawber RP, Leigh IM. (2000) Keratin expression in the normal nail unit: markers of regional differentiation. *Br J Dermatol* **142**: 89–96.
 - 16 Westgate GE, Tidman N, de Berker D, Blount MA, Philpott MP, Leigh IM. (1997) Characterisation of LH Tric 1, a new monospecific monoclonal antibody to the hair keratin Ha 1. *Br J Dermatol* **137**: 24–30.
 - 17 Moll I, Moll R. (1993) Merkel cells in ontogenesis of human nails. *Arch Dermatol Res* **285**: 366–71.
 - 18 Cameli N, Ortonne JP, Picardo M, Peluso AM, Tosti A. (1998) Distribution of Merkel cells in adult human nail matrix (letter). *Br J Dermatol* **139**: 541.
 - 19 Sirota L, Straussberg R, Fishman P, Dulitzky F, Djaldetti M. (1988) X-ray microanalysis of the fingernails in term and preterm infants. *Pediatr Dermatol* **5**: 184–6.
 - 20 Zwilling E. (1968) Morphogenetic phases in development. In: Locke M (ed) *The Emergence of Order in Developing Systems*. New York: Academic Press, pp. 184–207.
 - 21 Grant P. (ed) (1978) Limb morphogenesis: a dialog between an ectodermal sheet and mesoderm. In: *Biology of Developing Systems*. New York: Holt, Rinehart and Winston, pp. 414–21.
 - 22 Hanson JW, Smith DW. (1975) The fetal hydantoin syndrome. *J Pediatr* **87**: 285–90.
 - 23 Higashi N, Ikegami T, Asada Y. (1975) Congenital nail defects of the index finger. *Jap J Clin Dermatol* **29**: 699–701.
 - 24 Chen H, Lun Y, Ovchinnikov D *et al.* (1998) Limb and kidney defects in Lmx1b mutant mice suggest an involvement of LMX1B in human nail patella syndrome. *Nat Genet* **19**: 51–5.
 - 25 Blaydon DC, Ishii Y, O'Toole EA *et al.* (2006) The gene encoding R-spondin 4 (RSPO4), a secreted protein implicated in Wnt signaling, is mutated in inherited anonychia. *Nat Genet* **38**: 1245–7.
 - 26 Ishii Y, Wajid M, Bazzi H *et al.* (2008) Mutations in R-spondin 4 (RSPO4) underlie inherited anonychia. *J Invest Dermatol* **128**: 867–70.
 - 27 Aoki M, Kiyonari H, Nakamura H, Okamoto H. (2008) R-spondin2 expression in the apical ectodermal ridge is essential for outgrowth and patterning in mouse limb development. *Dev Growth Differ* **50**: 85–95.
 - 28 Blaydon DC, Philpott MP, Kelsell DP. (2007) R-spondins in cutaneous biology: nails and cancer. *Cell Cycle* **6**: 895–7.
 - 29 Segrelles C, Moral M, Lorz C *et al.* (2008) Constitutively active Akt induces ectodermal defects and impaired bone morphogenetic protein signaling. *Mol Biol Cell* **19**(1): 137–49.
 - 30 Han M, Yang X, Lee J, Allan CH, Muneoka K. (2008) Development and regeneration of the neonatal digit tip in mice. *Dev Biol* **315**: 125–35.
 - 31 Baran R. (1980) Syndrome d'Iso et Kikuchi (COIF syndrome); 2 cas avec revue de la littérature (44 cas). *Ann Dermatol Vénéreol* **107**: 431–5.
 - 32 Millman AJ, Strier RP. (1982) Congenital onychodysplasia of the index fingers. *J Am Acad Dermatol* **7**: 57–65.
 - 33 Aoki K, Suzuki H. (1984) The morphology and hardness of the nail in two cases of congenital onychoheterotopia. *Br J Dermatol* **110**: 717–23.
 - 34 Kinoshita Y, Nagano T. (1976) Congenital defects of the index finger. *Jap J Plast Reconstr Surg* **19**: 23.
 - 35 Kitayama Y, Tsukada S. (1983) Congenital onychodysplasia. Report of 11 cases. *Arch Dermatol* **119**: 8–12.
 - 36 Lowery JW, de Caestecker MP. (2010) BMP signaling in vascular development and disease. *Cytokine Growth Factor Rev* **21**: 287–98.
 - 37 Koizumi H, Tomoyori T, Ohkawara A. (1998) Congenital onychodysplasia of the index fingers with anomaly of the great toe. *Acta Derm Venerol* **78**: 478–9.
 - 38 Baran R, Juhlin L. (1986) Bone dependent nail formation. *Br J Dermatol* **114**: 371–5.
 - 39 George R, Clarke S, Ioffreda M, Billingsley E. (2008) Marking of nail matrix biopsies with ink aids in proper specimen orientation for more accurate histologic evaluation. *Dermatol Surg* **34**(12): 1705–6.
 - 40 Alkiewicz J, Pfister R. (1976) *Atlas der Nagelkrankheiten*. Stuttgart: Schattauer-Verlag, p. 8.
 - 41 Suarez SM, Silvers DN, Scher RK, Pearlstein HH, Auerback R. (1991) Histologic evaluation of nail clippings for diagnosing onychomycosis. *Arch Dermatol* **127**: 1517–19.
 - 42 Alvarez R, Zaias N. (1967) A modified polyethylene glycol-pyroxilin embedding method specially suited for nails. *J Invest Dermatol* **49**: 409–10.
 - 43 Chang A, Wharton J, Tam S, Kovich OI, Kamino H. (2007) A modified approach to the histologic diagnosis of onychomycosis. *J Am Acad Dermatol* **57**: 849–53.
 - 44 Bennett RG. (1976) Technique of biopsy of nails. *J Dermatol Surg* **2**: 325–6.
 - 45 Grover C, Nanda S, Reddy BS, Chaturvedi KU. (2005) Nail biopsy: assessment of indications and outcome. *Dermatol Surg* **31**(2): 190–4.
 - 46 Lewin K, DeWit SA, Lawson R. (1973) Softening techniques for nail biopsy. *Arch Dermatol* **107**: 223–4.
 - 47 Haneke E. (1991) Fungal infections of the nail. *Semin Dermatol* **10**: 41–53.
 - 48 D'Hue Z, Perkins SM, Billings SD. (2008) GMS is superior to PAS for diagnosis of onychomycosis. *J Cutan Pathol* **35**: 745–7.
 - 49 Achten G. (1963) L'ongle normal et pathologique. *Dermatologica* **126**: 229–45.
 - 50 Achten G, Andre J, Laporte M. (1991) Nails in light and electron microscopy. *Semin Dermatol* **10**: 54–64.
 - 51 Achten G, Wanet J. (1973) Pathologie der nagel. In: Doerr W, Seifert G, Uehlinger E (eds) *Spezielle Pathologische Anatomie*, vol. 7. New York: Springer Verlag, pp. 487–528.
 - 52 Baran R, Haneke E. (1984) Diagnostik und Therapie der streifenförmigen nagelpigmentierung. *Hautarzt* **35**: 359–65.
 - 53 Zaias N. (1967) The longitudinal nail biopsy. *J Invest Dermatol* **49**: 406–8.
 - 54 Nakayama Y, Iino T, Uchida A, Kiyosawa T, Soeda S. (1990) Vascularised free nail grafts nourished by arterial inflow from the venous system. *Plast Reconstr Surg* **85**: 239–45.
 - 55 Pessa JE, Tsai TM, Li Y, Kleinert HE. (1990) The repair of nail bed deformities with the nonvascularised nail bed graft. Indications and results. *J Hand Surg Am* **15A**: 466–70.
 - 56 Collins SC, Cordova KB, Jellinek NJ. (2010) Midline/paramedian longitudinal matrix excision with flap reconstruction: alternative surgical techniques for evaluation of longitudinal melanonychia. *J Am Acad Dermatol* **62**: 627–36.
 - 57 De Berker DA, Mawhinney B, Sviland L. (1996) Quantification of regional matrix nail production. *Br J Dermatol* **134**: 1083–6.
 - 58 Drapé JL, Wolfram-Gabel R, Idy-Peretti I *et al.* (1996) The lunula: a magnetic resonance imaging approach to the subnail matrix area. *J Invest Dermatol* **106**: 1081–5.
 - 59 Wilkerson MG, Wilkin JK. (1989) Red lunulae revisited: a clinical and histopathologic examination. *J Am Acad Dermatol* **20**: 453–7.
 - 60 Cohen PR. (1996) The lunula. *J Am Acad Dermatol* **34**: 943–53.
 - 61 Lewin K. (1965) The normal finger nail. *Br J Dermatol* **77**: 421–30.
 - 62 Wolfram-Gabel R, Sick H. (1995) Vascular networks of the periphery of the fingernail. *J Hand Surg Br* **20**: 488–92.
 - 63 Tan AL, Benjamin M, Toumi H *et al.* (2007) The relationship between the extensor tendon entheses and the nail in distal interphalangeal joint disease in psoriatic arthritis – a high-resolution MRI and histological study. *Rheumatology (Oxford)* **46**: 253–6.
 - 64 Soccia E, Scarpa R, Cimmino MA *et al.* (2009) Magnetic resonance imaging of nail unit in psoriatic arthritis. *J Rheumatol* **33**(Suppl): 42–5.
 - 65 Burrows MT. (1917) The significance of the lunula of the nail. *Anatom Rec* **12**: 161–6.
 - 66 Burrows MT. (1919) The significance of the lunula of the nail. *Johns Hopkins Med J* **18**: 357–61.
 - 67 Ham AW, Leeson TS (eds). (1961) *Histology*, 4th edn. London: Pitman Medical.

- 68 Baran R, Gioanni T. (1969) Les dyschromies ungueales. *Hospital (Paris)* 57: 101–7.
- 69 Guéro S, Guichard S, Fraitag SR. (1994) Ligamentary structure at the base of the nail. *Surg Radiol Anat* 16: 47–52.
- 70 De Berker DA, Baran R. (1998) Acquired malalignment: a complication of lateral longitudinal biopsy. *Acta Derm Venereol* 78: 468–70.
- 71 Higashi N. (1968) Melanocytes of nail matrix and nail pigmentation. *Arch Dermatol* 97: 570–4.
- 72 Higashi N, Saito T. (1969) Horizontal distribution of the DOPA-positive melanocytes in the nail matrix. *J Invest Dermatol* 53: 163–5.
- 73 Tosti A, Cameli N, Piraccini BM, Fanti PA, Ortonne JP. (1994) Characterization of nail matrix melanocytes with anti-PEP1, anti-PEP8, TMH-1, and HMB-45 antibodies. *J Am Acad Dermatol* 31 (2 Part 1): 193–6.
- 74 De Berker D, Dawber RP, Thody A, Graham A. (1996) Melanocytes are absent from normal nail bed: the basis of a clinical dictum. *Br J Dermatol* 134: 564.
- 75 Perrin C, Michiels JF, Pisani A, Ortonne JP. (1997) Anatomic distribution of melanocytes in normal nail unit: an immunohistochemical investigation. *Am J Dermatopathol* 19: 462–7.
- 76 Amin B, Nehal KS, Jungbluth AA *et al.* (2008) Histologic distinction between subungual lentigo and melanoma. *Am J Surg Pathol* 32: 835–43.
- 77 Theunis A, Richert B, Sass U, Lateur N, Sales F, André J. (2011) Immunohistochemical study of 40 cases of longitudinal melanonychia. *Am J Dermatopathol* 33: 27–34.
- 78 Molina, D, Sanchez, JL. (1995) Pigmented longitudinal bands of the nail. A clinicopathologic study. *Am J Dermatopathol* 17: 539–41.
- 79 Monash S. (1932) Normal pigmentation in the nails of negroes. *Arch Dermatol* 25: 876–81.
- 80 Leyden JJ, Spot DA, Goldsmith H. (1972) Diffuse banded melanin pigmentation in nails. *Arch Dermatol* 105: 548–50.
- 81 Kopf AW, Waldo F. (1980) Melanonychia striata. *Australas J Dermatol* 21: 59–70.
- 82 Leung AK, Robson WL, Liu EK *et al.* (2007) Melanonychia striata in Chinese children and adults. *Int J Dermatol* 46: 920–2.
- 83 Duhard E, Calvet C, Mariotte N, Tichet J, Vaillant L. (1995) Prevalence of longitudinal melanonychia in the white population. *Ann Dermatol Venereol* 122: 586–90.
- 84 Oropeza R. (1986) Melanomas of special sites. In: *Cancer of the Skin: Biology, Diagnosis, Management*, vol. 2. Oxford: Blackwell Scientific Publications, pp. 974–87.
- 85 Hashimoto K. (1971) The marginal band: a demonstration of the thickened cellular envelope of the human nail. *Arch Dermatol* 103: 387–93.
- 86 Hashimoto K. (1971) Ultrastructure of the human toenail. II. *J Ultrastruct Res* 36: 391–410.
- 87 Hashimoto K. (1971) Ultrastructure of the human toenail: I proximal nail matrix. *J Invest Dermatol* 56: 235–46.
- 88 Hashimoto K. (1971) Ultrastructure of the human toenail. Cell migration, keratinization and formation of the intercellular cement. *Arch Dermatol Forsch* 240: 1–22.
- 89 Parent D, Achten G, Stouffs-Vanhoof F. (1985) Ultrastructure of the normal human nail. *Am J Dermatopathol* 7: 529–35.
- 90 Allen AK, Ellis J, Rivett DE. (1991) The presence of glycoproteins in the cell membrane complex of variety of keratin fibres. *Biochim Biophys Acta* 1074: 331–3.
- 91 Oliveira MT, Specian AF, Andrade CG *et al.* (2010) Interaction of *Candida parapsilosis* isolates with human hair and nail surfaces revealed by scanning electron microscopy analysis. *Micron* 41: 604–8.
- 92 Laporte M, André J, Stouffs-Vanhoof F, Achten G. (1988) Nail changes in alopecia areata: light and electron microscopy. *Arch Dermatol Res* 280(Suppl): S85–9.
- 93 Schnitzler L, Baran R, Verret JL. (1980) Proximal nail fold biopsy in connectivetissue diseases. 26 cases studied under light and electron microscopy and direct immunofluorescence (author's transl). *Ann Dermatol Venereol* 107: 777–85.
- 94 Mauro J, Lumpkin LR, Dantzig PI. (1975) Scanning electron microscopy of psoriatic nail pits. *N Y State J Med* 75: 339–42.
- 95 Sangiorgi S, Manelli A, Congiu T. (2004) Microvascularization of the human digit as studied by corrosion casting. *J Anat* 204: 123–31.
- 96 Maricq HR. (1967) Observation and photography of sweat ducts of the fingers in vivo. *J Invest Dermatol* 48: 399–401.
- 97 Perrin C. (2008) The 2 clinical subbands of the distal nail unit and the nail isthmus. *Anatomical explanation and new physiological observations in relation to the nail growth*. *Am J Dermatopathol* 30(3): 216–21.
- 98 Pinkus F. (1927). In: Jadassohn JJ (ed) *Handbuch der Haut und Geschlechtskrankheiten*. Berlin: Springer, pp. 267–89.
- 99 Caputo R, Prandi G. (1973) Pterygium inversum unguis. *Arch Dermatol* 108: 817–18.
- 100 Odom RB, Stein KM, Maibach HI. (1974) Congenital, painful aberrant hyponychium. *Arch Dermatol* 110: 89–90.
- 101 Patterson JW. (1977) Pterygium inversum unguis-like changes in scleroderma. *Arch Dermatol* 113: 1429–30.
- 102 Rayan GM, Flournoy DJ. (1987) Microbiologic flora of human fingernails. *J Hand Surg* 12A: 605–7.
- 103 Tanner J, Khan D, Walsh S, Chernova J, Lamont S, Laurent T. (2009) Brushes and picks used on nails during the surgical scrub to reduce bacteria: a randomised trial. *J Hosp Infect* 71: 234–8.
- 104 Dowsett SA, Archila L, Segreto VA *et al.* (1999) *Helicobacter pylori* infection in indigenous families of Central America: serostatus and oral and fingernail carriage. *J Clin Microbiol* 37: 2456–60.
- 105 Lynch MH, O'Guin WM, Hardy C *et al.* (1986) Acid and basic hair/nail ('hard') keratins: their co-localisation in upper corticle and cuticle cells of the human hair follicle and their relationship to 'soft' keratins. *J Cell Biol* 103: 2593–606.
- 106 Lacour JP, Dubois D, Pisani A, Ortonne JP. (1991) Anatomical mapping of Merkel cells in normal human adult epidermis. *Br J Dermatol* 125: 535–42.
- 107 De Berker D, Leigh I, Wojnarowska F. (1992) Patterns of keratin expression in the nail unit: an indicator of regional matrix differentiation. *Br J Dermatol* 127: 423.
- 108 Sinclair RD, Wojnarowska F, Dawber RP. (1994) The basement membrane zone of the nail. *Br J Dermatol* 131: 499–505.
- 109 Purkis PE, Steel JB, Mackenzie IC, Nathrath WB, Leigh IM, Lane EB. (1990) Antibody markers of basal cells in complex epithelia. *J Cell Sci* 97: 39–50.
- 110 De Berker D, Sviland L, Angus BA. (1995) Suprabasal keratin expression in the nail bed: a marker of dystrophic nail differentiation. *Br J Dermatol* 133(Suppl 45): 16.
- 111 Fanti PA, Tosti A, Cameli N, Varotti C. (1994) Nail matrix hypergranulosis. *Am J Dermatopathol* 16: 607–10.
- 112 Kitahara T, Ogawa H. (1993) Coexpression of keratins characteristic of skin and nail differentiation in nail cells. *J Invest Dermatol* 100: 171–5.
- 113 Kitahara T, Ogawa H. (1994) Variation of differentiation in nail and bovine hoof cells. *J Invest Dermatol* 102: 725–9.
- 114 Kitahara T, Ogawa H. (1997) Cellular features of differentiation in the nail. *Microsc Res Tech* 38: 436–42.
- 115 Picardo M, Tosti A, Marchese C *et al.* (1994) Characterisation of cultured nail matrix cells. *J Am Acad Dermatol* 30: 434–40.
- 116 Nagae H, Nakanishi H, Urano Y, Arase S. (1995) Serial cultivation of human nail matrix cells under serum-free conditions. *J Dermatol* 22: 560–6.

- 117 Boot PM, Rowden G, Walsh N. (1992) The distribution of Merkel cells in human fetal and adult skin. *Am J Dermatopathol* **14**: 391–6.
- 118 Munro CS, Carter S, Bryce S *et al.* (1994) A gene for pachyonychia congenita is closely linked with the gene cluster on 17q12–q21. *J Med Genet* **31**: 675–8.
- 119 McLean WH, Rugg EL, Lunny DP *et al.* (1995) Keratin 16 and 17 mutations cause pachyonychia congenita. *Nat Genet* **9**: 273–8.
- 120 Corden LD, McLean WH. (1996) Human keratin disease: hereditary fragility of specific epithelial tissues. *Exp Dermatol* **5**: 297–307.
- 121 Hohl D. (1997) Steatocystoma multiplex and oligosymptomatic pachyonychia congenita of the Jackson–Lawler type. *Dermatology* **195**: 86–8.
- 122 Covello SP, Smith FJ, Sillevs Smitt JH *et al.* (1998) Keratin 17 mutations cause either steatocystoma multiplex or pachyonychia congenita type 2. *Br J Dermatol* **139**: 475–80.
- 123 Smith FJ, Jonkman MF, van Goor H *et al.* (1998) A mutation in human keratin K6b produces a phenocopy of the K17 disorder pachyonychia congenita type 2. *Hum Mol Genet* **7**: 1143–8.
- 124 Bowden PE, Haley JL, Kansky A *et al.* (1995) Mutation of a type II keratin gene (K6a) in pachyonychia congenita. *Nat Genet* **10**: 363–5.
- 125 Swensson O, Langbein L, McMillan JR *et al.* (1998) Specialised keratin expression pattern in human ridged skin as an adaptation to high physical stress. *Br J Dermatol* **139**: 767–75.
- 126 Okazaki M, Yoshimura K, Fujiwara H, Suzuki Y, Harii K. (2003) Induction of hard keratin expression in non-nail-matrical keratinocytes by nail-matrical fibroblasts through epithelial-mesenchymal interactions. *Plast Reconstr Surg* **111**: 286–90.
- 127 Lee DY, Lee JH, Yang JM, Lee ES, Mun GH, Jang KT. (2009) Versican is localized to nail mesenchyme containing onychofibroblasts. *J Eur Acad Dermatol Venereol* **23**: 1328–9.
- 128 Okamoto H, Kagami H, Okada K *et al.* (2006) Fate of transplanted nail matrical cells and potential of hard keratin production in vivo. *J Dermatol Sci* **44**: 175–8.
- 129 Lee DY, Yang JM, Mun GH. (2009) Onychofibroblasts induce hard keratin in skin keratinocytes in vitro. *Br J Dermatol* **161**: 960–2.
- 130 Baden H. (1994) Common transglutaminase substrates shared by hair, epidermis and nail and their function. *J Dermatol Sci* **7**(Suppl): S20–6.
- 131 Manabe M, O’Guin WM. (1994) Existence of trichohyalinkeratohyalin hybrid granules: co-localisation of 2 major intermediate filament-associated proteins in non-follicular epithelia. *Differentiation* **58**: 65–75.
- 132 O’Keefe EJ, Hamilton EH, Lee SC, Steiner P. (1993) Trichohyalin: a structural protein of hair, tongue, nail and epidermis. *J Invest Dermatol* **101**: 65s–71s.
- 133 Gruber R, Wilson NJ, Smith FJ *et al.* (2009) Increased pachyonychia congenita severity in patients with concurrent keratin and filaggrin mutations. *Br J Dermatol* **161**: 1391–5.
- 134 Lavker RM, Risse B, Brown H *et al.* (1998) Localisation of plasminogen activator inhibitor type 2 (PAI-2) in hair and nail: implications for terminal differentiation. *J Invest Dermatol* **110**: 917–22.
- 135 Cecchini A, Montella A, Ena P, Meloni GB, Mazzarello V. (2009) Ultrasound anatomy of normal nails unit with 18 MHz linear transducer. *Ital J Anat Embryol* **114**: 137–44.
- 136 Mogensen M, Thomsen JB, Skovgaard LT, Jemec GB. (2007) Nail thickness measurements using optical coherence tomography and 20-MHz ultrasonography. *Br J Dermatol* **157**: 894–900.
- 137 Farren L, Shayler S, Ennos AR. (2004) The fracture properties and mechanical design of human fingernails. *J Exp Biol* **207**: 735–41.
- 138 Jarrett A, Spearman RI. (1966) The histochemistry of the human nail. *Arch Dermatol* **94**: 652–7.
- 139 Samman P. (1961) The ventral nail. *Arch Dermatol* **84**: 192–5.
- 140 Jemec GB, Serup J. (1989) Ultrasound structure of the human nail plate. *Arch Dermatol* **125**: 643–6.
- 141 Garson JC, Baltenneck F, Leroy F, Riekel C, Müller M. (2000) Histological structure of human nail as studied by synchrotron X-ray microdiffraction. *Cell Mol Biol (Noisy-Le-Grand)* **46**: 1025–34.
- 142 Diaz AA, Boehm AF, Rowe WF. (1990) Comparison of fingernail ridge patterns of monozygotic twins. *J Forens Sci* **35**: 97–102.
- 143 Okada M, Nishimukai H, Okiura T, Sugino Y. (2008) Lyonization pattern of normal human nails. *Genes Cells* **13**: 421–8.
- 144 Apolinar E, Rowe WF. (1980) Examination of human fingernail ridges by means of polarized light. *J Forens Sci* **25**: 156–61.
- 145 Garg RK. (1983) Determination of ABO (H) blood group substances from finger and toenails. *Z Rechtsmed* **91**: 17–19.
- 146 Finlay AY, Moseley H, Duggan TC. (1987) Ultrasound transmission time: an in vivo guide to nail thickness. *Br J Dermatol* **117**: 765–70.
- 147 Samman PD, White WF. (1964) The ‘yellow nail’ syndrome. *Br J Dermatol* **76**: 153–7.
- 148 Baran R, Kechijian P. (1989) Longitudinal melanonychia diagnosis and management. *J Am Acad Dermatol* **21**: 1165–75.
- 149 Dawber RP, Colver GB. (1991) The spectrum of malignant melanoma of the nail apparatus. *Semin Dermatol* **10**: 82–7.
- 150 Germann H, Barran W, Plewig G. (1980) Morphology of corneocytes from human nail plates. *J Invest Dermatol* **74**: 115–18.
- 151 Tudela E, Lamberbourg A, Cordoba Diaz M, Zhai H, Maibach HI. (2008) Tape stripping on a human nail: quantification of removal. *Skin Res Technol* **14**: 472–7.
- 152 Shelley WB, Shelley D. (1984) Onychschizia: scanning electron microscopy. *J Am Acad Dermatol* **10**: 623–7.
- 153 Wallis MS, Bowen WR, Guin JD. (1991) Pathogenesis of onychoschizia (lamellar dystrophy). *J Am Acad Dermatol* **24**: 44–8.
- 154 Forslind B, Thyresson N. (1975) On the structures of the normal nail. *Arch Dermatol Forsch* **251**: 199–204.
- 155 Dawber RP. (1980) The ultrastructure and growth of human nails. *Arch Dermatol Res* **269**: 197–204.
- 156 Scherer WP, Scherer MD. (2004) Scanning electron microscope imaging of onychomycosis. *J Am Podiatr Med Assoc* **94**: 356–62.
- 157 Liu J, Lei P. (2003) Histopathologic and scanning electron microscope examination of the nail and hair in chronic mucocutaneous candidiasis. *J Am Acad Dermatol* **49**(2 Suppl Case Reports): S154–6.
- 158 Watts NR, Jones LN, Cheng N, Wall JS, Parry DA, Steven AC. (2002) Cryo-electron microscopy of trichocyte (hard alpha-keratin) intermediate filaments reveals a low-density core. *J Struct Biol* **137**: 109–18.
- 159 Fraser RD, Parry DA. (2007) Structural changes in the trichocyte intermediate filaments accompanying the transition from the reduced to the oxidized form. *J Struct Biol* **159**: 36–45.
- 160 Caputo R, Gasparini G, Contini D. (1982) A freeze-fracture study of the human nail plate. *Arch Dermatol Res* **272**: 117–25.
- 161 Arnn Y, Staehelin LA. (1981) The structure and function of spot desmosomes. *Int J Dermatol* **20**: 330–9.
- 162 Smith DO, Oura C, Kimura C, Toshimori K. (1991) Artery anatomy and tortuosity in the distal finger. *J Hand Surg* **16A**: 297–302.
- 163 Flint MH. (1955) Some observations on the vascular supply of the nail bed and terminal segments of the finger. *Br J Plast Surg* **8**: 186–95.
- 164 Smith DO, Oura C, Kimura C, Toshimori K. (1991) The distal venous anatomy of the finger. *J Hand Surg* **16A**: 303–7.
- 165 Lynn RB, Steiner RE, van Wyck FA. (1955) Arteriographic appearances of the digital arteries of the hands in Raynaud’s disease. *Lancet* **i**: 471–4.
- 166 Samman P, Strickland B. (1962) Abnormalities of the fingernails associated with impaired peripheral blood supply. *Br J Dermatol* **74**: 165–73.
- 167 Dawber RP. (1981) Effects of immobilization on nail growth. *Clin Exp Dermatol* **6**: 533–5.
- 168 Orentreich N, Markofsky J, Vogelmann JH. (1979) The effect of ageing on the rate of linear nail growth. *J Invest Dermatol* **73**: 126–30.
- 169 Currie AE, Gallagher PJ. (1988) The pathology of clubbing: vascular changes in the nail bed. *Br J Dis Chest* **82**: 382–5.

- 170 Gilje O, Kierland R, Baldes EJ. (1974) Capillary microscopy in the diagnosis of dermatologic diseases. *J Invest Dermatol* **22**: 199–206.
- 171 Park JH, Lee DY, Cha HS, Koh EM. (2009) Handheld portable digital dermoscopy: routine outpatient use for evaluating nail-fold capillary changes in autoimmune connective tissue diseases. *J Eur Acad Dermatol Venereol* **23**: 207.
- 172 Ryan TJ. (1973) Direct observations of blood vessels in the superficial vasculature system of the skin. In: Jarrett A (ed) *The Physiology and Pathophysiology of the Skin*, vol. 2. London: Academic Press, pp. 658–9.
- 173 Davies E, Landau J (eds). (1966) *Clinical Capillary Microscopy*. Springfield, IL: C.C. Thomas.
- 174 Basserga M, Bonacci E, Cammarota MG, d'Amico N. (1996) La capillaroscopia periungueale nello studio del microcircolo in età pediatrica. *Minerva Pediatr* **48**: 297–301.
- 175 Buchanan I, Humpston DJ. (1968) Nail fold capillaries in connective tissue disorders. *Lancet* **41**: 845–7.
- 176 Granier F, Vayssairat M, Priollet P, Housset E. (1986) Nail fold capillary microscopy in mixed connective tissue disease. *Arthritis Rheum* **29**: 189–95.
- 177 Studer A, Hunziker T, Lutolf O *et al.* (1991) Quantitative nail fold capillary microscopy in cutaneous and systemic lupus erythematosus and localised and systemic scleroderma. *J Am Acad Dermatol* **24**: 941–5.
- 178 Ohtsuka T, Tamura T, Yamakage A, Yamazaki S. (1998) The predictive value of quantitative nail fold capillary microscopy in patients with undifferentiated connective tissue disease. *Br J Dermatol* **139**: 622–9.
- 179 Schumann L, Korten G, Holdt B, Holtz M. (1996) Microcirculation of the fingernail fold in CAPD patients: preliminary observations. *Perit Dial Int* **16**: 412–16.
- 180 Ohtsuka T, Yamakage A, Miyachi Y. (1994) Statistical definition of nail fold capillary pattern in patients with psoriasis. *Int J Dermatol* **33**: 779–82.
- 181 Richardson D, Schwartz R. (1984) Comparison of resting capillary flow dynamics in the finger and toe nail folds. *Microcirc Endothel Lymphat* **1**: 645–56.
- 182 Krylova NV, Soboleva TM. (1995) The use of capillaroscopy of the skin of the nail wall in personal identification. *Sud Med Ekspert* **38**: 16–19.
- 183 Bollinger A, Jäger K, Roten A, Timeus C, Mahler F. (1979) Diffusion, pericapillary distribution and clearance of Na-fluorescein in the human nail fold. *Pflügers Arch* **382**: 137–43.
- 184 Grassi W, Felder M, Thüring-Vollenweider U, Bollinger A. (1989) Microvascular dynamics at the nail fold in rheumatoid arthritis. *Clin Exp Rheumatol* **7**: 47–53.
- 185 Mahler F, Saner H, Boss C *et al.* (1987) Local cold exposure test for capillaroscopic examination of patients with Raynaud's syndrome. *Microvasc Res* **33**: 422–7.
- 186 Hansen SW, Olsen N, Rossing N, Rorth M. (1990) Vascular toxicity and the mechanism underlying Raynaud's phenomenon in patients treated with cisplatin, vinblastine and bleomycin. *Ann Oncol* **1**: 289–92.
- 187 Klyszcz T, Hahn M, Rassner G, Jünger M. (1997) The technical construction of a computer-supported measuring unit for in-vivo capillary pressure measurement in human nail fold capillaries. *Biomed Tech (Berl)* **42**: 310–18.
- 188 Wu CC, Zhang G, Huang TC, Lin KP. (2009) Red blood cell velocity measurements of complete capillary in finger nail-fold using optical flow estimation. *Microvasc Res* **78**: 319–24.
- 189 Mugii N, Hasegawa M, Hamaguchi Y *et al.* (2009) Reduced red blood cell velocity in nail-fold capillaries as a sensitive and specific indicator of microcirculation injury in systemic sclerosis. *Rheumatology (Oxford)* **48**: 696–703.
- 190 Cutolo M, Ferrone C, Pizzorni C, Soldano S, Seriole B, Sulli A. (2010) Peripheral blood perfusion correlates with microvascular abnormalities in systemic sclerosis: a laser-Doppler and nailfold videocapillaroscopy study. *J Rheumatol* **37**(6): 1174–80.
- 191 Schnitzler L, Baran R, Civatte J, Schubert B, Verret JL, Hurez D. (1976) Biopsy of the proximal nail fold in collagen diseases. *J Dermatol Surg* **2**: 313–15.
- 192 Masson P (ed). (1937) *Les Glomus Neurovasculaires*. Paris: Hermann.
- 193 Wilgis EF, Maxwell GP. (1979) Distal digital nerve graft. *J Hand Surg* **4**: 439–43.
- 194 Zook EG. (1988) Injuries of the fingernail. In: Green DP (ed) *Operative Hand Surgery*, 2nd edn. New York: Churchill Livingstone.
- 195 Winkelmann RK. (1960) Similarities in cutaneous nerve end-organs. In: Montagna W (ed) *Advances in Biology of Skin: Cutaneous Innervation*. New York: Pergamon, pp. 48–62.
- 196 Bas H, Kleinert JM. (1999) Anatomic variations in sensory innervation of the hand and digits. *J Hand Surg Am* **24**: 1171–84.
- 197 Barbareschi M, Cambiaghi S, Crupi AC, Tadini G. (1997) Family with 'pure' hair-nail ectodermal dysplasia. *Am J Med Genet* **72**: 91–3.
- 198 Murdoch-Kinch CA, Miles DA, Poon CK. (1993) Hypodontia and nail dysplasia syndrome. Report of a case. *Oral Surg Oral Med Oral Pathol* **75**: 403–6.
- 199 Garzon MC, Paller AS. (1996) What syndrome is this? Witkop tooth and nail syndrome. *Pediatr Dermatol* **13**: 63–4.
- 200 Smith FJ, Corden LD, Rugg EL *et al.* (1997) Missense mutations in keratin 17 cause either pachyonychia congenita type 2 or a phenotype resembling steatocystoma multiplex. *J Invest Dermatol* **108**: 220–3.
- 201 Achten G. (1968) Normale histologie und histochemie des nagels. In: Jadassohn J (ed) *Handbuch der Haut und Geschlechtskrankheiten*, vol. 1. Berlin: Springer-Verlag, pp. 339–76.
- 202 Perrin C. (2007) Expression of follicular sheath keratins in the normal nail with special reference to the morphological analysis of the distal nail unit. *Am J Dermatopathol* **29**: 543–50.
- 203 Templeton SF, Wiegand SE. (1997) Pachyonychia congenital-associated alopecia. A microscopic analysis using transverse section technique. *Am J Dermatopathol* **19**: 180–4.
- 204 Ito T, Ito N, Saathoff M *et al.* (2005) Immunology of the human nail apparatus: the nail matrix is a site of relative immune privilege. *J Invest Dermatol* **125**: 1139–48.
- 205 Spearman RI (1978) The physiology of the nail. In: Jarrett A (ed) *The Physiology and Pathophysiology of the Skin*, vol. 5. New York: Academic Press, p. 1827.
- 206 Lucas AM, Strettenheim PR. (1972) *Avian Anatomy Integument*. Part 2. Agricultural Handbook No. 362. Washington DC: US Government Printing Office.
- 207 Kato T. (1977) A study on the development of the cat claw. *Hiroshima J Med Sci* **26**: 103–26.
- 208 Mueller RS, Sterner-Kock A, Stannard AA. (1993) Microanatomy of the canine claw. *Vet Dermatol* **4**: 5–11.
- 209 Gillespie JM, Marshall RC, Woods EF. (1982) A comparison of lizard claw keratin proteins with those of avian beak and claw. *J Mol Evol* **18**: 121–9.
- 210 Scott DW, Miller WH. (1992) Disorders of the claw and clawbed in dogs. *Compendium* **14**: 1448–58.
- 211 Pautard FG. (1964) Calcification of keratin. In: Rook AJ, Champion RE (eds) *Progress in Biological Sciences in Relation to Dermatology*, vol. 2. Cambridge: Cambridge University Press, p. 227.
- 212 Harvey RG, Markwell PJ. (1996) The mineral composition of nails in normal dogs and comparison with shed nails in canine idiopathic onychomadesis. *Vet Dermatol* **7**: 29–34.
- 213 Bowden PE, Henderson H, Reilly JD. (2009) Defining the complex epithelia that comprise the canine claw with molecular markers of differentiation. *Vet Dermatol* **20**: 347–59.
- 214 Alibardi L, Toni M. (2009) Immunocytochemistry and protein analysis suggest that reptilian claws contain small high cysteine-glycine proteins. *Tissue Cell* **41**: 180–92.

- 215 Carter RA, Shekk V, de Laat MA, Pollitt CC, Galantino-Homer HL. (2010) Novel keratins identified by quantitative proteomic analysis as the major cytoskeletal proteins of equine (*Equus caballus*) hoof lamellar tissue. *J Anim Sci* **88**: 3843–55.
- 216 Chen J, Jaeger K, Den Z, Koch PJ, Sundberg JP, Roop DR. (2008) Mice expressing a mutant Krt75 (K6hf) allele develop hair and nail defects resembling pachyonychia congenita. *J Invest Dermatol* **128**: 270–9.
- 217 Akhtar W, Edwards HG. (1997) Fourier-transform Raman spectroscopy of mammalian and avian keratotic biopolymers. *Spectrochim Acta A Mol Biomol Spectrosc* **53A**: 81–90.
- 218 Sisson S, Grossman JD (eds). (1953) *The Anatomy of the Domestic Animals*. Philadelphia: W.B. Saunders.
- 219 Norton LA. (1971) Incorporation of thymidine-methyl-H3 and glycine-2-H3 in the nail matrix and bed of humans. *J Invest Dermatol* **56**: 61–8.
- 220 De Berker D, Angus B. (1996) Proliferative compartments in the normal nail unit. *Br J Dermatol* **135**: 555–9.
- 221 Johnson M, Schuster S. (1993) Continuous formation of nail along the nail bed. *Br J Dermatol* **128**: 277–80.
- 222 Heikkilä H, Stubb S, Kiistala U. (1996) Nail growth measurement employing nail indentation: an experimental follow-up study of nail growth in situ. *Clin Exp Dermatol* **21**: 96–9.
- 223 De Berker D. (1997) Nail growth measurement by indentation. *Clin Exp Dermatol* **22**: 109.
- 224 Nishi G, Shibata Y, Tago K *et al.* (1996) Nail regeneration in digits replanted after amputation through the distal phalanx. *J Hand Surg* **21A**: 229–33.
- 225 Libbin RM, Neufeld DA. (1988) Regeneration of the nail bed. *Plast Reconstr Surg* **81**: 1001–2.
- 226 Kligman A. (1961) Why do nails grow out instead of up? *Arch Dermatol* **84**: 181–3.
- 227 Baran R. (1981) Nail growth direction revisited. *J Am Acad Dermatol* **4**: 78–83.
- 228 Kikuchi I, Ogata K, Idemori M. (1984) Vertically growing ectopic nail. *J Am Acad Dermatol* **10**: 114–16.
- 229 Tosti A, Morelli R, d'Alessandro R, Bassi F. (1993) Carpal tunnel syndrome presenting with ischemic skin lesions, acroosteolysis and nail changes. *J Am Acad Dermatol* **29**: 287–90.
- 230 Todd G, Saxe N. (1994) Idiopathic phalangeal osteolysis. *Arch Dermatol* **130**: 759–62.
- 231 Gilchrist M, Dudley Buxton LH. (1938) The relation of fingernail growth to nutritional status. *J Anat* **9**: 575–82.
- 232 Hillman R. (1955) Fingernail growth in the human subject. *Hum Biol* **27**: 274–83.
- 233 Dawber R. (1970) Fingernail growth in normal and psoriatic subjects. *Br J Dermatol* **82**: 454–7.
- 234 Babcock MJ. (1955) Methods for measuring fingernail growth rates in nutritional studies. *J Nutr* **55**: 323–36.
- 235 Sibinga MS. (1959) Observations on growth of fingernails in health and disease. *Pediatrics* **24**: 225–33.
- 236 Yu HJ, Kwon HM, Oh DH, Kim JS. (2004) Is slow nail growth a risk factor for onychomycosis? *Clin Exp Dermatol* **29**: 415–18.
- 237 De Doncker P, Piérard GE. (1994) Acquired nail beading in patients receiving itraconazole: an indicator of faster nail growth? A study using optical profilometry. *Clin Exp Dermatol* **19**: 404–6.
- 238 Hamilton JB, Terada H, Mestler GE. (1955) Studies of growth throughout the lifespan in Japanese: growth and size of nails and their relationship to age, sex heredity and other factors. *J Gerontol* **10**: 401–15.
- 239 Fukushima R, Rigolizzo DS, Maia LP, Sampaio FC, Lauris JR, Buzalaf MA. (2009) Environmental and individual factors associated with nail fluoride concentration. *Caries Res* **43**: 147–54.
- 240 McDonnell ST, O'Mullane D, Cronin M, MacCormac C, Kirk J. (2004) Relevant factors when considering fingernail clippings as a fluoride biomarker. *Community Dent Health* **21**: 19–24.
- 241 Yaemsiri S, Hou N, Slining MM, He K. (2010) Growth rate of human fingernails and toenails in healthy American young adults. *J Eur Acad Dermatol Venereol* **24**: 420–3.
- 242 Hewitt D, Hillman RW. (1966) Relation between rate of nail growth in pregnant women and estimated previous general growth rate. *Am J Clin Nutr* **19**: 436–9.
- 243 Bean WB. (1980) Nail growth. Thirty five years of observation. *Arch Intern Med* **140**: 73–6.
- 244 Geoghegan B, Roberts DF, Sampford MR. (1958) A possible climatic effect on nail growth. *J Appl Physiol* **13**: 135–8.
- 245 Donovan KM. (1977) Antarctic environment and nail growth. *Br J Dermatol* **96**: 507–10.
- 246 Gormly PJ, Ledingham JE. (1983) Nail growth in antarctic conditions. *Australas J Dermatol* **24**: 86–9.
- 247 Geyer AS, Onumah N, Uyttendaele H, Scher RK. (2004) Modulation of linear nail growth to treat diseases of the nail. *J Am Acad Dermatol* **50**: 229–34.
- 248 Weismann K. (1977) J.H.S. Beau and his descriptions of transverse depressions on nails. *Br J Dermatol* **97**: 571–2.
- 249 Moffitt DL, de Berker DA. (2000) Yellow nail syndrome: the nail that grows half as fast grows twice as thick. *Clin Exp Dermatol* **25**: 21–3.
- 250 Uyttendaele H, Geyer A, Scher RK. (2003) Brittle nails: pathogenesis and treatment. *J Drugs Dermatol* **2**: 48–9.
- 251 Dawber RP, Samman P, Bottoms E. (1971) Fingernail growth in idiopathic and psoriatic onycholysis. *Br J Dermatol* **85**: 558–60.
- 252 Galosi A, Plewig G, Braun-Falco O. (1985) The effect of aromatic retinoid RO 10-9359 on fingernail growth. *Arch Dermatol Res* **277**: 138–40.
- 253 Dawber RP. (1970) The effect of methotrexate, corticosteroids and azathioprine on fingernail growth in psoriasis. *Br J Dermatol* **83**: 680–3.
- 254 Baran R, Belaich S, Beylot C. (1997) Comparative multicenter double-blind study of terbinafine (250 mg per day) versus griseofulvin (1 g per day) in the treatment of dermatophyte onychomycosis. *J Dermatol Treat* **8**: 93–7.
- 255 Slotnick MJ, Nriagu JO. (2006) Validity of human nails as a biomarker of arsenic and selenium exposure: a review. *Environ Res* **102**: 125–39.
- 256 Nowak B. (1996) Occurrence of heavy metals, sodium, calcium and potassium in human hair, teeth and nails. *Biol Trace Elem Res* **52**: 11–22.
- 257 Gniadecka M, Nielsen O, Christensen D *et al.* (1998) Structure of water, proteins and lipids in intact human skin, hair and nail. *J Invest Dermatol* **110**: 393–8.
- 258 Gillespie JM, Frenkel MJ. (1974) The diversity of keratins. *Comp Biochem Physiol* **47B**: 339–46.
- 259 Marshall RC. (1980) Genetic variation in the proteins of the human nail. *J Invest Dermatol* **75**: 264–9.
- 260 Forslind B. (1970) Biophysical studies of the normal nail. *Acta Derm Venereol* **50**: 161–8.
- 261 Hanukoglu I, Fuchs E. (1983) The cDNA sequence of a human epidermal keratin: divergence of sequence but conservation of structure among intermediate filaments. *Cell* **31**: 243–51.
- 262 Kitahara T, Ogawa H. (1991) The extraction and characterisation of human nail keratin. *J Dermatol Sci* **2**: 402–6.
- 263 Zaias N (ed). (1989) *The Nail in Health and Disease*, 2nd edn. Norwalk, CT: Appleton and Lange, pp. 12–13.
- 264 Djaldetti M, Fishman P, Harpaz D, Lurie B. (1987) X-ray microanalysis of the fingernails in cirrhotic patients. *Dermatologica* **174**: 114–16.
- 265 Alexiou D, Koutsclinis A, Manolidis C *et al.* (1980) The content of trace elements in fingernails of children. *Dermatology* **160**: 380–2.
- 266 Lakshmi Priya MD, Geetha A. (2011) A biochemical study on the level of proteins and their percentage of nitration in the hair and nail of autistic children. *Clin Chim Acta* **412**: 1036–42.
- 267 Jacobs A, Jenkins DJ. (1960) The iron content of fingernails. *Br J Dermatol* **72**: 145–8.

- 268 Oimomi M, Maeda Y, Hata F *et al.* (1985) Glycosylation levels of nail proteins in diabetic patients with retinopathy and neuropathy. *Kobe J Med Sci* **31**: 183–8.
- 269 Sueki H, Nozaki S, Fujisawa R *et al.* (1989) Glycosylated proteins of skin, nail and hair: application as an index for long-term control of diabetes mellitus. *J Dermatol* **16**: 103–10.
- 270 Matsumoto T, Sakura N, Ueda K. (1990) Steroid sulphatase activity in nails: screening for X-linked ichthyosis. *Pediatr Dermatol* **7**: 266–9.
- 271 Serizawa S, Nagai T, Ito M, Sato Y. (1990) Cholesterol sulphate levels in the hair and nails of patients with recessive X-linked ichthyosis. *Clin Exp Dermatol* **15**: 13–15.
- 272 Salamon T, Lazovic-Tepavac O, Nikulin A *et al.* (1988) Sudan IV positive material of the nail plate related to plasma triglycerides. *Dermatologica* **176**: 52–4.
- 273 Behne D, Gessner H, Kyriakopoulos A. (1996) Information on the selenium status of several body compartments of rats from the selenium concentrations in blood fractions, hair and nails. *J Trace Elem Med Biol* **10**: 174–9.
- 274 Rogers M, Thomas DB, Davis S *et al.* (1991) A case control study of oral cancer and pre-diagnostic concentrations of selenium and zinc in nail tissue. *Int J Cancer* **48**: 182–8.
- 275 Van den Brandt PA, Goldbohm RA, vant Veer P *et al.* (1994) Toenail selenium levels and the risk of breast cancer. *Am J Epidemiol* **140**: 20–6.
- 276 Yoshizawa K, Willett WC, Morris SJ *et al.* (1998) Study of the prediagnostic selenium levels in toenails and the risk of advanced prostate cancer. *J Natl Cancer Inst* **90**, 1219–24.
- 277 Garland M, Morris JS, Colditz GA *et al.* (1996) Toenail trace element levels and breast cancer: a prospective study. *Am J Epidemiol* **144**: 653–60.
- 278 Vannucchi HF, Fávvaro RM, Cunha DF, Marchini JS. (1995) Assessment of zinc nutritional status of pellagra patients. *Alcohol Alcohol* **30**: 297–302.
- 279 Kaneshige T, Takagi K, Nakamura S, Hirasawa T, Sada M, Uchida K. (1992) Genetic analysis using fingernail DNA. *Nucleic Acids Res* **20**: 5489–90.
- 280 Allouche M, Hamdoum M, Mangin P, Castella V. (2008) Genetic identification of decomposed cadavers using nails as DNA source. *Forens Sci Int Genet* **3**: 46–9.
- 281 Wilhelm M, Hafner D, Lombeck I, Ohnesorge FK. (1991) Monitoring of cadmium, copper, lead and zinc status in young children using toenails: comparison with scalp hair. *Sci Total Environ* **103**: 199–207.
- 282 Hussein Were F, Njue W, Murungi J, Wanjau R. (2008) Use of human nails as bio-indicators of heavy metals environmental exposure among school age children in Kenya. *Sci Total Environ* **393**: 376–84.
- 283 Tang YR, Zhang SQ, Xiong Y *et al.* (2003) Studies of five microelement contents in human serum, hair, and fingernails correlated with aged hypertension and coronary heart disease. *Biol Trace Elem Res* **92**: 97–104.
- 284 Das D, Chatterjee A, Badal K *et al.* (1995) Arsenic in ground water in six districts of West Bengal, India: the biggest arsenic calamity in the world. *Analyst* **120**: 917–24.
- 285 Harrington J, Middaugh J, Morse D, Housworth J. (1978) A survey of a population exposed to high concentrations of arsenic in well water in Fairbanks, Alaska. *Am J Epidemiol* **108**: 377–85.
- 286 Karagas MR, Morris JS, Weiss JE. (1996) Toenail samples as an indicator of drinking water arsenic exposure. *Cancer Epidemiol Biomarkers Prev* **5**: 849–52.
- 287 Mordukhovich I, Wright RO, Amarasiwardena C *et al.* (2009) Association between low-level environmental arsenic exposure and QT interval duration in a general population study. *Am J Epidemiol* **170**: 739–46.
- 288 Al-Delaimy WK, Stampfer MJ, Manson JE, Willett WC. (2008) Toenail nicotine levels as predictors of coronary heart disease among women. *Am J Epidemiol* **167**: 1342–8.
- 289 Gamelgaard B, Anderson JR. (1985) Determination of nickel in human nails by adsorption differential-pulse voltammetry. *Analyst* **110**: 1197–9.
- 290 Suzuki O, Hattori H, Asano M. (1984) Nails as useful materials for detection of methamphetamine or amphetamine abuse. *Forens Sci Int* **24**: 9–16.
- 291 Suzuki S, Inoue T, Hori H, Inayama S. (1989) Analysis of methamphetamine in hair, nail, sweat and saliva by mass fragmentography. *J Anal Toxicol* **13**: 176–8.
- 292 Miller M, Martz R, Donnelly B. (1994) Drugs in keratin samples from hair, fingernails and toenails (abstract). Presented at the Second International Meeting on Clinical and Forensic Aspects of Hair Analysis, Genoa, Italy, June 6–8, p. 39.
- 293 Cirimele V, Kintz P, Mangin P. (1995) Detection of amphetamines in fingernails: an alternative to hair analysis. *Arch Toxicol* **70**: 68–9.
- 294 Skopp G, Pötsch L. (1997) A case report on drug screening of nail clippings to detect prenatal drug exposure. *Ther Drug Monit* **19**: 386–9.
- 295 Dykes PJ, Thomas R, Finlay AY. (1990) Determination of terbinafine in nail samples during treatment for onychomycoses. *Br J Dermatol* **123**: 481–6.
- 296 Matthieu L, de Doncker P, Cauwenburgh G *et al.* (1991) Itraconazole penetrates the nail via the nail matrix and the nail bed: an investigation in onychomycosis. *Clin Exp Dermatol* **16**: 374–6.
- 297 Munro CS, Shuster S. (1992) The route of rapid access of drugs to the distal nail plate. *Acta Derm Venereol* **72**: 387–8.
- 298 Rashid A, Scott EM, Richardson MD. (1995) Inhibitory effect of terbinafine on the invasion of nails by Trichophyton mentagrophytes. *J Am Acad Dermatol* **33**: 718–23.
- 299 Ofori-Adjei D, Ericsson O. (1985) Chloroquine in nail clippings. *Lancet* **2**(8450): 331.
- 300 Baden HP. (1970) The physical properties of nail. *J Invest Dermatol* **55**: 115.
- 301 Maloney MJ, Paquette EG. (1977) The physical properties of fingernails. I. Apparatus for physical measurements. *J Soc Comp Chem* **28**: 415.
- 302 Finlay AF, Frost P, Keith AC, Snipes W. (1980) An assessment of factors influencing flexibility of human fingernails. *Br J Dermatol* **103**: 357–65.
- 303 Wessel S, Gniadecka M, Jemec GB, Wulf HC. (1999) Hydration of human nails investigated by NIR-FT-Raman spectroscopy. *Biochim Biophys Acta* **17**: 210–16.
- 304 Zaun H. (1997) Brittle nails. Objective assessment and therapy follow-up. *Hautarzt* **48**: 455–61.
- 305 Spruit D. (1972) Effect of nail polish on hydration of the fingernail. *Am Cosm Perf* **87**: 57–8.
- 306 Jemec GB, Agner T, Serup J. (1989) Transonychia water loss: relation to sex, age and nail plate thickness. *Br J Dermatol* **121**: 443–6.
- 307 Walters KA, Flynn GL, Marvel JR. (1983) Physicochemical characterisation of the human nail: permeation pattern for water and the homologous alcohols and differences with respect to the stratum corneum. *J Pharm Pharmacol* **35**: 28–33.
- 308 Gunt HB, Miller MA, Kasting GB. (2007) Water diffusivity in human nail plate. *J Pharm Sci* **96**: 3352–62.
- 309 Kobayashi Y, Miyamoto M, Sugibayashi K, Morimoto Y. (1998) Enhancing effect of N-acetyl-L-cysteine or 2-mercaptoethanol on the in vitro permeation of 5-fluorouracil or tolnaftate through the human nail plate. *Chem Pharm Bull (Tokyo)* **46**: 1797–802.
- 310 Mertin D, Lippold BC. (1997) In vitro permeability of the human nail and of a keratin membrane from bovine hooves: penetration of chloramphenicol from lipophilic vehicles and a nail lacquer. *J Pharm Pharmacol* **49**: 241–5.
- 311 Yang D, Chaumont JP, Makki S, Millet-Clerc J. (1997) Un nouveau modèle de simulation pour étudier la pénétration topique d'antifongiques en kératine dure in vitro. *J Mycol Med* **7**: 195–8.

- 312 Pittrof F, Gerhards J, Erni W. (1992) Loceryl nail lacquer: realization of a new galenical approach to onychomycosis therapy. *Clin Exp Dermatol* **17**(Suppl 1): 26–8.
- 313 Kim JH, Lee CH, Choi HK. (2001) A method to measure the amount of drug penetrated across the nail plate. *Pharm Res* **18**: 1468–71.
- 314 Spruit D. (1971) Measurement of water vapor loss through human nail in vivo. *J Invest Dermatol* **56**: 359–61.
- 315 Walters KA, Flynn GL, Marvel JR. (1981) Physicochemical characterization of the human nail: 1. Pressure sealed apparatus for measuring nail plate permeability. *J Invest Dermatol* **76**: 76–9.
- 316 Mertin D, Lippold BC. (1997) In vitro permeability of the human nail and of a keratin membrane from bovine hooves: influence of the partition coefficient octanol/water and the water solubility of drugs on their permeability and maximum flux. *J Pharm Pharmacol* **49**: 30–4.
- 317 Walters KA, Flynn GL, Marvel JR. (1985) Physicochemical characterisation of the human nail: solvent effects on the permeation of homologous alcohols. *J Pharm Pharmacol* **37**: 771–5.
- 318 Mertin D, Lippold BC. (1997) In vitro permeability of the human nail and of a keratin membrane from bovine hooves: prediction of the penetration rate of antimycotics through the nail plate and their efficacy. *J Pharm Pharmacol* **49**: 866–72.
- 319 Quintanar-Guerrero D, Ganem-Quintanar A, Tapia-Olguin P, Kalia YN, Buri P. (1998) The effect of keratolytic agents on the permeability of three imidazole antimycotic drugs through the human nail. *Drug Dev Ind Pharm* **24**: 685–90.
- 320 Kobayashi Y, Komatsu T, Sumi M *et al.* (2004) In vitro permeation of several drugs through the human nail plate: relationship between physicochemical properties and nail permeability of drugs. *Eur J Pharm Sci* **21**: 471–7.
- 321 Stüttgen G, Bauer E. (1982) Bioavailability, skin and nail penetration of topically applied antimycotics. *Mykosen* **25**: 74–80.
- 322 Franz TJ. (1992) Absorption of amorolfine through human nail. *Dermatology* **184**(Suppl 1): 18–20.
- 323 Ceschin-Roques CG, Hanel H, Pruja-Bougaret SM, Luc J, Vandermander J, Michel G. (1991) Ciclopirox nail lacquer 8%: in vivo penetration into and through nails. *Skin Pharmacol* **4**: 89–94.
- 324 Mensing H, Splanemann V. (1991) Evaluation of the antimycotic activity of the pathological substance under the nail after treatment with RO 14-4767 nail lacquer. In: Proceedings of the 1st EADV Congress. Oxford: Blackwell Scientific Publications, pp. 21–2.
- 325 Walters KA, Flynn GL, Marvel JR. (1985) Penetration of the human nail plate: the effects of vehicle pH on the permeation of miconazole. *J Pharm Pharmacol* **37**: 418–19.
- 326 Marty JP, Dervault AM. (1991) Voie percutanée. In: Dubertret L (ed) *Thérapeutique Dermatologique*. Paris: Medecine Sciences Flammarion, pp. 649–63.
- 327 Narasimha Murthy S, Wiskirchen DE, Bowers CP. (2007) Iontophoretic drug delivery across human nail. *J Pharm Sci* **96**: 305–11.
- 328 Dutet J, Delgado-Charro MB. (2009) In vivo transungual iontophoresis: effect of DC current application on ionic transport and on transungual water loss. *J Control Release* **140**: 117–25.
- 329 Hao J, Smith KA, Li SK. (2009) Iontophoretically enhanced ciclopirox delivery into and across human nail plate. *J Pharm Sci* **98**: 3608–16.
- 330 Amichai B, Mosckovitz R, Trau H *et al.* (2010) Iontophoretic terbinafine HCL 1.0% delivery across porcine and human nails. *Mycopathologia* **169**: 343–9.
- 331 Smith KA, Hao J, Li SK. (2010) Influence of pH on transungual passive and iontophoretic transport. *J Pharm Sci* **99**: 1955–67.
- 332 Dutet J, Delgado-Charro MB. (2010) Transungual iontophoresis of lithium and sodium: effect of pH and co-ion competition on cationic transport numbers. *J Control Release* **144**: 168–74.
- 333 Amichai B, Nitzan B, Mosckovitz R, Shemer A. (2010) Iontophoretic delivery of terbinafine in onychomycosis: a preliminary study. *Br J Dermatol* **162**: 46–50.
- 334 Dutet J, Delgado-Charro MB. (2010) Electroosmotic transport of mannitol across human nail during constant current iontophoresis. *J Pharm Pharmacol* **62**: 721–9.
- 335 Nair AB, Chakraborty B, Murthy SN. (2010) Effect of polyethylene glycols on the trans-ungual delivery of terbinafine. *Curr Drug Deliv* **7**: 407–14.
- 336 Nair AB, Kiran Vaka SR, Murthy SN. (2011) Transungual delivery of terbinafine by iontophoresis in onychomycotic nails. *Drug Dev Ind Pharm* **37**: 1253–8.
- 337 Kobayashi Y, Miyamoto M, Sugibayashi K, Morimoto Y. (1999) Drug permeation through the three layers of the human nail plate. *J Pharm Pharmacol* **51**: 271–8.
- 338 Mayer PR, Couch RC, Erickson MK, Woodbridge CB, Brazzell RK. (1992) Topical and systemic absorption of sodium pyriithone following topical application to the nails of the rhesus monkey. *Skin Pharmacol* **5**: 154–9.
- 339 Rai MK, Qureshi S. (1994) Screening of different keratin baits for isolation of keratinophilic fungi. *Mycoses* **37**: 295–8.
- 340 Halkier-Sørensen L, Cramers M, Kragballe K. (1990) Twenty nail dystrophy treated with topical PUVA. *Acta Derm Venereol* **70**: 510–11.
- 341 Baran R, Juhlin L. (1987) Drug induced photo onycholysis. *J Am Acad Dermatol* **17**: 1012–16.
- 342 Beltrani V, Scher R. (1991) Evaluation and management of melanonychia striata in a patient receiving phototherapy. *Arch Dermatol* **127**: 319–20.
- 343 Onukak EE. (1980) Squamous cell carcinoma of the nail bed. Diagnosis and therapeutic problems. *Br J Surg* **67**: 893–5.
- 344 Baran R, Gormley DE. (1987) Polydactylous Bowen's disease of the nail. *J Am Acad Dermatol* **17**: 201–4.
- 345 Parker SG, Diffey BL. (1983) The transmission of optical radiation through human nails. *Br J Dermatol* **108**: 11–16.
- 346 Yu RC, King CM. (1992) A double blind study of superficial radiotherapy in psoriatic nail dystrophy. *Acta Derm Venereol* **72**: 134–6.
- 347 Kwang TY, Nee TS, Seng KT. (1994) A therapeutic study of nail psoriasis using electron beams (letter). *Acta Derm Venereol* **75**: 90.
- 348 Hao J, Smith KA, Li SK. (2010) Time-dependent electrical properties of human nail upon hydration in vivo. *J Pharm Sci* **99**: 107–18.
- 349 Moreira AL, Porto NS, Moreira JS, Ulbrich-Kulczynski JM, Irion KL. (2008) Clubbed fingers: radiological evaluation of the nail bed thickness. *Clin Anat* **21**: 314–18.
- 350 Foucher G, Lemarchal P, Citron N, Merle M. (1987) Osteoid osteoma of the distal phalanx: a report of four cases and review of the literature. *J Hand Surg Br* **12**: 382–6.
- 351 Pang HN, Yi-Liang Lee J, Beng-Hoi Tan A. (2009) Pincer nails complicated by distal phalangeal osteomyelitis. *J Plast Reconstr Aesthet Surg* **62**: 254–7.
- 352 Tosti A, Peluso AM, Bardazzi F, Morelli R, Bassi F. (1994) Phalangeal osteomyelitis due to nail biting. *Acta Derm Venereol* **74**: 206–7.
- 353 Peterson SR, Layton EG, Joseph AK. (2004) Squamous cell carcinoma of the nail unit with evidence of bony involvement: a multidisciplinary approach to resection and reconstruction. *Dermatol Surg* **30**: 218–21.
- 354 Ryu JS, Cho JW, Moon TH, Lee HL, Han HS, Choi GS. (2000) Squamous cell lung cancer with solitary subungual metastasis. *Yonsei Med J* **41**: 666–8.
- 355 Lumpkin LR, Rosen T, Tschen JA. (1984) Subungual squamous cell carcinoma. *J Am Acad Dermatol* **11**: 735–8.
- 356 Mathis WH, Schulz MD. (1948) Roentgen diagnosis of glomus tumours. *Radiology* **51**: 71–6.
- 357 Van Geertruyden J, Lorea P, Goldschmidt D *et al.* (1996) Glomus tumours of the hand. A retrospective study of 51 cases. *J Hand Surg Br* **21**: 257–60.
- 358 Camirand P, Giroux JM. (1970) Subungual glomus tumour. Radiological manifestations. *Arch Dermatol* **102**: 677–9.

- 359 Takemura N, Fujii N, Tanaka T. (2006) Subungual glomus tumor diagnosis based on imaging. *J Dermatol* **33**: 389–93.
- 360 Jablon M, Horowitz A, Bernstein DA. (1990) Magnetic resonance imaging of a glomus tumour of the finger tip. *J Hand Surg* **15A**: 507–9.
- 361 Holzberg M. (1992) Glomus tumour of the nail. *Arch Dermatol* **128**: 160–2.
- 362 Goettmann S, Drape JL, Idy-Peretti I *et al.* (1994) Magnetic resonance imaging: a new tool in the diagnosis of tumours of the nail apparatus. *Br J Dermatol* **130**: 701–10.
- 363 Drapé JL, Idy-Peretti I, Goettmann S *et al.* (1996) Standard and high resolution MRI in glomus tumours of toes and fingertips. *J Am Acad Dermatol* **35**: 550–5.
- 364 Drapé JL, Idy-Peretti I, Goettmann S *et al.* (1996) MR imaging of digital mucoid cysts. *Radiology* **200**: 531–6.
- 365 Drapé JL, Wolfram-Gabel R, Idy-Peretti I *et al.* (1996) The lunula: a magnetic resonance imaging approach to the subnail matrix area. *J Invest Dermatol* **106**: 1081–5.
- 366 Tan AL, McGonagle D. (2010) Psoriatic arthritis: correlation between imaging and pathology. *Joint Bone Spine* **77**: 206–11.
- 367 Al-Qattan MM, Al-Namla A, Al-Thunayan A, Al-Subhi F, El-Shayeb AF. (2005) Magnetic resonance imaging in the diagnosis of glomus tumours of the hand. *J Hand Surg Br* **30**: 535–40.
- 368 Wortsman X, Jemec GBE (2006) Ultrasound imaging of nails. *Dermatol Clin* **24**: 323–8.
- 369 Fornage BD. (1988) Glomus tumours in the fingers: diagnosis with US. *Radiology* **167**: 183–5.
- 370 Wortsman X, Jemec GB. (2009) Role of high-variable frequency ultrasound in preoperative diagnosis of glomus tumors: a pilot study. *Am J Clin Dermatol* **10**: 23–7.
- 371 Gutierrez M, Wortsman X, Filippucci E, de Angelis R, Filosa G, Grassi W. (2009) High resolution high-frequency sonography in the evaluation of psoriasis: nail and skin involvement. *J Ultrasound Med* **28**: 1569–74.
- 372 Corcuff P, de Rigal J, Lévêque JL, Makki S, Agache P. (1983) Skin relief and ageing. *J Soc Cosm Chem* **34**: 177–90.
- 373 Grove GL, Grove MJ, Leyden JJ. (1989) Optical profilometry: an objective method for quantification of facial wrinkles. *J Am Acad Dermatol* **21**: 631–7.
- 374 Ablal MA, Kaur JS, Cooper L *et al.* (2009) The erosive potential of some alopecops using bovine enamel: an in vitro study. *J Dent* **37**: 835–9.
- 375 Nikkels-Tassoudji N, Piérard-Franchimont C, de Doncker P, Piérard GE. (1995) Optical profilometry of nail dystrophies. *Dermatology* **190**: 301–4.
- 376 Piérard GE, Piérard-Franchimont C. (1996) Dynamics of psoriatic trachyonychia during low dose cyclosporin A treatment: a pilot study on onychochronobiology using optical profilometry. *Dermatology* **192**: 116–19.
- 377 Iorizzo M, Dahdah M, Vincenzi C, Tosti A. (2008) Videodermoscopy of the hyponychium in nail bed psoriasis. *J Am Acad Dermatol* **58**: 714–15.
- 378 Gewirtzman AJ, Saurat JH, Braun RP. (2003) An evaluation of dermoscopy fluids and application techniques. *Br J Dermatol* **149**(1): 59–63.
- 379 Zalaudek I, Docimo G, Argenziano G. (2009) Using dermoscopic criteria and patient-related factors for the management of pigmented melanocytic nevi. *Arch Dermatol* **145**: 816–26.
- 380 Stolz W, Braun-Falco O, Bilek P, Landthaler M, Cagnetta AB. (1994) Pigmented lesions on hands and feet. In: Stolz W (ed) *Color Atlas of Dermatoscopy*. Oxford: Blackwell Scientific Publications, pp. 101–7.
- 381 Ronger S, Touzet S, Ligeron C *et al.* (2002) Dermoscopic examination of nail pigmentation. *Arch Dermatol* **138**: 1327–33.
- 382 Bilemjian AP, Piñeiro-Maceira J, Barcaui CB, Pereira FB. (2009) Melanonychia: the importance of dermatoscopic examination and of nail matrix/bed observation. *An Bras Dermatol* **84**: 185–9.
- 383 Phan A, Dalle S, Touzet S, Ronger-Savlé S, Balme B, Thomas L. (2010) Dermoscopic features of acral lentiginous melanoma in a large series of 110 cases in a white population. *Br J Dermatol* **162**: 765–71.
- 384 Oztas MO. (2010) Clinical and dermoscopic progression of subungual hematomas. *Int Surg* **95**: 239–41.
- 385 Bakos RM, Bakos L. (2006) Use of dermoscopy to visualize punctate hemorrhages and onycholysis in “playstation thumb”. *Arch Dermatol* **142**: 1664–5.
- 386 Braun RP, Baran R, Saurat JH, Thomas L. (2006) Surgical Pearl: Dermoscopy of the free edge of the nail to determine the level of nail plate pigmentation and the location of its probable origin in the proximal or distal nail matrix. *J Am Acad Dermatol* **55**: 512–13.
- 387 Sontheimer RD. (2004) A portable digital microphotography unit for rapid documentation of periungual nailfold capillary changes in autoimmune connective tissue diseases. *J Rheumatol* **31**: 539–44.
- 388 Bakos RM, Bakos L. (2008) ‘Whitish chains’: a remarkable in vivo dermoscopic finding of tungiasis. *Br J Dermatol* **159**: 991–2.
- 389 Maehara LS, Ohe EM, Enokihara MY, Michalany NS, Yamada S, Hirata SH. (2010) Diagnosis of glomus tumor by nail bed and matrix dermoscopy. *An Bras Dermatol* **85**: 236–8.
- 390 Criscione V, Telang G, Jellinek NJ. (2010) Onychopapilloma presenting as longitudinal leukonychia. *J Am Acad Dermatol* **63**: 541–2.
- 391 Goyal S, Griffiths WA. (1998) An improved methods of studying fingernail morphometry: application to the early detection of fingernail clubbing. *J Am Acad Dermatol* **39**: 640–2.
- 392 Welzel J, Lankenau E, Birngruber R, Engelhardt R. (1997) Optical coherence tomography of the human skin. *J Am Acad Dermatol* **37**: 958–63.
- 393 Kaufman SC, Beuerman RW, Greer DL. (1995) Confocal microscopy: a new tool for the study of the nail unit. *J Am Acad Dermatol* **32**: 668–70.
- 394 Abuzahra F, Spöler F, Först M *et al.* (2010) Pilot study: optical coherence tomography as a non-invasive diagnostic perspective for real time visualization of onychomycosis. *Mycoses* **53**: 334–9.
- 395 Van der Wall EE, Schuijff JD, Bax JJ, Jukema JW, Schalijs MJ. (2010) Fingertip digital thermal monitoring: a fingerprint for cardiovascular disease? *Int J Cardiovasc Imag* **26**: 249–52.
- 396 Stavem P. (1959) Instrument for estimation of clubbing. *Lancet* **2**: 7–8.
- 397 Bentley D, Moore A, Schwachman H. (1976) Finger clubbing: a quantitative survey by analysis of the shadowgraph. *Lancet* **2**: 164–7.
- 398 Regan GM, Tagg B, Thomson ML. (1967) Subjective measurement and objective measurement of finger clubbing. *Lancet* **1**: 530–2.
- 399 Cudowicz P, Wraith DG. (1957) An evaluation of the clinical significance of clubbing in common lung disorders. *Br J Tuberc Dis Chest* **51**: 14–31.
- 400 Geoghegan B, Roberts DF, Sandford MR. (1958) A possible climactic effect on nail growth. *J Appl Physiol* **13**: 135–7.
- 401 Schick B. (1908) Die physiologische nagellinie des. uglings. *Jahrb Kinderheilk* **67**: 146–60.
- 402 LeGros Clark WE, Buxton LH. (1938) Studies in nail growth. *Br J Dermatol* **50**: 221–9.
- 403 Landherr G, Braun-Falco O, Hofmann C *et al.* (1982) Fingernagelwachstum bei psoriatikern unter puva-therapie. *Hautarzt* **33**: 210–13.
- 404 Dawber RP. (1981) The effect of immobilization upon finger nail growth. *Clin Exp Dermatol* **6**: 533–5.
- 405 Estes SA. (1983) Relapsing polychondritis. *Cutis* **32**: 471–6.
- 406 Baran R. (1982) Action thérapeutique et complications due retinoïde aromatique sur l’appareil ungueal. *Ann Dermatol Vénéréol* **109**: 367–71.
- 407 Miller E. (1973) Levodopa and nail growth. *N Engl J Med* **288**: 916.
- 408 Fenton DA, Wilkinson JD. (1983) Milia, increased nail growth and hypertrichosis following treatment with Benoxapofen. *J R Soc Med* **76**: 525–7.
- 409 Widjaja E, Garland M. (2010) Detection of bio-constituents in complex biological tissue using Raman microscopy. Application to human nail clippings. *Talanta* **80**: 1665–71.

- 410 Widjaja E, Lim GH, An A. (2008) A novel method for human gender classification using Raman spectroscopy of fingernail clippings. *Analyst* **133**: 493–8.
- 411 Perrin C, Baran R, Balaguer T *et al.* (2010) Onychomatricoma: new clinical and histological features. A review of 19 tumors. *Am J Dermatopathol* **32**: 1–8.
- 412 Kreuter A, Gambichler T, Pfister H, Wieland U. (2009) Diversity of human papillomavirus types in periungual squamous cell carcinoma. *Br J Dermatol* **161**: 1262–9.
- 413 Litz CE, Cavagnolo RZ. (2010) Polymerase chain reaction in the diagnosis of onychomycosis: a large, single-institute study. *Br J Dermatol* **163**: 511–14.
- 414 Fujita Y, Kubo S, Yoshida Y, Tokunaga I, Gotohda T, Ishigami A. (2004) Application of AmpFISTR Profiler PCR amplification kit for personal identification of a putrefied cadaver. *J Med Invest* **51**: 243–6.
- 415 Cline RE, Laurent NM, Foran DR. (2003) The fingernails of Mary Sullivan: developing reliable methods for selectively isolating endogenous and exogenous DNA from evidence. *J Forens Sci* **48**: 328–33.
- 416 James VJ. (2009) Fiber diffraction of skin and nails provides an accurate diagnosis of malignancies. *Int J Cancer* **125**(1): 133–8.
- 417 Goullé JP, Sausseureau E, Mahieu L *et al.* (2009) Application of inductively coupled plasma mass spectrometry multielement analysis in fingernail and toenail as a biomarker of metal exposure. *J Anal Toxicol* **33**: 92–8.
- 418 Batista BL, Rodrigues JL, Nunes JA, Tormen L, Curtius AJ, Barbosa F Jr. (2008) Simultaneous determination of Cd, Cu, Mn, Ni, Pb and Zn in nail samples by inductively coupled plasma mass spectrometry (ICP-MS) after tetramethylammonium hydroxide solubilization at room temperature: comparison with ETAAS. *Talanta* **76**: 575–9.
- 419 Kovarik JM, Mueller EA, Zehender H, Denouël J, Caplain H, Millerioux L. (1995) Multiple-dose pharmacokinetics and distribution in tissue of terbinafine and metabolites. *Antimicrob Agents Chemother* **39**: 2738–41.
- 420 Greaves M, Moll JM. (1976) Amino acid composition of human nail, as measured by gas-liquid chromatography. *Clin Chem* **22**: 1608–13.
- 421 Ruben BS. (2010) Pigmented lesions of the nail unit: clinical and histopathologic features. *Semin Cutan Med Surg* **29**: 148–58.
- 422 Xun P, Liu K, Morris JS, Daviglus ML, He K. (2010) Longitudinal association between toenail selenium levels and measures of sub-clinical atherosclerosis: the CARDIA trace element study. *Atherosclerosis* **210**(2): 662–7.
- 423 Gómez-Aracena J, Riemersma RA, Gutiérrez-Bedmar M, Bode P, Kark JD, García-Rodríguez A, Gorgojo L, Van't Veer P, Fernández-Crehuet J, Kok FJ, Martín-Moreno JM; Heavy Metals and Myocardial Infarction Study Group (2006) Toenail cerium levels and risk of a first acute myocardial infarction: the EURAMIC and heavy metals study. *Chemosphere* **64**(1): 112–20.
- 424 Bergomi M, Pellacani G, Vinceti M *et al.* (2005) Trace elements and melanoma. *J Trace Elem Med Biol* **19**: 69–73.
- 425 Jäger K, Fischer H, Tschachler E, Eckhart L. (2007) Terminal differentiation of nail matrix keratinocytes involves up-regulation of DNase1L2 but is independent of caspase-14 expression. *Differentiation* **75**: 939–46.