

# The ECG

A Two-Step Approach to Diagnosis

Bearbeitet von  
Marc Gertsch, C.P Cannon

1. Auflage 2003. Buch. xxxiv, 615 S. Hardcover  
ISBN 978 3 540 00869 9  
Format (B x L): 19,5 x 26 cm  
Gewicht: 2011 g

[Weitere Fachgebiete > Medizin > Klinische und Innere Medizin](#)

Zu [Inhaltsverzeichnis](#)

schnell und portofrei erhältlich bei

  
DIE FACHBUCHHANDLUNG

Die Online-Fachbuchhandlung [beck-shop.de](http://beck-shop.de) ist spezialisiert auf Fachbücher, insbesondere Recht, Steuern und Wirtschaft. Im Sortiment finden Sie alle Medien (Bücher, Zeitschriften, CDs, eBooks, etc.) aller Verlage. Ergänzt wird das Programm durch Services wie Neuerscheinungsdienst oder Zusammenstellungen von Büchern zu Sonderpreisen. Der Shop führt mehr als 8 Millionen Produkte.

## Chapter 3

# The Normal ECG and its (Normal) Variants

### At a Glance and The Full Picture

This chapter is not divided in two sections because the knowledge of the *normal* ECG and its *normal variants* is as essential for those readers choosing to glance as for those preferring the full picture. This chapter can be used as a dictionary by both types of readers.

When we interpret an ECG we compare it instantaneously with the *normal* ECG and *normal variants* stored in our memory; these memories are stored *visually* in the posterior parts of the cerebrum and *intellectually* in the frontal parts. If these reservoirs contain only question marks, we are as helpless and lost in our interpretation as someone wandering through a snowstorm without a compass. It is important therefore to fill, or reactivate, these reservoirs.

Normal ECG variants will be discussed extensively in this chapter, because their interpretation often leads to a wrong diagnosis. In contrast to pathologic ECG patterns, normal variants can be described as *constant ECG patterns that are neither linked to corresponding typical symptoms, nor to corresponding clinical and anamnestic findings, and not to drugs*.

As early as 1959, Goldman [1] demonstrated that misinterpretation of normal variants can lead to cardiac invalidism. Even today, ill-advised diagnostic and 'therapeutic' interventions may be based on normal variants.

The differential diagnoses of normal variants – the *pathologic conditions* – are presented in brief throughout this chapter.

## 1 Components of the Normal ECG

The *time intervals* of the ECG must be measured and the *whole* ECG must be examined *systematically* and with *caution* in order to avoid mistakes (Chapter 2 Practical Approach). In general, computers measure more precisely than the human eye.

However, computers can generate terrible errors, such as in determining rate – in the presence of high T waves, the computer may indicate double the real rate. For the patterns of *myocardial infarction* and *intraventricular conduction disturbance*, and for many *arrhythmias*, 'computer diagnosis' is unreliable.

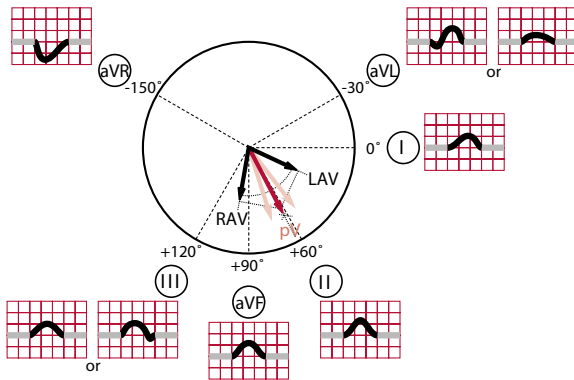
### 1.1 Sinus Rhythm

The sinus node is the normal pacemaker of the heart. *Sinus rhythm* is an obligatory component of the normal ECG. If we diagnose sinus rhythm, we mean that the whole heart (the atria and the ventricles) is depolarized by the electrical stimulus originating in the sinus node and we use the abbreviation SR (ECG 3.1).

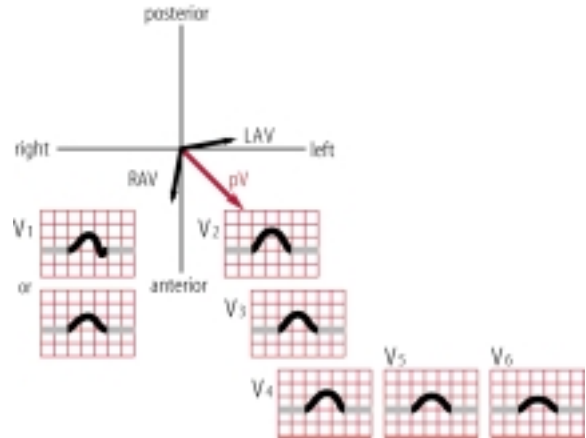
In some special conditions, such as complete atrioventricular (AV) block or in patients with a one-chamber ventricular pacemaker (VVI), the expression sinus 'rhythm' should be restricted to *atrial rhythm* only. A second rhythm that is responsible for the activation of the ventricles must be described separately. For example, ECG 3.2 shows complete AV block; *sinus rhythm of the atria*, rate 102/min; *ventricular escape rhythm*, rate 76/min.

The rate of normal sinus rhythm is 60–100/min (or better 50–90/min) [2]. Sinus rhythm with a rate below 50–60/min is called *sinus bradycardia*; sinus rhythm with a rate above 100/min is called *sinus tachycardia*. Generally, sinus rhythm is not completely regular, especially at lower rates. If the deviation exceeds more than 15% of the basic rate, the term *sinus arrhythmia* is used. In young healthy people the rate variability may exceed 50%.

*Sinus bradycardia* (ECG 3.3) is often seen as a normal variant in individuals at rest, and usually in athletes. Episodes of sinus bradycardia at a rate < 40/min were observed in young



**Figure 3.1a**  
Normal atrial vectors and corresponding p waves in the frontal plane. RAV=right atrial vector; LAV=left atrial vector; pV=p vector.



**Figure 3.1b**  
Normal atrial vectors and corresponding p waves in the horizontal plane. RAV=right atrial vector; LAV=left atrial vector; pV=p vector.

healthy people, in 24% of men and 8% of women; with sinus pauses of up to 2.06 sec in men and 1.92 sec in women [3,4].

Differential diagnosis: Frequent organic disorders are hypothyreosis, cerebral diseases with elevated intracranial pressure, liver diseases, conditions following heart valve operations, and the sick sinus syndrome.

*Sinus tachycardia* (ECG 3.4) is normal during exercise and under conditions of mental stress.

Differential diagnosis: Includes febrile status, heart failure, hyperthyreosis, tumoral diseases, and cachexia.

*Sinus arrhythmia* is almost always normal (ECG 3.5). The rate variation depends on respiration, so that during inspiration the rate increases and during expiration the rate decreases, always with some delay. The rate deviation may reach 50% in children and +/- 15% in middle-aged people; in the elderly the deviation is small or absent.

Differential diagnosis: Atrial premature beats originating near the sinus node. Note: sinus arrhythmia is generally *not* a component of the sick sinus syndrome.

### 1.1.1 Atrial Vectors in Sinus Rhythm

Because the sinus node is situated in the right atrium, the activation of the right atrium begins about 30 msec before the activation of the left atrium. For the diagnosis of sinus rhythm it is not sufficient that after a normal PQ interval, a p wave is followed by a QRS. The activation of the atria by the electric stim-

ulus of the sinus node produces a *typical p vector* in the frontal and horizontal leads. The right atrium vector points inferiorly, anteriorly, and slightly to the right, whereas the left atrial vector points posteriorly, to the left, and slightly downwards (Figures 3.1a and 3.1b). The p vector in sinus rhythm is a *fusion* of the right atrial vector and the left atrial vector. In the limb leads, the fusion vector that corresponds to the p wave, has an axis of +50° to +80°, often about +70°. As a consequence, the p wave is always *positive* in lead I and always *negative* in lead aVR (ECG 3.1). The p wave is mostly positive in II, aVF and III, but may also be biphasic (+/-) in these leads. In lead aVL, the p wave may be biphasic (-/+), positive or negative. If the p vector is not considered, one may mix up sinus rhythm with other atrial rhythms and especially with the most frequent kind of *false poling* (erroneous exchange of the upper limb leads). In this case, as the most striking sign, the p wave is *negative* in I. Of course, the QRS complex and the depolarization are also inverse in this lead (ECG 3.6), whereas the p and QRS configuration in the precordial leads is normal (for other false poling, see Chapter 32 Rare ECGs).

In the horizontal leads, the normal p wave is positive in all leads V<sub>1</sub> to V<sub>6</sub>, with one frequent exception: in lead V<sub>1</sub> the p is often biphasic (+/-), with a first, positive portion and a (smaller) second, negative portion. The latter is due to activation of the left atrium that is placed dorsally in the thorax.

Differential diagnosis: There is no real differential diagnosis of sinus rhythm. Only a (rare) focus near the sinus node cannot be distinguished from one of sinusal origin.

The presence or absence of sinus rhythm of the atria should be examined carefully especially in cases of complete AV block (where only the atria follow a supraventricular rhythm).

### Short Story/Case Report 1

In December 2002 we found ventricular pacemaker rhythm at a rate of 84/min in a 63-year-old woman who had been implanted with a one-chamber (VVIR) pacemaker for treatment of complete AV block with syncope in 1996. Yet the diagnosis of the arrhythmia was incomplete. She did not have sinus rhythm of the atria, but *atrial fibrillation* (ECG 3.7), thus needing additional therapy with an anticoagulation or aspirin. The correct and complete arrhythmia diagnosis is therefore: atrial fibrillation, complete AV block, ventricular pacemaker rhythm at a rate of 84/min.

The *scalar alterations* of the p wave concerning amplitude, form and duration are described in Chapter 4 Atrial Enlargement, and the p wave abnormalities due to *arrhythmias* are described in Chapters 18, 19, 23 and 24.

## 1.2 PQ Interval

The *normal* PQ interval is 0.13–0.20 sec. It is measured from the beginning of the P wave to the beginning of the QRS complex, being a Q wave or an R wave. Lead II is suitable for measuring this because the initial deflections of P and QRS are sharply defined in this lead. In some cases, the beginning of the P and QRS must be determined in another lead, or even in two different leads, registered simultaneously. In healthy individuals a shortened PQ (without a delta wave and without paroxysmal supraventricular tachycardia) is occasionally encountered (ECG 3.8). Also, there are AV blocks in normal individuals: AV block 1° in 8% (male) to 12% (female) [3,4] and intermittent AV block 2° type Wenckebach in 6% (male) to 4% (female) [3,4], especially in athletes, and during the night.

*Early* atrial premature beats may be completely AV blocked in normal individuals, especially in persons with AV block 1°, and during bradycardia.

Differential diagnosis: A PQ interval of more than 0.20 sec is defined as AV block 1°. A PQ interval of less than 0.13 sec associated with paroxysmal supraventricular tachycardias represents the so-called Lown-Ganong-Levine (LGL) syndrome. In the Wolff-Parkinson-White (WPW) syndrome a shortened PQ is linked to a delta wave of the QRS complex.

## 1.3 QRS complex

### 1.3.1 QRS Axis in the Frontal Plane ( $\dot{A}QRS_F$ )

The normal QRS complex is very *variable* in the frontal leads and quite *uniform* in the horizontal leads.

In the *frontal leads* the direction of the QRS vector depends on habitus, body weight, body position, age (especially), and on unknown causes. The frontal QRS axis must be determined in a lying position. Generally, the mean QRS axis undergoes a rotation from right to left during aging. The reason is probably the increasing electric preponderance of the left ventricle compared to the right. Table 3.1 shows the common  $\dot{A}QRS_F$  axis (found in about 70% of normal individuals) in relation to age. ECGs 3.9a–3.9g represent such normal findings. Right-axis deviation or a left-axis deviation (ECG 3.9f shows near left-axis deviation) are very rare in middle-aged patients, and in these cases are often without explanation. Small changes of the QRS axis may be associated with the use of different ECG registration machines. A substantial change of  $\dot{A}QRS_F$  *within a short time* needs further evaluation.

**Table 3.1**  
General behavior of QRS axis in the frontal plane ( $\dot{A}QRS_F$ ) in relation to age

Years	$\dot{A}QRS_F$
0–2	+ 120°
2–10	+ 90°
10–25	+ 70°
25–40	+ 60°
40–70	+ 20°
70–90	– 20°

Differential diagnosis: a shift to the *right* is seen in some cases with pulmonary embolism, in emphysema, and chronic pulmonary hypertension. A shift to the *left* may be associated with inferior infarction or with left anterior fascicular block. The most spectacular alterations of the QRS axis without heart disease are seen in people with thoracic deformation, or after resection of one lung.

An  $S_I/S_{II}/S_{III}$  configuration, generally with R waves greater than the S waves, is not a very rare finding in normal hearts (ECG 3.10) and may be associated with a frontal *sagittal* QRS axis.

Differential diagnosis: This  $S_I/S_{II}/S_{III}$  pattern is rarely seen in right ventricular hypertrophy, or dilatation. In these cases the S wave generally has a greater amplitude than the R wave. Other signs are often also present of right ventricular hypertrophy or right ventricular dilatation, such as a tall R wave in lead  $V_1$ , or a pattern of incomplete or complete right bundle-branch block, and/or negative T waves in  $V_1$  to  $V_3$ .

### 1.3.2 QRS Axis in the Horizontal Plane

The most common pattern in the horizontal leads is shown in ECG 3.1. In leads  $V_1$  and  $V_2$  there is a rS complex with small R waves and deep S waves. In lead  $V_3$  (transition zone from a negative QRS to a positive QRS complex) the R wave is still smaller than the S wave. In lead  $V_4$  the amplitude of the R wave is greater than that of the S wave, sometimes with a small Q wave. In leads  $V_5/V_6$  a qR wave is generally seen, often without an S wave.

In *clockwise rotation* (ECG 3.11) the transition zone from negative to positive QRS is shifted to the *left*. This condition is also called ‘poor R progression in the precordial leads’.

Differential diagnosis: Clockwise rotation may be seen, for example, in the presence of ‘non-Q wave’ anterior myocardial infarction, or in right and/or left ventricular dilatation.

*Counterclockwise rotation* (ECG 3.12) is characterized by a shift of the transition zone to the *right*. It is more common in *young* healthy individuals. In children up to 8 years of age a tall R wave in  $V_1$  is frequent, and it occurs in 20% of children aged 8–12 years, and in 10% aged 12–16 years [5]. An R : S ratio of  $>1$  in lead  $V_2$  is rare in healthy adults (about 1%), whereas a R : S ratio  $>1$  in lead  $V_2$  is found in children in 10% [6].

Differential diagnosis: A prominent notched R wave, at least 0.04 sec broad, in  $V_2/V_3$  ( $V_1$ ) is seen in posterior infarction. An Rs complex in  $V_1$  may be due to right ventricular hypertrophy. A tall R wave with delta wave in leads  $V_1$  to  $V_3$  (to  $V_6$ ) is typical for one type of pre-excitation.

In some cases clockwise or counterclockwise rotation may be caused by erroneous placement of the precordial leads by one intercostal space too low or one space too high, respectively.

### 1.3.3 Two Special QRS Patterns

Two puzzling QRS patterns often provoke diagnostic difficulties (Chapter 14 Differential Diagnosis of Pathologic Q waves).

#### a. $Q_{III}$ Type

The so-called  $Q_{III}$  type corresponds to a QS or QR pattern in lead III, sometimes combined with a significant Q wave, or very occasionally a QS pattern in aVF, and associated with a *positive asymmetric T wave* in most cases (ECGs 3.13a and 3.13b).

The QS or QR pattern in lead III is found in *normal* hearts and in various *pathologic conditions*.

Differential diagnosis: The pathologic conditions are: *inferior infarction*, often associated with a persisting symmetric negative

T wave; or the Q/QS wave is followed by a positive T wave, perhaps due to mirror image in *systolic overload* or *left ventricular hypertrophy*, to *pre-excitation* (with a negative delta wave) or *left bundle-branch block* (broad QRS and typical pattern in the other leads). In later stages of inferior myocardial infarction the T wave may also be positive in the inferior leads.

#### b. $QS_{V1/V2}$ Type

A QS pattern in leads  $V_1$  and/or  $V_2$  (ECG 3.14), found in healthy hearts, is a normal variant, or is due to misplacement of leads by one intercostal space (ICS) too high. In young people, there may be a negative T wave also in  $V_2$ , mimicking a small anteroseptal infarction with ischemia. In other cases we find a QS type only in  $V_2$ . The explanation is that on the thoracic wall, the lead  $V_2$  is positioned superiorly compared with a line between  $V_1$  and  $V_3$ , thus suppressing the initial R wave. The disappearance of QS and the appearance of an rS complex, respectively, after moving lead  $V_2$  (and  $V_1$ ) one ICS higher, is not a reliable criterion for absent infarction.

Differential diagnosis: An additional Q wave in lead  $V_3$ , or a QRS notching in more than two precordial leads, combined to a negative T wave in lead  $V_3$ , favors the diagnosis of old anteroseptal myocardial infarction.

The correct diagnosis in  $Q/QS_{III}$  and  $QS_{V1/V2}$  is made not only by morphologic ECG criteria, but also by anamnestic and clinical findings. In cases of doubt, further examinations are necessary.

### 1.3.4 Other Normal Variants of the QRS Complex

#### a. Notching Versus Pseudo-Notching

Notching or a ‘notch’ is defined as a small (about 1–2 mm high) additional deflection with inverse polarity, within the Q, R, or S wave of the QRS complex (Figure 3.2a). In this book we do not distinguish between *notching* and *slurring* [that is defined

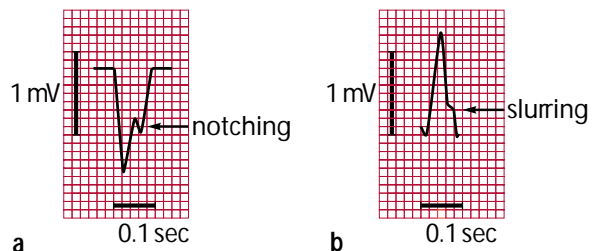


Figure 3.2  
a. Notching of QRS. b. Slurring of QRS.

as ‘slight’ notching, without change of polarity (Figure 3.2b)]. Notching and slurring correspond either to a *localized disturbance (delay)* of conduction and excitation, or merely may be due to *projections* (known as *pseudo-notching*). In practice it is important to distinguish between *true* intraventricular conduction disturbance (notching) and a *harmless* functional alteration, based only on vectorial projection (pseudo-notching).

Differentiation between notching and pseudo-notching may be difficult. Slight pseudo-notching is frequently seen in the inferior leads III, aVF and II (ECGs 3.15a and 3.15b) and occasionally in lead aVL. A pseudo-notching in lead I is rare.

Differential diagnosis: Left posterior fascicular block: Often ‘slurred R downstroke’ in leads III, aVF and  $V_6$ . Left anterior fascicular block (always with left-axis deviation): Often ‘slurred R downstroke’ in leads I and aVL. Notching in the limb leads may also be seen in old myocardial infarction, with or without pathologic Q waves.

A pseudo-notching may also be present in the *transition zone* of the precordial leads, mostly in only one lead, and predominantly in  $V_3$  (ECG 3.16a and 3.16b). Again, this is due to projection. The QRS complex cannot decide whether it should be negative or positive. ECG 3.16c shows notching in leads  $V_3$  and III.

Differential diagnosis: In cases of notching in three or more precordial leads, an intraventricular conduction disturbance is probable, often due to an infarction scar (Chapter 13 Myocardial Infarction).

#### b. Pseudo-Delta Wave

Projections may also be associated with a positive *pseudo-delta wave* in leads III, aVF (II) and in leads  $V_2$  and/or  $V_3$  (ECGs 3.17a and 3.17b). Occurrence of a pseudo-delta wave in  $V_2/V_3$  can be explained: the septal vector is (as normal) positive in these leads, but there is also a positive projection of the following 20–30 msec of the QRS complex, on leads  $V_2$  and  $V_3$ . This pattern is often misinterpreted as (‘abortive’) pre-excitation. However, the PQ interval is *normal*. In highly doubtful cases, it is advisable to repeat the ECG or to perform a test with ajmaline. In pseudo-pre-excitation the delta wave persists, in true pre-excitation it should disappear.

#### c. QRS Low Voltage

A QRS voltage of less than 5 mm (0.5 mV) in up to three of the six frontal leads is not a rare finding. True *peripheral* low voltage is present if the QRS complex is smaller than 5 mm in five out of six or all six limb leads (ECG 3.18), a rare finding in normal individuals.

Differential diagnosis: True peripheral low voltage in pathologic conditions is found in lung emphysema, obese people, and rarely in patients with extensive pericardial effusion. Peripheral low voltage has little clinical importance. The same is valuable for the very rare *horizontal* low voltage defined as QRS voltage smaller than 7 mm in all precordial leads. A significant decrease of QRS voltage has been described after therapy with (overdosed) adriablastine.

#### d. Incomplete Right Bundle-Branch Block (iRBBB)

An iRBBB ( $rSr'$  in lead  $V_1$ ) is a frequent finding in healthy people, especially in young people. This pattern may lead to a notching or  $rSr'$  complex in lead III also. If  $r > r'$  (ECG 3.19a) a normal variant is probable. A notched S upstroke in  $V_1$  often corresponds to iRBBB. In this case, there is a terminal R wave in lead aVR, as in common patterns of iRBBB. In addition, the QRS configuration with  $r < r'$  (ECG 3.19b) represents a normal variant in many cases. However, we have to exclude diseases of the right ventricle.

Differential diagnosis: iRBBB with  $r' > r$  is encountered in right ventricular systolic overload (as in pulmonary *embolism* and any disease with *pulmonary hypertension*, and/or *right ventricular hypertrophy*), in RV diastolic overload (as in *atrial septal defect*) or may represent a *precursor* of complete RBBB. iRBBB with  $r > r'$  is a rarer finding in these pathologic conditions. A new onset iRBBB may be a sign of acute right ventricular overload, or it can appear after different placing of lead  $V_1$  – in which case it may be harmless.

## 1.4 ST Segment

For some physicians, an ST elevation of  $\geq 2$  mm in any ECG lead automatically means *acute ischemia*. This opinion needs to be revised: there is *one very common* normal ECG pattern with ST elevation, and *one very rare* normal variant.

### 1.4.1 Common Pattern of ST elevation: ST elevation in $V_2/V_3$

In about 70% of normal ECGs the so-called *junction (J) point* (the point that defines the end of the QRS complex and the beginning of the ST segment) is 0.5–1.5 mm above the isoelectric line in lead  $V_2$  and often  $V_3$ , and consequently there is *elevation* of the ST segment (measured at rest 0.08 sec after the J point). Especially in *sinus bradycardia* the J point, and thus the ST segment, may be elevated up to 2–3 mm (ECG 3.20a), and rarely up to 4 mm. Vagal stimulation enhances the discordance of repolarization in the anteroseptal leads, and this phenomenon is magnified by the ‘proximity effect’. The latter effect explains also the relative high amplitude of the S and

T waves in leads  $V_2$  and  $V_3$ . This common pattern of repolarization *should not* be misinterpreted as acute ischemia.

## Short Story/Case Report 2

A 38-year-old man with acute pain on the left side of the thorax was seen at the emergency station. He mentioned subfebrile body temperatures over the previous few days. The only risk factor for coronary heart disease (CHD) was that one of his uncles had a myocardial infarction at the age of 50 years. Blood pressure was 150/90 mmHg. The ECG showed sinus bradycardia with ST elevation of 2 mm in leads  $V_2$  and  $V_3$  (ECG 3.20b). Creatine kinase (CK) was slightly elevated (by 20%), and myocardial fraction of CK and troponin were normal. There was leukocytosis of  $11 \times 10^9/l$ . The diagnosis of acute anterior infarction was made and thrombolysis performed. The ECG remained unchanged. The pain disappeared after the first dose of morphine and blood pressure normalized. One day later the diagnosis was revised and an infectious disease of unclear origin with pain of chest skeletal muscle presumed. The patient insisted on a coronary angiography. The coronary arteries were normal. A day later the patient was dismissed without symptoms and with aspirin 500 mg for 7 days. On the basis of positive titers of coxsackievirus, the final diagnosis of coxsackievirus infection (Bornholm disease) was made. In conclusion, the chest pain was atypical and the ECG was normal. The slightly elevated CK was overestimated. It would have been better to observe the patient for some hours and to control the ECG and the enzymes.

### 1.4.2 Rare Pattern of ST Elevation: Early Repolarization

'Early repolarization' is characterized by a *marked, constant* elevation of the J point and the ST segment of 2–4 mm, emerging directly from the R wave downstroke, in the *anterior* precordial leads (accentuated more septally or more laterally) and/or the *inferior* leads III and aVF. It occurs more frequently in males than in females, but no less in white than black people [7]. The pattern is very similar – even the same – as that of *acute infarction* or *Prinzmetal angina*. In these conditions the ST elevation varies within a short time and is mostly associated with chest pain. The correct diagnosis is based on anamnestic and clinical findings.

The ECGs presented in ECGs 3.21a–3.21d show examples of early repolarization in normal individuals, with an ST elevation of 2–3 mm in some leads.

Differential diagnosis: The most important differential diagnosis of ST elevation, arising from the R wave, is acute myocardial infarction and, rarely, vasospastic angina. Hypercalcemia may provoke a slight ST elevation of this type. ST elevations, generally arising from the S wave, are seen in acute pericarditis and as a mirror image of 'systolic left ventricular overload'.

If slight elevations of the ST segment in otherwise normal ECGs are included, early repolarization is not that rare. For differentiation between early repolarization and acute pericarditis see the paper by Spodick [8].

In some cases, an *Osborn wave* – a very short and small positive deflection within the ST segment (ECG 3.20a) – is seen in addition to the ST elevation [9]. In rare normal ECGs, without early repolarization, a *minimal* Osborn wave may be present in the inferior leads or in  $V_5/V_6$  (ECG 3.22).

Differential diagnosis: An Osborn wave is regularly seen in hypothermia (ECGs 3.23a–3.23d) and sometimes in cases of acute pericarditis. For details, see Chapter 17 Special Waves And Phenomena.

## 1.5 T Wave and U Wave

### 1.5.1 T Wave

Besides the QRS complex (great variability of the axis in the frontal leads), the T wave is the most variable component of the ECG. There are some rules about normal T waves, however.

A normal T wave is *asymmetric*, with a slow upstroke and a more rapid downstroke.

In respect to polarity, T is positive in most leads and negative in some leads. In the *frontal leads* the T wave is positive in I and often positive in aVL, II, aVF, and III. The T wave is often negative in lead III (and aVF, occasionally also in II), independent of the frontal QRS axis (ECGs 3.24a and 3.24b). In a QRS axis of  $0^\circ$  or less, the T wave may be negative also in aVL, but *never* in lead I.

In the *horizontal leads* the T wave is negative or positive (or isoelectric) in  $V_1$  and positive in  $V_2$  to  $V_6$ . In rare cases there is a negative T wave in  $V_2$  (and  $V_3$ ), especially in young women (up to the age of 30 years). A negative T wave in any of the other precordial leads is very rare and should be interpreted as a normal variant only after exclusion of any pathology.

Differential diagnosis: T wave alterations alone, not with QRS abnormalities, have to be considered as *unspecific*. The reasons for pathologic T waves are manifold, but some general rules apply:

1. Coronary heart disease (CHD) is the most common origin of *symmetric* and *negative* T waves, so-called 'coronary' T waves

(ECG 3.24c). However, this type of T wave occurs in other conditions too, such as pericarditis, or severe anemia.

2. *Asymmetric, negative* T waves are generally associated with ventricular overload. In *left* ventricular overload we find discordant negative T waves in I, aVL, V<sub>6</sub> and V<sub>3</sub> (ECG 3.24d). It must be mentioned that often the distinction between left ventricular overload and coronary origin is impossible based on the morphology of the T wave. Furthermore, the combination of these two conditions is not rare. In *right* ventricular overload the T waves may be negative (concordant) in V<sub>2</sub> and V<sub>3</sub>, T negativity in V<sub>1</sub> to V<sub>3</sub> is also found in cases of 'arrhythmogenic right ventricular dysplasia' and in funnel chest.

Tall, positive and even *symmetric* T waves may be seen in the precordial leads, especially in V<sub>2</sub> and V<sub>3</sub> (and V<sub>4</sub>), often in younger people and associated with sinus bradycardia (ECGs 3.20a and 3.20b).

Differential diagnosis: Hyperkalemia. Very rare transitory sign of peracute ischemia.

### 1.5.2 U Wave

The U wave is a positive flat deflection after the T wave, visible best in leads V<sub>3</sub> and V<sub>6</sub>. It is thought that the U wave represents the repolarization of the Purkinje fibers. The absence of the U wave is not rare and has no clinical significance.

Differential diagnosis: on one hand, negative U waves have been found (e.g. in acute ischemia or severe aortic valve incompetence) and even alternating U waves have been described. On the other hand, two conditions, not compromising the U wave alone, should be mentioned:

- i. The fusion of the T wave with the U wave, leading to a *TU wave*, is typical for *hypokalemia*.
- ii. In the 'long QT syndromes' (see following section QT Interval) there is often a fusion of the T wave and the U wave. In fact, in many cases with this syndrome we do not know what we are measuring, whether it is the QT interval or the QTU interval.

## 1.6 QT Interval

The QT interval is measured from the beginning of the QRS complex to the end of the T wave, generally in lead II, where the end of the T wave is sharply determined in most ECGs. The QT time is rate dependent. The lower the rate, the longer the QT is, and the higher the rate, the shorter the QT. The time-corrected QT interval is called QTc. Today most ECG machines measure the QT interval automatically, the time-corrected QT (QTc) included. The QT interval and the QTc may also be calculated 'by hand', using the Bazett formula:

$$\left( \text{QTc} = \frac{\text{QT}}{\sqrt{60/f}} \text{ resp. } \frac{\text{QT}}{\sqrt{\text{R}-\text{R}}} \right)$$

Slightly shortened or slightly prolonged QT intervals are sometimes encountered in normal hearts. The QTc should *not* exceed 0.46 sec, however.

Differential diagnosis: A substantially prolonged QT interval is called long QT syndrome. The *acquired* type is more frequent and is generally due to drugs, to antiarrhythmic drugs of Class Ia or Class III (Vaughan-Williams), and due to ischemia. The *congenital* long QT syndrome (Romano-Ward syndrome, Jervell-Lange-Nielsen syndrome) is a rare condition. A pronounced prolongation of QT or QTU tends to a special form of fast polymorphic ventricular tachycardia, called torsade de pointes (for details see Chapter 26 Ventricular Tachycardias).

Some electrolyte disturbances influence the QT interval in a typical manner: A prolonged QT is also seen in *hypocalcemia* (in this case without disposition to torsade de pointes). A *TU fusion* is typical for *hypokalemia*, with possible consecutive torsade de pointes. A markedly shortened QT is very rare and is generally associated with *hypercalcemia* (Chapter 16 Electrolyte Imbalance).

## 1.7 Arrhythmias

It is quite difficult to classify certain arrhythmias into those that are *normal variants*, and those that are *pathologic* findings. We know, for example, that episodes of *ventricular tachycardia* (VT) [10] or a *slow ventricular escape rhythm* may be found in apparently healthy individuals, especially in athletes. However, a VT or a ventricular rhythm of 30/min would not be classified as a normal finding. Both examples represent common and clinically important and often dangerous arrhythmias, that may rarely arise in healthy individuals under special conditions, and in these cases they are (probably) harmless.

However, there are a substantial number of arrhythmias that occur so frequently in individuals without heart disease that they *may* represent normal variants. Three conditions must normally be fulfilled:

- i. Absence of any heart disease.
- ii. Exclusion of many arrhythmias, *not* representing normal variants (Table 3.2).
- iii. A 'normal-variant arrhythmia' should occur only rarely and should not be associated with very low or very high rates. However, a healthy individual may *feel* a normal-variant arrhythmia.

Table 3.3 reveals the arrhythmias that often represent *normal variants*. The number of normal *supraventricular* PBs, espe-



**Table 3.2****Arrhythmias, *not* representing 'normal variants'**

Complete AV block
AV block 2°, type Mobitz and type 'high degree'
Sinoatrial (SA) block 2° and 3°
Ventricular pauses of > 2 sec
Monomorphic ventricular tachycardia (VT: > three ventricular beats)
Polymorphic VT (torsade de pointes; other forms)
Ventricular triplets (three consecutive ventricular premature beats (VPBs)), multiple couplets
Multiple ventricular 'couplets'
Single ventricular VPBs if:
a. >200/24 h?
b. polymorphic
c. with true R-on-T phenomenon (ventricular PB <i>before</i> 90% of the preceding T wave: potential 'vulnerable period')
Most forms of atrial tachycardias (e.g. atrial flutter, atrial fibrillation, re-entrant atrioventricular (AV) tachycardias, re-entry tachycardias in the Wolff-Parkinson-White syndrome)
Supraventricular PBs in salvos (> 3 beats) and at a high rate (> 160/min)
Rare arrhythmias (e.g. parasystole, accelerated idioventricular rhythm, AV dissociation with interference)
Ventricular fibrillation (of course)

cially of normal *ventricular* PBs, is as arbitrary as it is questionable.

As mentioned above, there is no strict dividing line between pathologic arrhythmias and normal-variant arrhythmias, and there is no consent in the literature. The classification in Table 3.3 is based on 40 years of personal experience and on many discussions with other specialists in cardiology and rhythmology.

Principally, an arrhythmia should always be interpreted in the context of other clinical findings, considering also age and special conditions of a patient, including exercise capacity, psychological factors and drug abuse (ethyl, nicotine, medical drugs). Generally, 'normal-variant arrhythmias' should not be treated with antiarrhythmic drugs.

**Table 3.3****Frequent normal-variant arrhythmias**

Sinus bradycardia: minimal rate about 45/min; minimal instantaneous rate during sleep about 35/min
Sinus tachycardia: maximal rate about 110/min
Sinus arrhythmia
Isolated ventricular pauses: < 2 sec during sleep
Isolated AV-junctional (AV-nodal) escape beats (during sinus arrhythmia or after a premature beat)
Short episodes of AV-nodal rhythm (with retrograde atrial activation)
Short episodes (< 10 beats?) of 'AV dissociation' (with accrochage, with synchronization)
Short episodes of accelerated idionodal rhythm
Episodes of normocardic ectopic atrial rhythm (e.g. so-called 'coronary sinus rhythm')
Supraventricular premature beats (PBs) (in most cases atrial PBs), if:
a) isolated (< 200/min?)
b) < 5 salvos (or < 20?) of maximal three beats
c) instantaneous rate (beat-to-beat interval) < 160/min
d) isolated <i>early</i> atrial PBs with functional complete AV block
Ventricular PBs (VPBs), if:
a) isolated (< 200/24 h?)
b) monomorphic
c) isolated 'couplets' (< 20/24 h?), instantaneous rate < 160/min
d) isolated VPBs with 'pseudo-R-on-T phenomenon' (VPB <i>after</i> 90% of the preceding QT interval: 'supernormal period')

## 1.8 Day-to-Day and Circadian Variation

Day-to-day variation concerns the amplitude and axis of the QRS complex and variations of the T wave in particular. Willems et al [11] studied 20 healthy volunteers (7 women and 13 men aged 22–58 years; a total of 290 tracings) with the Frank leads ECG and vectorcardiogram. Several cases had marked changes of the frontal QRS axis, also with disappearance and reappearance of (small) Q waves. In one individual the anterior QRS forces in the transversal and sagittal planes disappeared. The authors believe *that such extreme changes occurring in normal subjects may be unusual, but should serve as a warning for too enthusiastic diagnostic and therapeutic interventions*. T wave changes were fairly common. Some variations could also be observed in tracings, recorded immediately one after the other ('circadian variation').

We have observed a young healthy individual with unexplainable T negativity in leads V<sub>3</sub> to V<sub>5</sub>. Serial ECGs (two taken

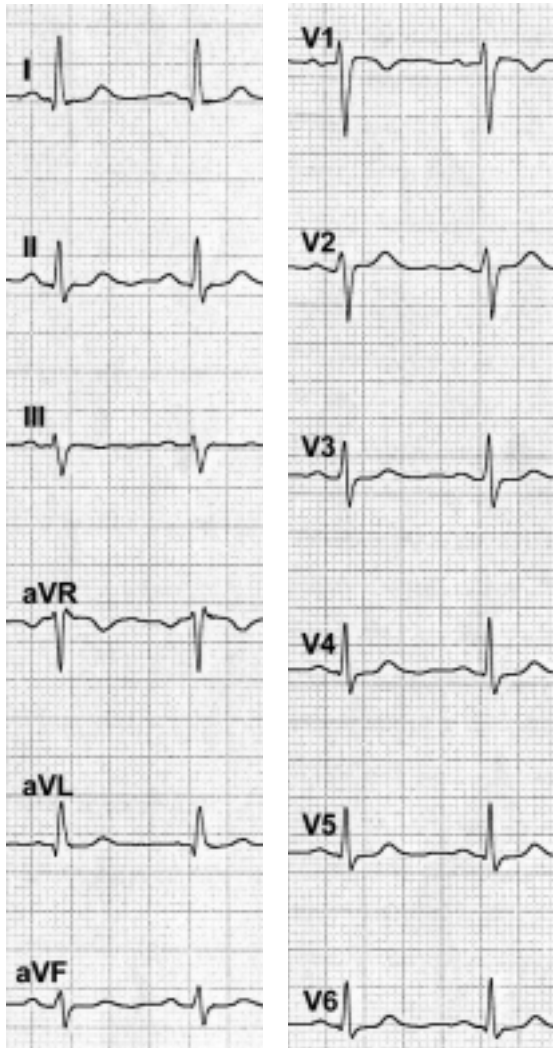
during the night) revealed that T negativity was only present between 11 A.M. and about 6 P.M.

## General Conclusion

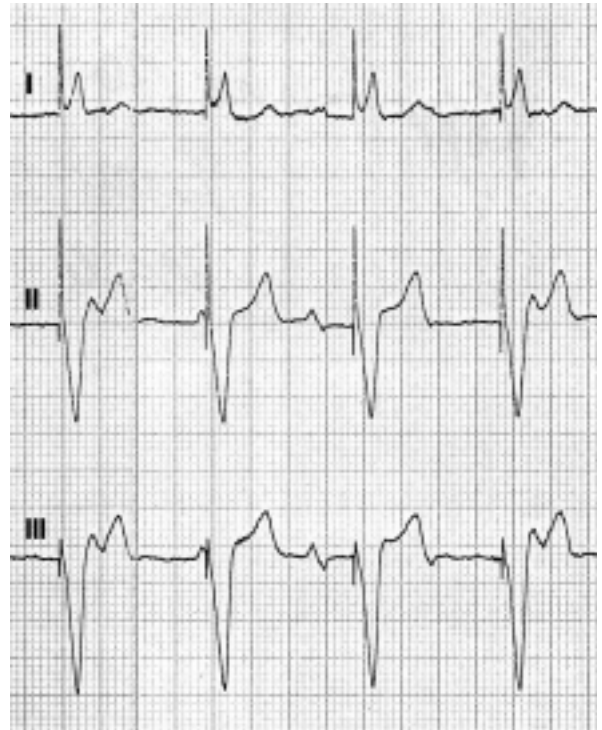
As mentioned at the beginning of this chapter, every ‘unusual’ ECG pattern should be interpreted in the context of the conditions of the person being investigated, including age, anamnesis, and other clinical findings and quality of symptoms.

## References

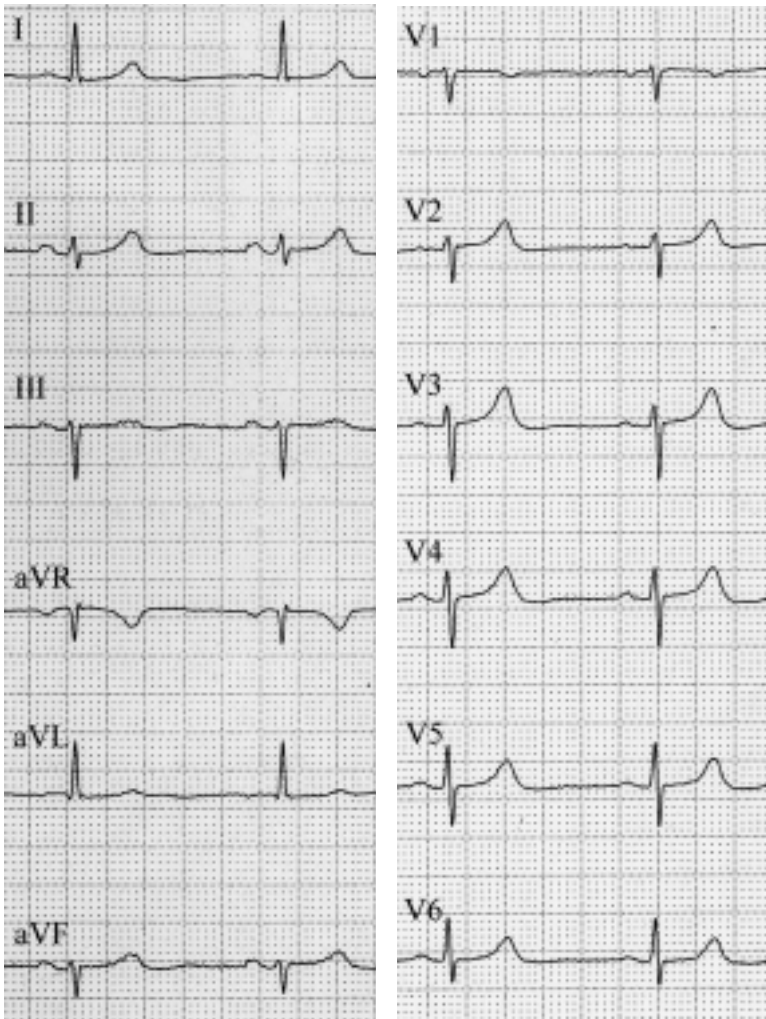
1. Goldman MF. Normal variants in the electrocardiogram leading to cardiac invalidism. *Am Heart J* 1959;59:71–7
2. Spodick DH. Normal sinus heart rate: Sinus tachycardia and sinus bradycardia redefined. *Am Heart J* 1992;124:1119–21
3. Brodsky M, Wu D, Denes P, et al. Arrhythmias documented by 24-hour continuous electrocardiographic monitoring in 50 male medical students without apparent heart disease. *Am J Cardiol* 1977;39:390–5
4. Sobotka PA, Mayer JH, Bauernfeind RA, et al. Arrhythmias documented by 24-hour continuous ambulatory electrocardiographic monitoring in young women without apparent heart disease. *Am Heart J* 1981;101:753–9
5. James FW, Kaplan S. The normal electrocardiogram in the infant and child. *Cardiovasc Clin* 1973;5:294–311
6. Hiss RG, Lamb LE, Allen M. Electrocardiographic findings in 67 375 asymptomatic subjects: X. Normal values. *Am J Cardiol* 1960;6:200
7. Mehta M, Abnash CJ, Mehta A. Early repolarization. *Clin Cardiol* 1999;22:59–65
8. Spodick DH. Differential characteristics of the electrocardiogram in early repolarization and acute pericarditis. *N Engl J Med* 1976;295:523–7
9. Patel A, Getsos JP, Moussa G, Damato AN. The Osborn wave of hypothermia in normothermic patients. *Clin Cardiol* 1994;17:273–6
10. Bjerregaard P. Premature beats in healthy subjects 40–79 years of age. *Europ Heart J* 1982;3:493–503
11. Willems JL, Pobleto PF, Pipberger HV. Day-to-day variation of the normal orthogonal electrocardiogram and vectorcardiogram. *Circulation* 1972;45:1057–64



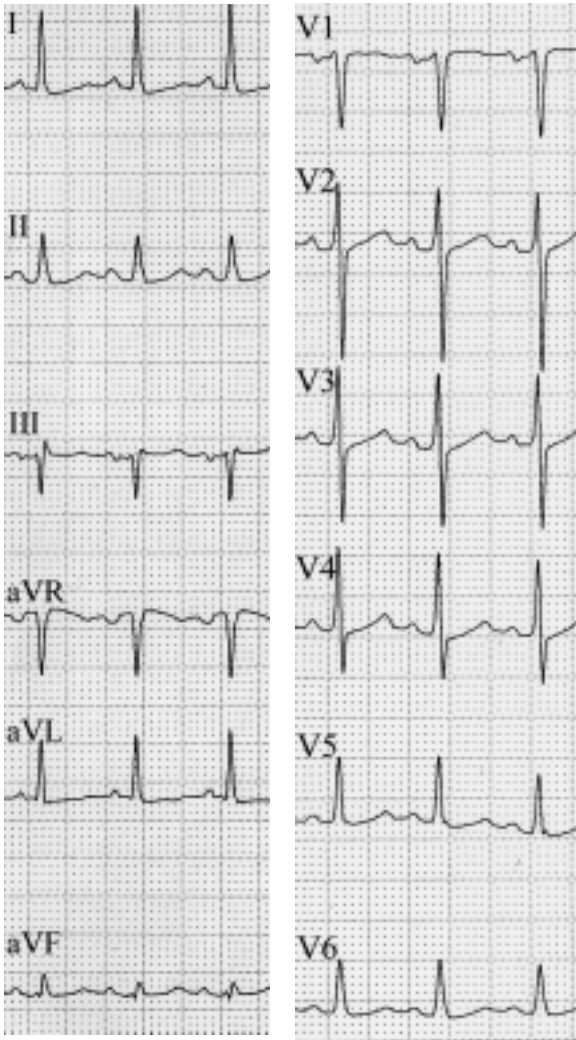
ECG 3.1  
Sinus rhythm (81/min).



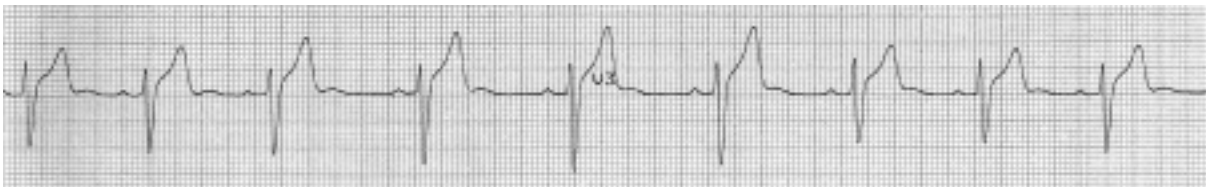
ECG 3.2  
Sinus rhythm of the atria; ventricular pacemaker rhythm (complete AV block).



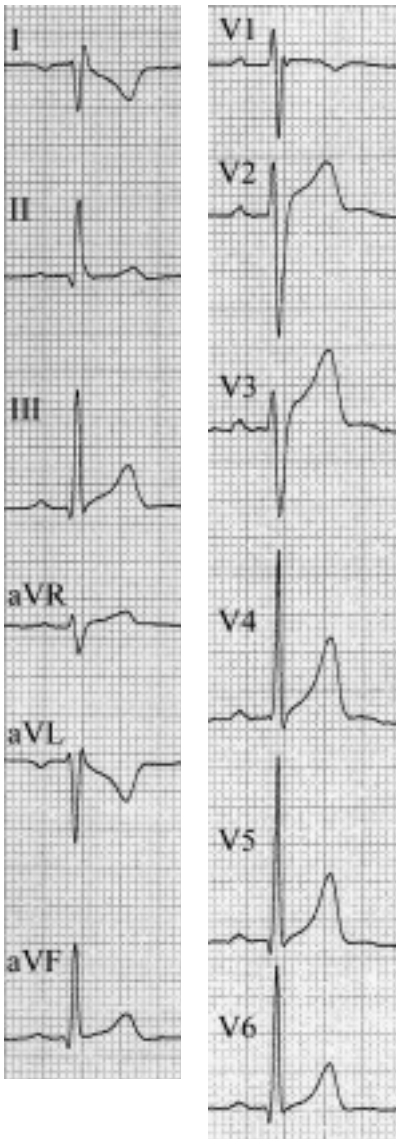
**ECG 3.3**  
Sinus bradycardia, 49/min.



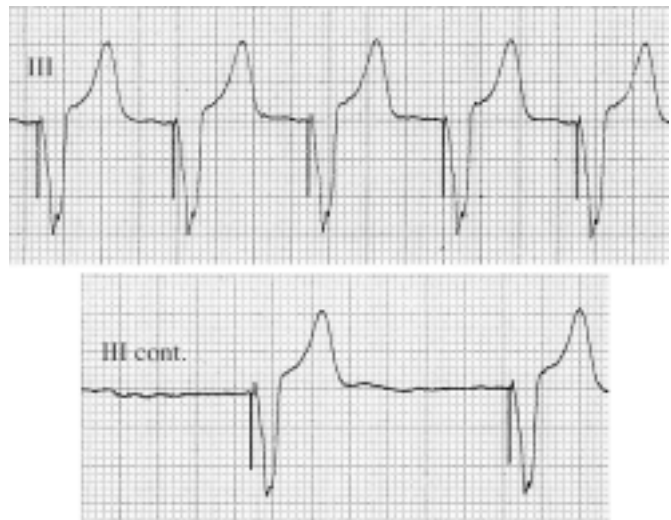
**ECG 3.4**  
Sinus tachycardia, 122/min.



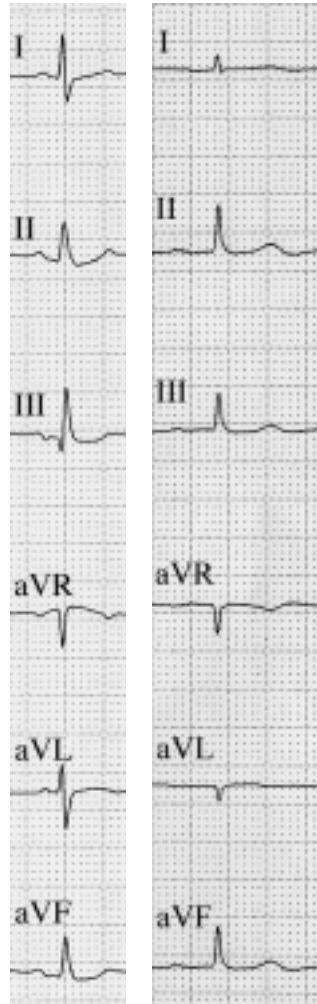
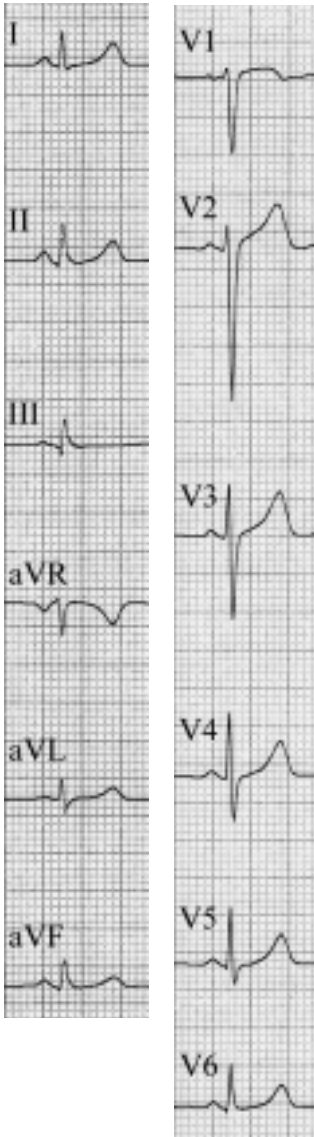
**ECG 3.5**  
Sinus arrhythmia (minimal rate 42/min, maximal rate 67/min).



**ECG 3.6**  
False poling of the upper limb leads.

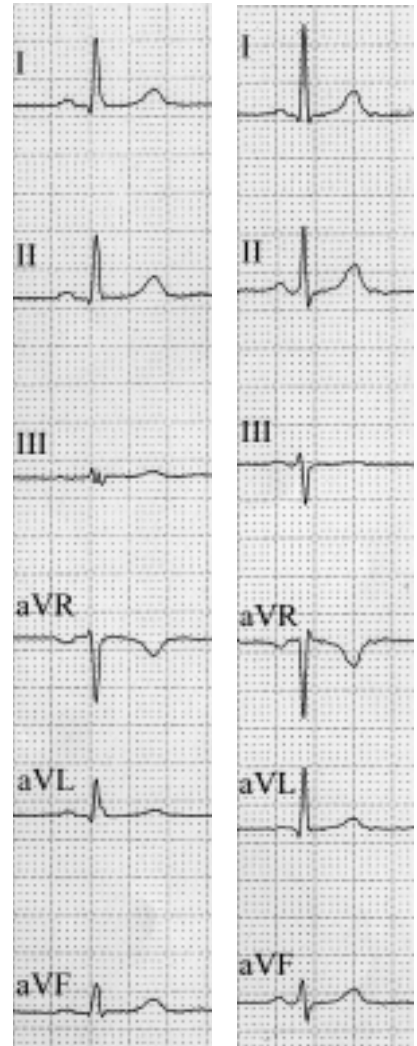


**ECG 3.7**  
Ventricular pacemaker rhythm at a rate of 85/min. The U waves were misdiagnosed as p waves. Pacing at 44/min reveals fine f (fibrillation) waves.



a

b



c

d

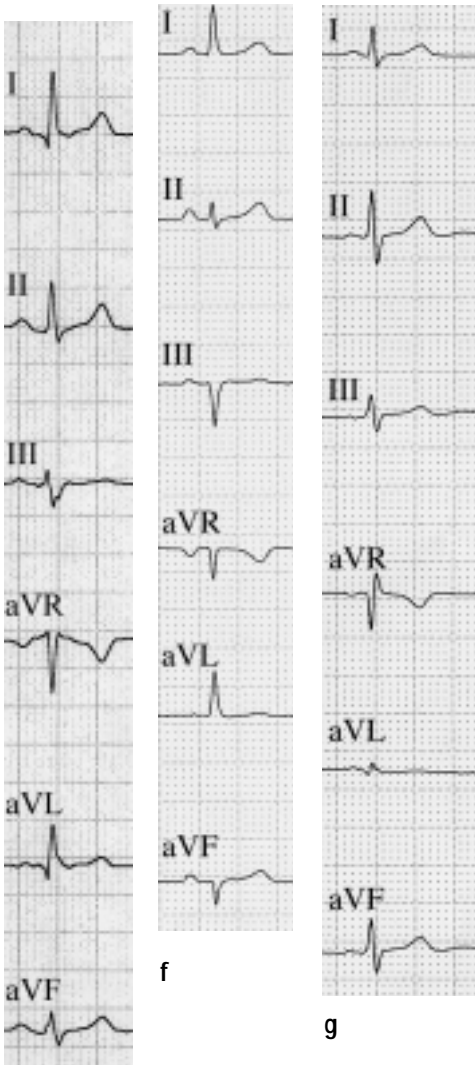
**ECGs 3.9a–3.9d**

**Different  $\hat{A}QRS_F$ .**

- a. 18y.  $\hat{A}QRS_F + 80^\circ$ .
- b. 25y.  $\hat{A}QRS_F + 75^\circ$ .
- c. 40y.  $\hat{A}QRS_F + 30^\circ$ .
- d. 54y.  $\hat{A}QRS_F + 20^\circ$ .

**ECG 3.8**

Short PQ interval, normal ECG, no episodes of tachycardia.



e

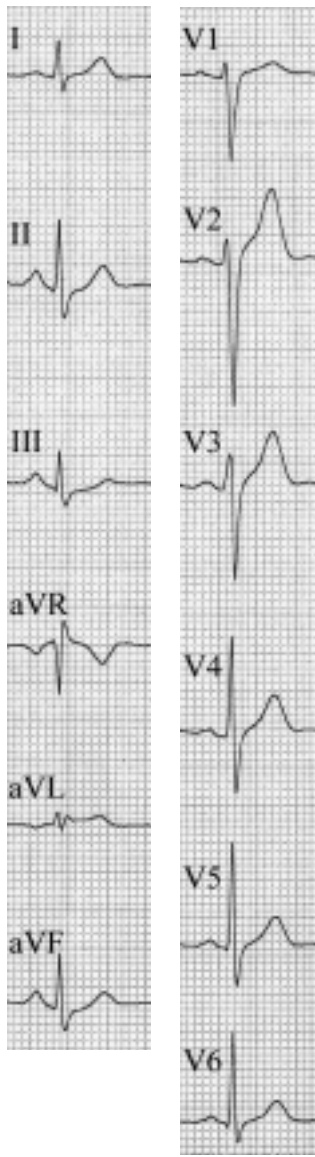
**ECGs 3.9e–3.9g**

Different  $\dot{A}QRS_F$ .

e. 60y.  $\dot{A}QRS_F$   $0^\circ$ .


f. 73y.  $\dot{A}QRS_F$   $-20^\circ$ .

g. 25y.  $\dot{A}QRS_F$  not determinable. The positive and negative components of the QRS complex have almost the same amplitude in the individual limb leads. This frontal QRS axis is called *sagittal axis*.



**ECG 3.10**

$S_I/S_{II}/S_{III}$ -type.



**ECG 3.11**

Clockwise rotation of QRS.