

Chapter 2

Elbow

LISTEN

Mechanism of Injury (If Applicable)

Patient usually remembers their position at the time of injury
Certain mechanisms of injury result in characteristic patterns

Fall on outstretched hand → supracondylar fracture
→ posterior dislocation
→ radial head fracture

Direct blow to elbow → olecranon fracture

Fall on to flexed elbow → supracondylar fracture
→ anterior dislocation
→ capitellar fracture

A child being lifted by arms → subluxation of radial head

Pain

Site of Pain

Localized pain (to which the patient can point with a finger)

Medial epicondyle → medial epicondylitis (golfer's elbow)
→ cubital tunnel syndrome
→ ulnar collateral ligament injuries

Lateral epicondyle → lateral epicondylitis (tennis elbow)
→ radial tunnel syndrome
→ osteochondritis of capitellum

Generalized pain → osteoarthritis and other inflammatory arthropathy
→ gout
→ infection
→ tumors

Type of Pain

Aching pain → degenerative changes

Sharp pain/ catching pain → loose body

Pain after activity → inflammatory arthropathy
→ tendinosis

Radiation of Pain

Conditions involving the lateral compartment (radiocapitellar joint) provoke pain that extends over the lateral aspect of the elbow, with radiation proximally to the midhumerus and distally over the forearm.

Stiffness

Rest stiffness/early morning stiffness → rheumatoid arthritis
→ inflammatory arthropathy
→ osteoarthritis

Swelling

Spontaneous → rheumatoid arthritis
→ bursitis
→ septic arthritis

Localized posterior → rheumatoid nodules
→ olecranon bursa
→ gouty tophi

Neurological Symptoms

Altered sensation
Weakness/Atrophy

LOOK**With the Arms by the Side (Elbow in Extension)**

Scars, skin grafts, sinuses, erythema

Carrying angle: Normal valgus angulation of the elbow. Ask the patient to stand with the arms by their side with the elbows extended and forearms supinated. The angle formed between the longitudinal axis of the arm and the forearm is the carrying angle. (Figure 2.1)

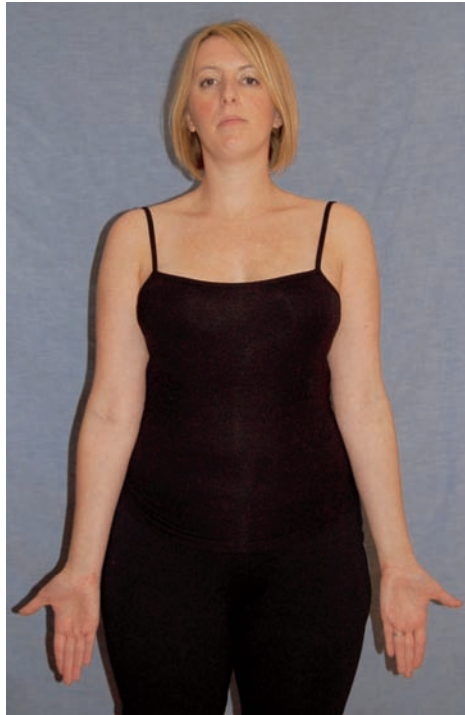

FIGURE 2.1. Carrying angle.

Normal average:

Men → 10°

Women → 13°

Increased carrying angle (cubitus valgus) → nonunion lateral condyle fracture
→ premature closure of lateral epiphysis

Decreased carrying angle (cubitus varus) → malunited supracondylar fractures
→ premature closure of medial epiphysis

With the Elbow in Flexion

Scars, sinuses, erythema

Swellings in the posterior aspect of the elbow are easily seen.

Causes → effusions

→ rheumatoid nodules

→ olecranon bursa

FEEL

Increased skin temperature → septic arthritis

→ bursitis

→ acute attack of gout

Lateral Side

Lateral Epicondyle

Visible landmark in most patients.

Flexion of the elbow to 90° helps identification in obese patients.

Radial head:

With the patient's elbow flexed to 90°, the examiner first palpates the lateral epicondyle with his thumb. The radial head is 2 cm distal to the lateral epicondyle. Pronation and supination of the patient's forearm facilitate the palpation of the radial head (Figure 2.2).

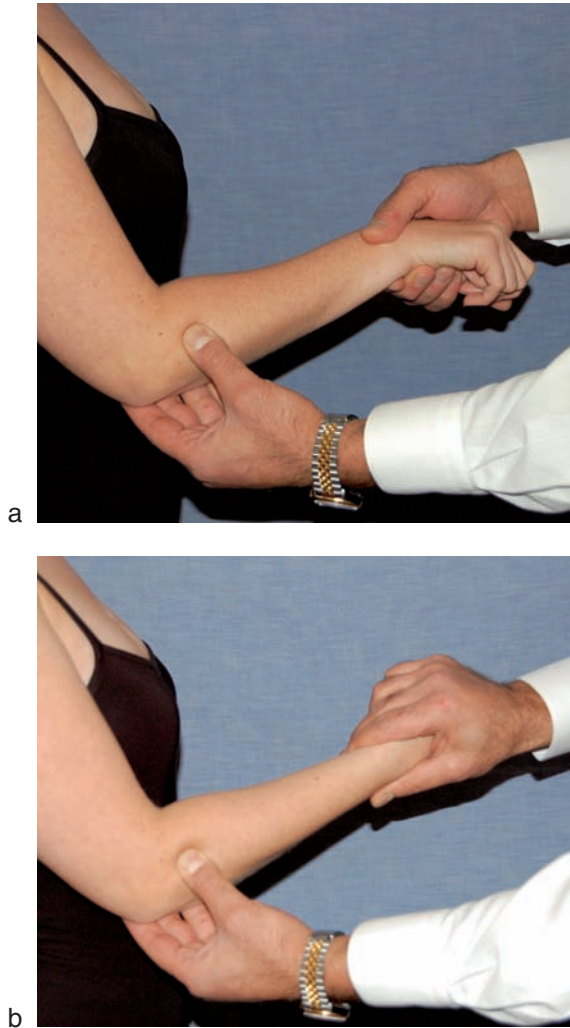


FIGURE 2.2. (a) Palpation of the radial head. Forearm pronated. (b) Palpation of the radial head. Forearm supinated.

If painful → Radial head fracture
→ Radiohumeral arthritis

Posterior Interosseous Nerve

Four finger breadths distal to lateral epicondyle (Figure 2.3), the posterior interosseous nerve passes between two heads of supinator under a thick ligament called *arcade of Frohse*. Entrapment of the nerve at this site is known as radial tunnel syndrome.

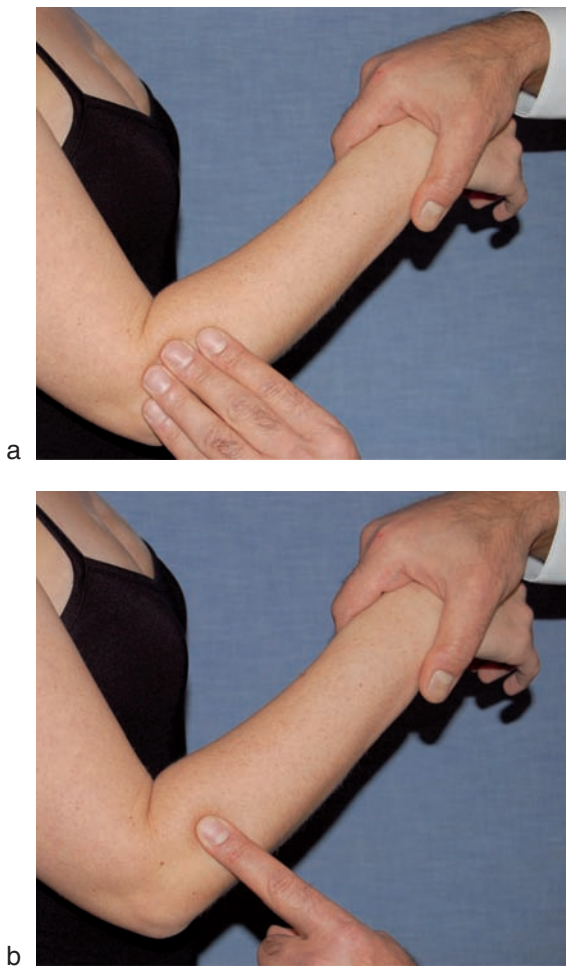


FIGURE 2.3. (a) Posterior interosseous nerve. (b) The index finger is over the *arcade of Frohse*.

From Behind**Tip of the Olecranon**

The tip of the olecranon and the olecranon fossa are palpated for tenderness.

The bony prominences of the lateral epicondyle, the radial head and the olecranon form a triangle (Figure 2.4). The center of this triangle is the radiohumeral joint capsule . Careful palpation may reveal minor effusions or low grade synovitis.

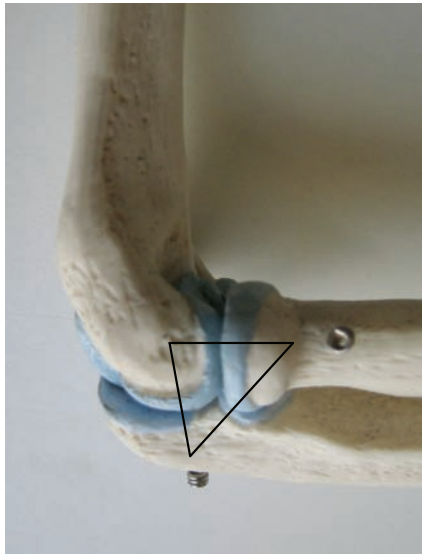


FIGURE 2.4. Relationship of the three bony points.

Medial Side

Medial Epicondyle

The most prominent structure of the medial side of the elbow is the medial epicondyle. The ulnar nerve can be felt behind the medial epicondyle (Figure 2.5). To facilitate palpation, the patient's arm should be in slight abduction, external rotation, and the elbow flexed between 20 and 70°.

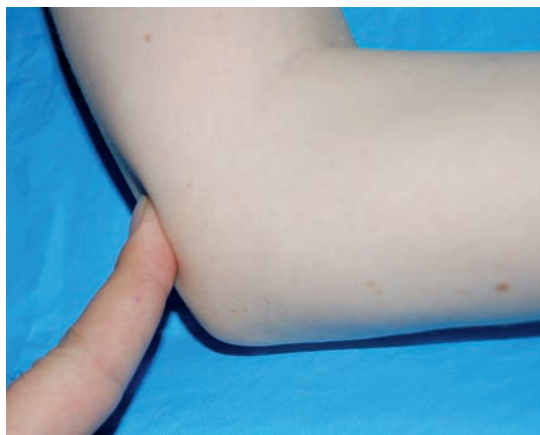


FIGURE 2.5. Palpation of ulnar nerve behind medial epicondyle.

Bony Prominences of the Epicondyles and the Apex of the Olecranon

The examiner puts his thumb on the lateral epicondyle, the index finger on the olecranon and the middle finger on the medial epicondyle and feels for the relationship of these bony prominences. They form a triangle when the elbow is flexed to 90° and a straight line when the elbow is in extension (Figures 2.6 and 2.7).

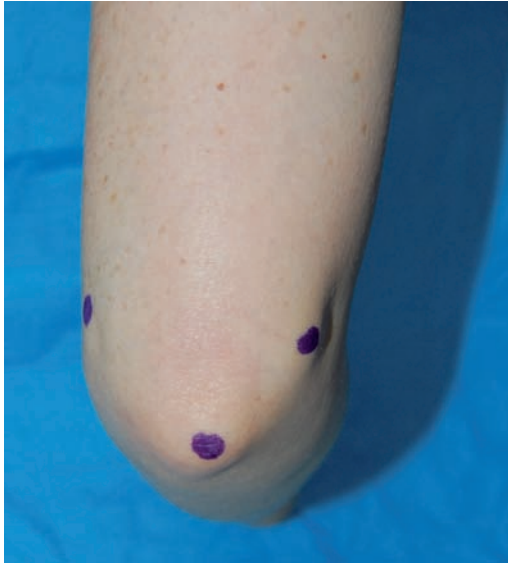

FIGURE 2.6. Three bony points.

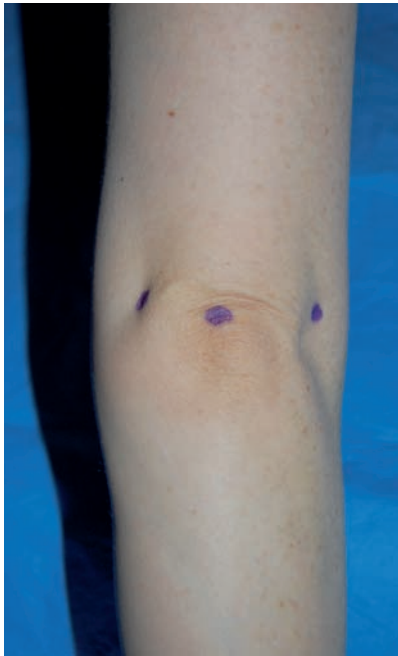

FIGURE 2.7. Three bony points in full extension.

From the Front

Lacertus fibrosus is the most prominent band anteriorly when the patient is made to flex the forearm against resistance (Figure 2.8)

The biceps tendon is lateral to lacertus fibrosus

The brachial artery is felt medial to the biceps tendon

The median nerve is medial to the brachial artery.

The musculocutaneous nerve is lateral to the biceps tendon.

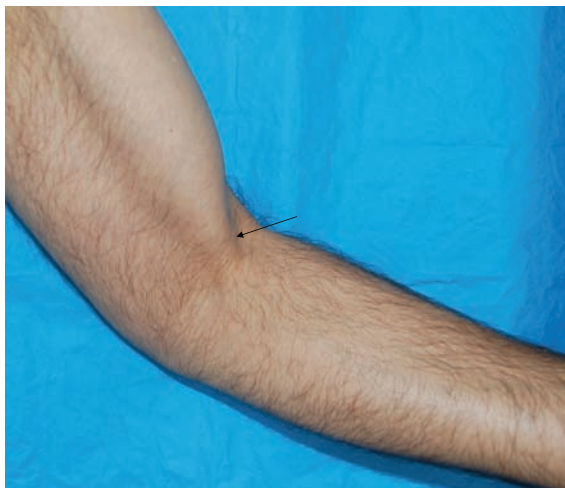

FIGURE 2.8. Lacertus fibrosus.

Range of Movement**Flexion – Extension**

The patient is asked to abduct the shoulder to 90° , and then bend the elbow as far as possible. The degree of flexion and extension is measured (Figures 2.9 and 2.10).

Normal Flexion $\rightarrow 0$ to 140°

Hyperextension $\rightarrow 0$ to -10°

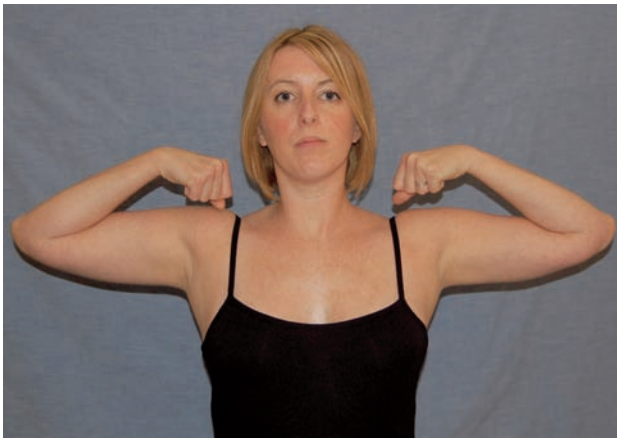

FIGURE 2.9. Flexion.

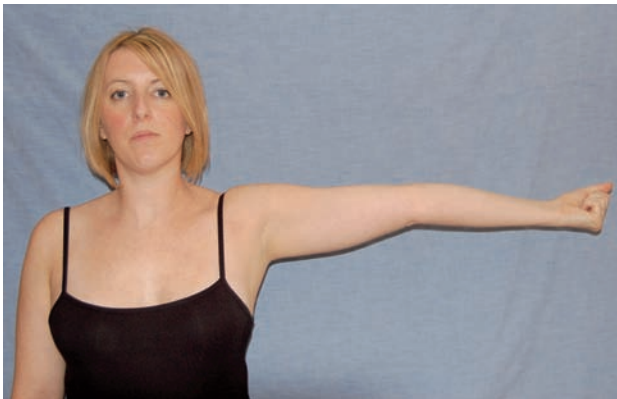

FIGURE 2.10. Extension.

Pronation – Supination

The patient is instructed to show the palm and back of the hands while he flexes the elbows to 90° and keeps the arms by his side (Figures 2.11 to 2.14).

Normal Range:

Pronation → 0 to 70°

Supination → 0 to 85°

The passive range of movement is evaluated after the active range is measured by the examiner.

Passive movements should be pain-free.

If pain elicited

with hyperextension → posterior impingement

with hyperflexion → anterior impingement (between coronoïd tip and fossa)

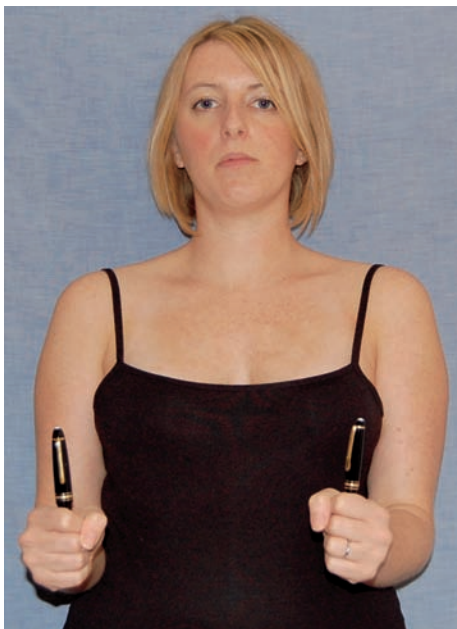

FIGURE 2.11. Neutral rotation.

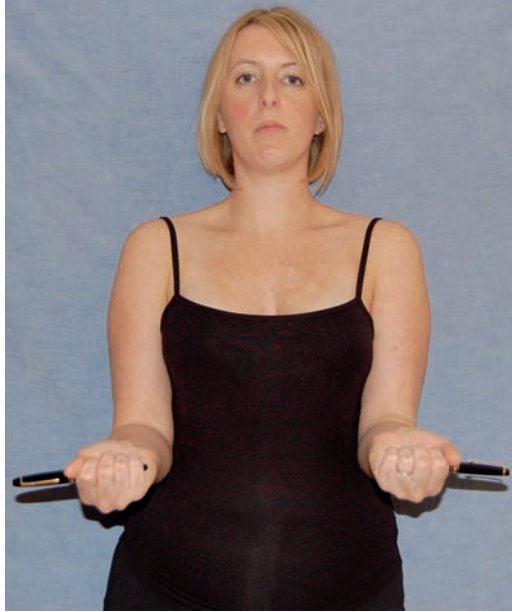

FIGURE 2.12. Supination.

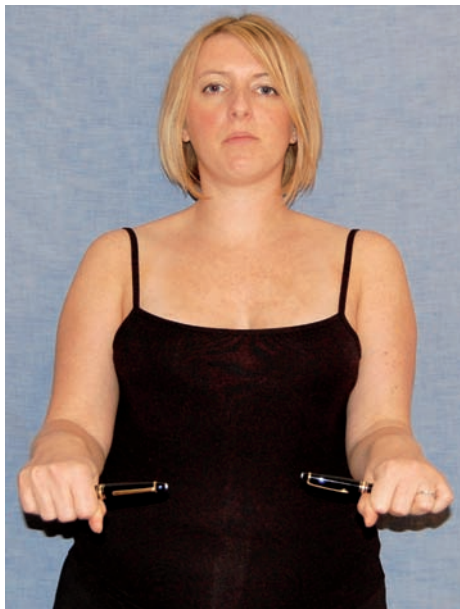

FIGURE 2.13. Pronation.

During examination for the passive range, the examiner feels for the end point of each movement. The common end points are:

Bony→Two hard surfaces meeting, bone to bone (e.g., elbow extension as the olecranon locks into the olecranon fossa).

Capsular→Leathery feel, further motion available (e.g. forearm pronation and supination).

Soft tissue approximation→Soft tissue contact (e.g., elbow flexion as the movement is blocked by the bulk of the arm and forearm muscles).

Spasm→Muscle contraction limits motion

Springy block→Intra-articular block; rebound is felt

Empty→Movement causes pain, pain limits movement



FIGURE 2.14. Incorrect method of recording pronation. The elbows must be kept by the sides.

Muscle Testing**Biceps (Musculocutaneous nerve)**

To assess the biceps, the patient is asked to flex the elbow to 90° and maintain the position. The examiner supports the elbow with one hand, holds the wrist with the other hand and attempts to extend the elbow (Figure 2.15).

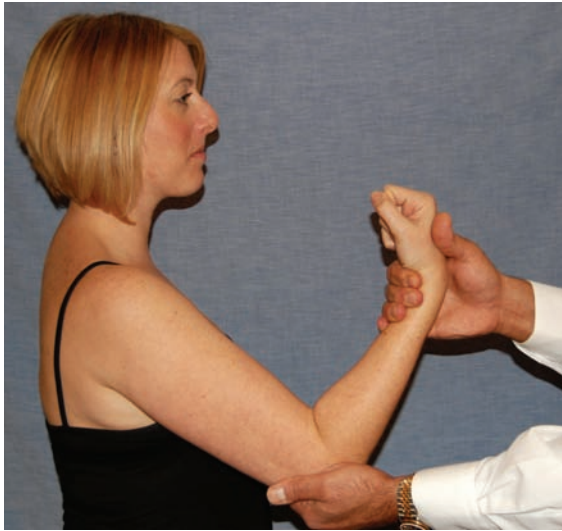

FIGURE 2.15. Assessing the biceps.

Triceps (Radial Nerve)

To assess the triceps, the patient is asked to flex the elbow to 90° and maintain the position. The examiner supports the elbow with one hand and holds the wrist with the other hand and attempts to flex the elbow (Figure 2.16).

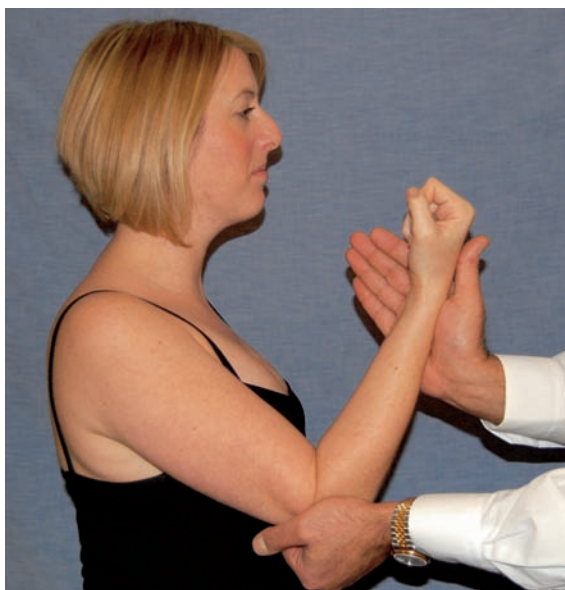

FIGURE 2.16. Assessing the triceps.

Brachioradialis (Radial Nerve)

The patient is asked to flex the elbow to 90° with the wrist in neutral and to maintain that position. The examiner holds the elbow with one hand and exerts downward pressure to the radial border of the distal forearm with the other hand. The brachioradialis muscle stands out in the proximal forearm (Figure 2.17).

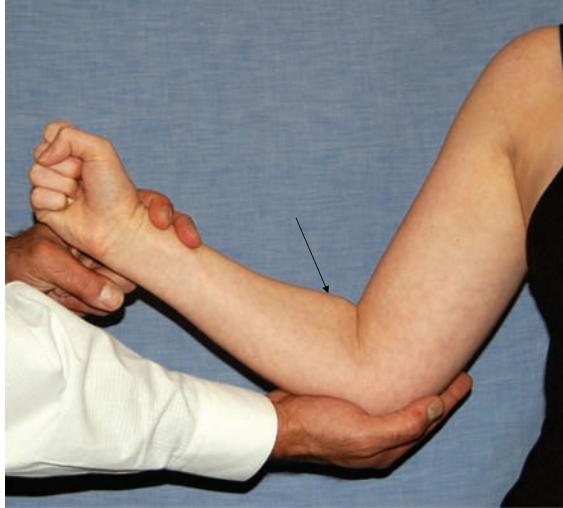

FIGURE 2.17. Assessing the brachioradialis. The black arrow points toward the muscle.

Pronator teres and Pronator quadratus (Median nerve)

(Tested together)

The patient is asked to flex the elbow to 90° with the forearm fully pronated and maintain the position. The examiner stabilizes the elbow with one hand and with the other hand holds the wrist and attempts to supinate the forearm (Figure 2.18).

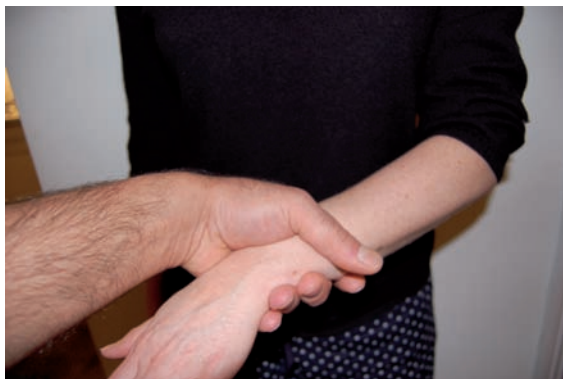

FIGURE 2.18. Assessing the pronators.

Supination of the elbow joint is provided by the supinator (radial nerve) and the biceps muscle (musculocutaneous nerve). The power of the supinator muscle cannot be elicited in isolation. To assess the overall supination power of the forearm, the patient is asked to flex the elbow to 90° with the forearm fully supinated and maintain the position. The examiner stabilizes the elbow with one hand and with the other hand holds the wrist and attempts to pronate the forearm (Figure 2.19).

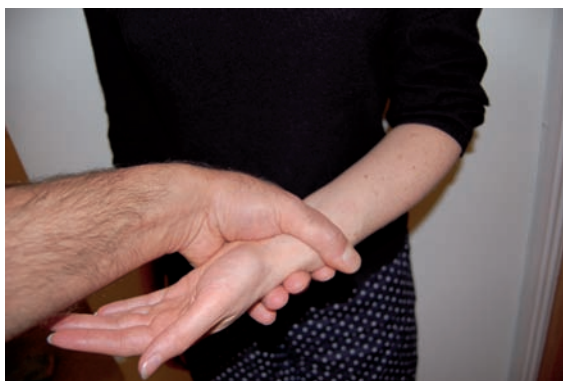

FIGURE 2.19. Assessing the supinators.

Complete neurological examination is mandatory and this is covered in the Hand and Wrist chapter.

Special Tests

Varus Stress Test

The examiner puts one hand above and one hand below the elbow. With the forearm in full supination and the elbow in extension, the examiner exerts varus force (Figure 2.20).

Opening of the lateral compartment → lateral ligament laxity

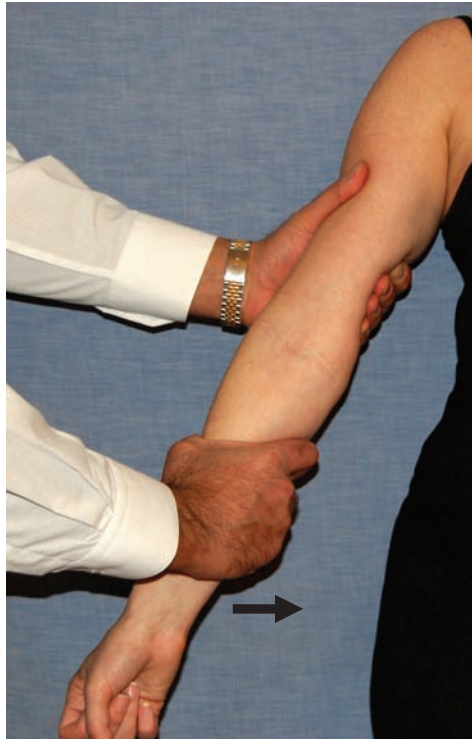

FIGURE 2.20. Varus stress test. Note the direction of force.

Valgus Stress Test

The examiner puts one hand above and one hand below the elbow. With the forearm in full supination and the elbow in slight flexion, the examiner exerts valgus force (Figure 2.21).

Opening of medial compartment → medial ligament laxity

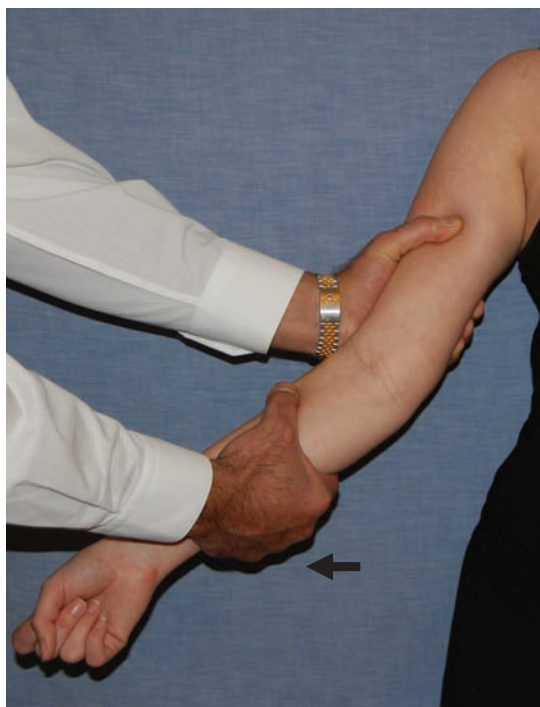

FIGURE 2.21. Valgus stress test. Note the direction of force.

Lateral Pivot Shift Test

This is a test for posterolateral rotatory instability of the elbow: Ask the patient to place the arm over his head. The examiner then holds the patient's wrist and the elbow. The forearm is fully supinated, and valgus stress is applied as the elbow is moved from the fully extended position to a flexed position. This reproduces posterolateral rotatory instability, which manifests as pain and apprehension in the patient.

Tinel's Test

For ulnar nerve neuropathy.

With the elbow flexed to 20°, the examiner taps gently over the ulnar groove between the olecranon and the medial epicondyle. In a positive test, there is a tingling sensation down the forearm to the ulnar distribution in the hand.

Provocative Test for Lateral Epicondylitis

The patient is instructed to extend the wrist and fingers and maintain the position. The examiner applies downward force to the middle finger (ECRB inserts into the base of the third metacarpal) while the elbow is in full extension. In a positive test, it produces pain at the lateral epicondyle.