

Diseases of the Inner Ear

A Clinical, Radiologic, and Pathologic Atlas

Bearbeitet von
Masoud Motasaddi Zarandy, John Rutka

1st Edition. 2010. Buch. vii, 93 S. Hardcover
ISBN 978 3 642 05057 2
Format (B x L): 19,3 x 26 cm

[Weitere Fachgebiete > Medizin > Sonstige Medizinische Fachgebiete > Radiologie,
Bildgebende Verfahren](#)

Zu [Inhaltsverzeichnis](#)

schnell und portofrei erhältlich bei

The logo for beck-shop.de features the text 'beck-shop.de' in a bold, red, sans-serif font. Above the 'i' in 'shop' are three red dots of increasing size. Below the main text, the words 'DIE FACHBUCHHANDLUNG' are written in a smaller, red, all-caps, sans-serif font.

beck-shop.de
DIE FACHBUCHHANDLUNG

Die Online-Fachbuchhandlung beck-shop.de ist spezialisiert auf Fachbücher, insbesondere Recht, Steuern und Wirtschaft. Im Sortiment finden Sie alle Medien (Bücher, Zeitschriften, CDs, eBooks, etc.) aller Verlage. Ergänzt wird das Programm durch Services wie Neuerscheinungsdienst oder Zusammenstellungen von Büchern zu Sonderpreisen. Der Shop führt mehr als 8 Millionen Produkte.

Core Messages

- › Major properties of cholesteatoma include bone erosion and secondary infection.
- › Both congenital and acquired cholesteatoma can cause intratemporal and intracranial complications.
- › Recidivistic rates (residual and recurrent disease) are higher in childhood cholesteatoma.
- › Mastoid surgery is required to provide a safe, dry and when possible better hearing ear.

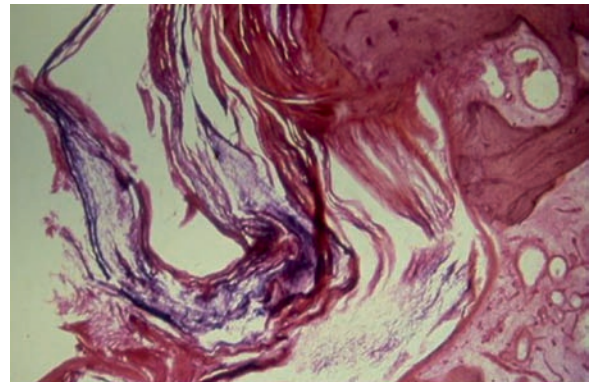


Fig. 2.1 Cholesteatoma (note its destructive effect on bone)

Cholesteatoma is a term whose initial use can be credited to Muller in 1838. The first case, however, of a cholesteatoma-like mass was reported by Du Verney in 1683, who described a mass between the cerebellum and the cerebrum. In essence, the term cholesteatoma represents the presence of the stratified squamous epithelium within the middle ear space that clinically has two significant properties, namely secondary infection and bone erosion (Fig. 2.1).

It is accepted that cholesteatoma may be either congenital or acquired [8]. To date, several pathogenic mechanisms have been proposed to explain the pathogenesis of cholesteatoma. Proposed theories of congenital cholesteatoma include: (a) the presence of an ectopic epidermis rest, (b) in-growth of meatal epidermis, (c) metaplasia following infection/inflammation, and somewhat interestingly, (d) reflux of amniotic fluid containing squamous epithelium in utero into the middle ear (Fig. 2.2).

The actual incidence of congenital cholesteatoma is difficult to determine. Nevertheless, greater awareness among physicians has occurred with the introduction

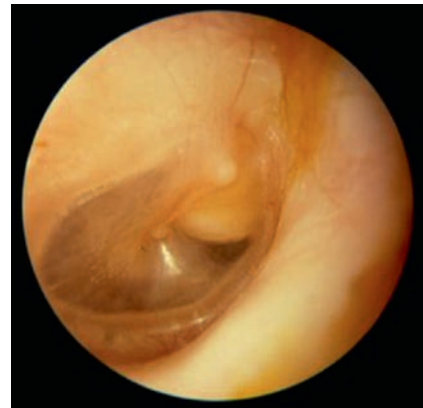

Fig. 2.2 Congenital cholesteatoma. Typically presents as a whitish mass (Michael's body) in epitympanum behind an intact tympanic membrane

of the high resolution CT and MRI. Perhaps as a result, its incidence seems to be increasing [5, 10].

Unlike primary acquired cholesteatoma, congenital cholesteatoma typically does not present with a prior

history of otorrhea, tympanic membrane perforation, or previous surgery. While there is hearing loss (usually conductive initially), the tympanic membrane is typically normal. With a close inspection, however, a pearly white mass (so-called Michael's body) medial to the ear drum is often noted [5, 7].

At the other end of the disease spectrum, the clinical picture of a child with otorrhea, hearing loss (conductive type), a tympanic membrane perforation in an atypical location together with a mastoid filled with cholesteatoma also may represent the end point in the natural history of congenital cholesteatoma. Distinguishing between congenital and acquired cholesteatoma is, however, not always that obvious [6].

Proposed theories for the pathogenesis of acquired cholesteatoma, include: (a) invaginations of the tympanic membrane from chronic Eustachian tube dysfunction resulting in retraction pockets (primary acquired cholesteatoma), (b) basal cell proliferation, (c) epithelial in-growth into the middle ear through a perforation (the immigration theory), (d) or inadvertent implantation (following myringotomy or tympanoplasty surgery), and (e) squamous metaplasia of the middle ear epithelium secondary to chronic infection/inflammation/persistent use of ototopical agents [8] (Figs. 2.3–2.5).

Congenital cholesteatoma of the temporal bone may be divided into four anatomic areas for consideration: (1) middle ear, (2) petrous apex, (3) perigeniculate area, and (4) primary cerebellopontine angle and combinations thereof [1].

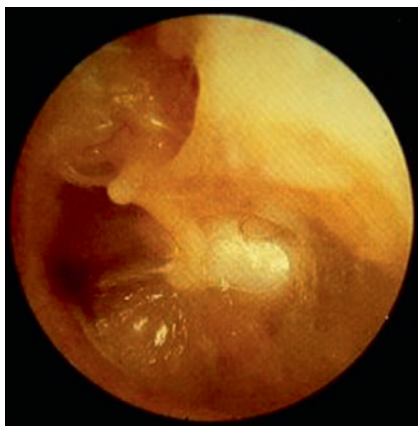


Fig. 2.3 Primary acquired cholesteatoma. Retraction pockets in the pars flaccida from chronic Eustachian tube dysfunction lead to the development of a keratin containing sac within the middle ear

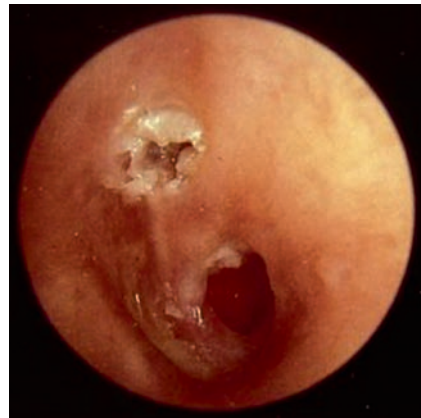

Fig. 2.4 Primary acquired cholesteatoma. Cholesteatoma is thought to arise from retraction pockets with the failure of epithelial migration leading to keratin accumulation and the development of a gradually expanding sac. A history of a chronic, painless, and malodorous discharging ear is not unusual

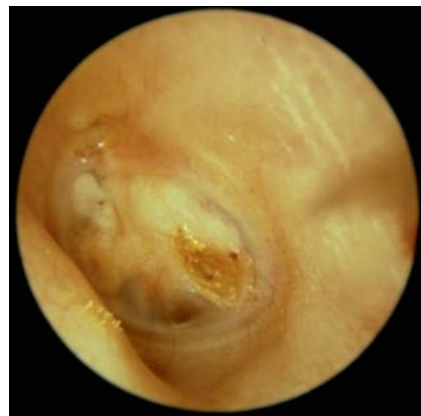

Fig. 2.5 Acquired cholesteatoma. Implantation of the squamous epithelium lead to the development of cholesteatoma after tympanoplasty

The most common sites of presentation on physical examination are behind the anterior-superior and posterior-superior quadrants of the tympanic membrane.

While conductive hearing loss tends to be the most common presenting symptom, perigeniculate and petrous apex cholesteatomas are not infrequently present with an insidious or rapidly progressive facial nerve paralysis [5].

Bone erosion and secondary infection from cholesteatoma can lead to both intratemporal (facial paralysis, infective cochleolabyrinthitis, etc.) and intracranial complications (meningitis, brain abscess, sigmoid sinus

thrombophlebitis, etc.) in both congenital and acquired forms of the disease.

Occasionally, a patient with congenital cholesteatoma may present with complications of the disease. Complications of congenital cholesteatoma that arise from bone erosion not infrequently involve the facial nerve at the level of the geniculate ganglion and its labyrinthine segment. Despite significant erosion into the otic capsule, partial hearing and vestibular function are not infrequently maintained [13].

Bilateral congenital cholesteatoma is a rare condition but has been reported [7] (Figs. 2.6–2.10).

In general, intracranial complications are more likely to arise in primary acquired cholesteatoma as a result of secondary infection. Erosion into the otic capsule of the lateral semicircular canal is frequently identified in primary acquired cholesteatoma where disease spread usually follows an orderly pattern through a route of least resistance via the aditus ad antrum, antrum, and into the mastoid bone proper (Figs. 2.11–2.25).

Cholesteatoma is still considered a surgical disease requiring either the complete removal of its squamous lined matrix or its exteriorization for continued aural toilet and ventilation. To this end, different tympanomastoidectomy procedures are available.

Surgery for cholesteatoma is generally divided into combined approach tympanomastoidectomy (canal wall up) or modified radical and radical (canal

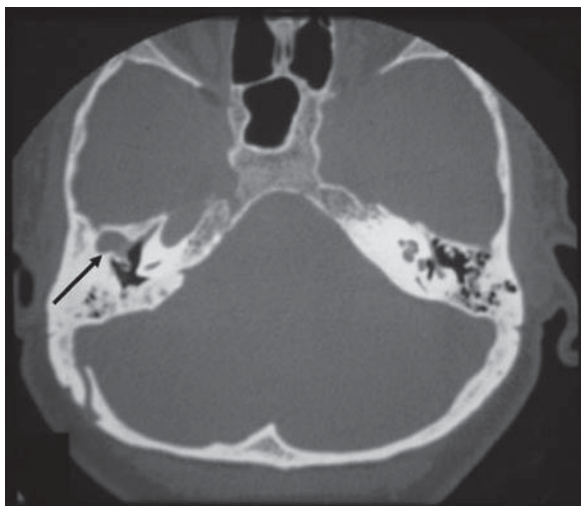

Fig. 2.6 Congenital cholesteatoma (*arrow*). Typically presents as a mass in the epitympanum behind an intact tympanic membrane

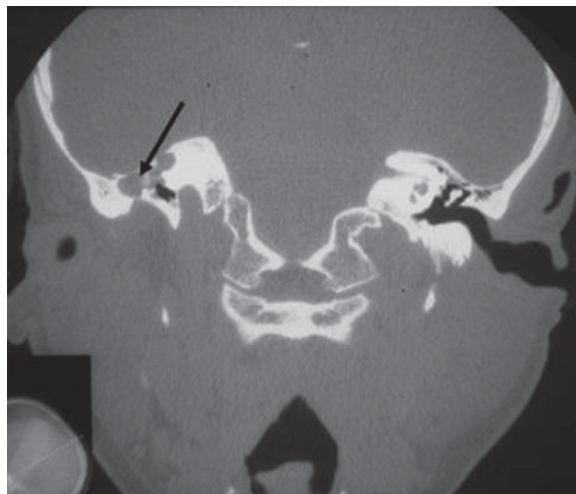


Fig. 2.7 Congenital cholesteatoma. Note the smooth bony erosions in the anterior epitympanum typical for cholesteatoma. See *arrow*

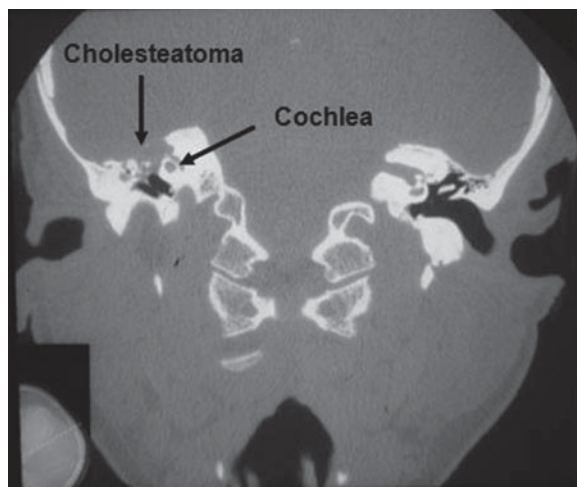


Fig. 2.8 Congenital cholesteatoma demonstrating erosion into the cochlea. Patient presented with an acute facial nerve paralysis and a longstanding sensorineural hearing loss. Vestibular function was partially intact

wall down) mastoidectomy procedures. The first and foremost goal of surgery is to provide a safe, dry and when possible, a better hearing ear. Reconstruction of the ossicular chain (ossiculoplasty) often depends on the remaining anatomy of the middle ear and Eustachian tube function. Hearing results in congenital cholesteatoma frequently depend on its location and the significant involvement of the ossicular chain.

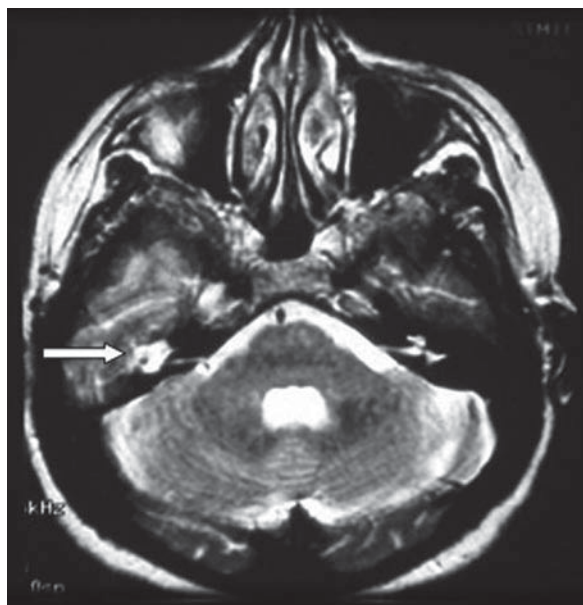


Fig. 2.9 MRI T2-weighted image demonstrating congenital cholesteatoma (see *arrow*). Relative magnitude of hydrogen atoms in keratin causes it to assume a bright fluid-like signal similar to cerebrospinal fluid

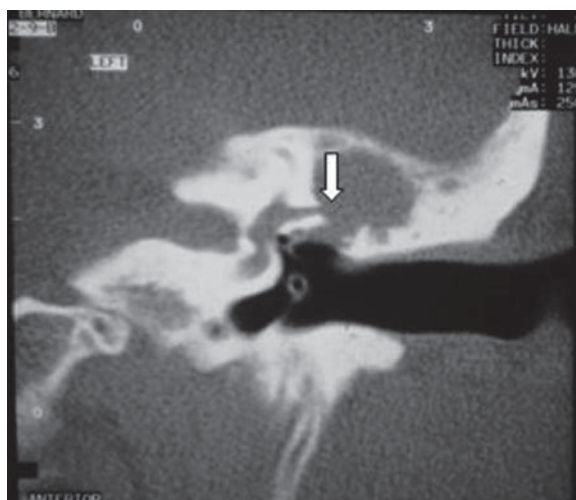

Fig. 2.11 Primary acquired cholesteatoma causing erosion with fistula into the lateral semicircular canal (see *arrow*). Axial CT scan

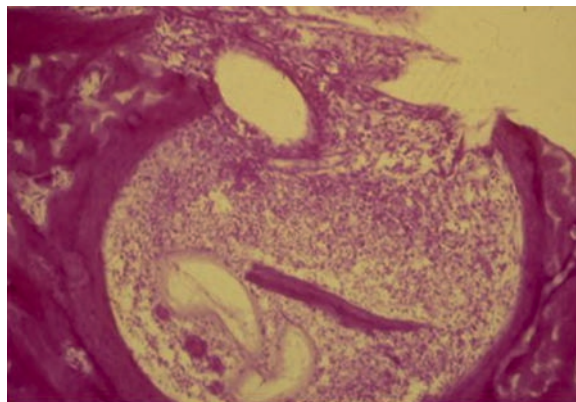


Fig. 2.12 Acute bacterial labyrinthitis from cholesteatoma involving the lateral semicircular canal

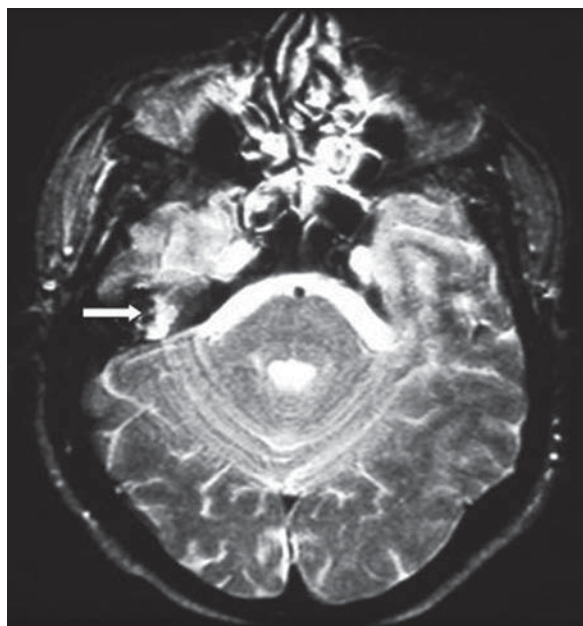


Fig. 2.10 MRI image of intralabyrinthine cholesteatoma (*arrow*)

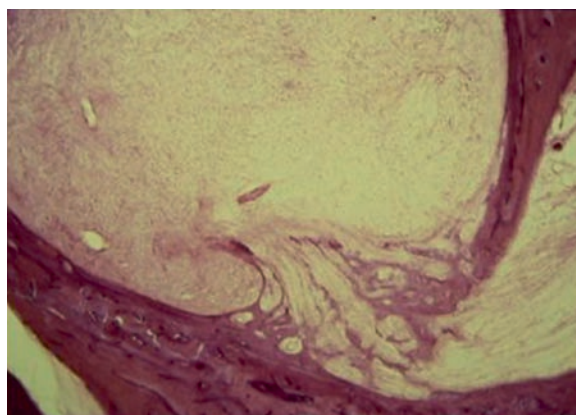


Fig. 2.13 Acute bacterial labyrinthitis involving the superior semicircular canal from cholesteatoma

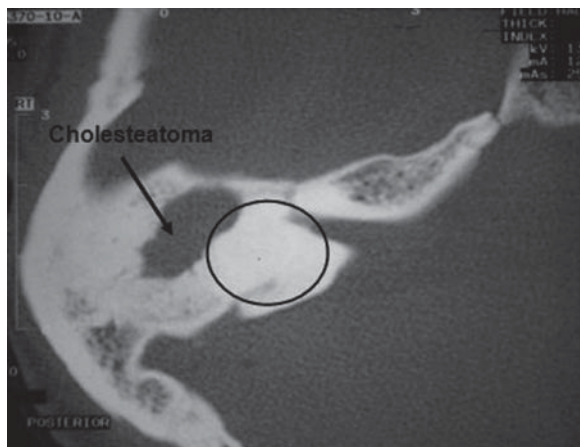


Fig. 2.14 Axial CT scan. Labyrinthitis ossificans of the cochlea and labyrinth following acute labyrinthitis caused by cholesteatoma. Note the absence of inner ear structures. See black circle

When restricted to the epitympanum, good results in hearing following surgery are often possible especially if the cholesteatoma is diagnosed and treated early [3, 11, 12].

From the world literature, it would appear that the best treatment results in childhood cholesteatoma are obtained in the early clinical stage. Open procedures (i.e., atticotomy, modified radical mastoidectomy, etc.) seem to have the best long-term results. However, canal wall up procedures have been recommended as the first-line surgical option in children. Nevertheless, the recidivistic (residual and recurrent disease) rate tends to be higher. Each case therefore needs to be evaluated separately and the appropriate technique should be tailored to the individual patient's needs and surgical expectations [4, 5].

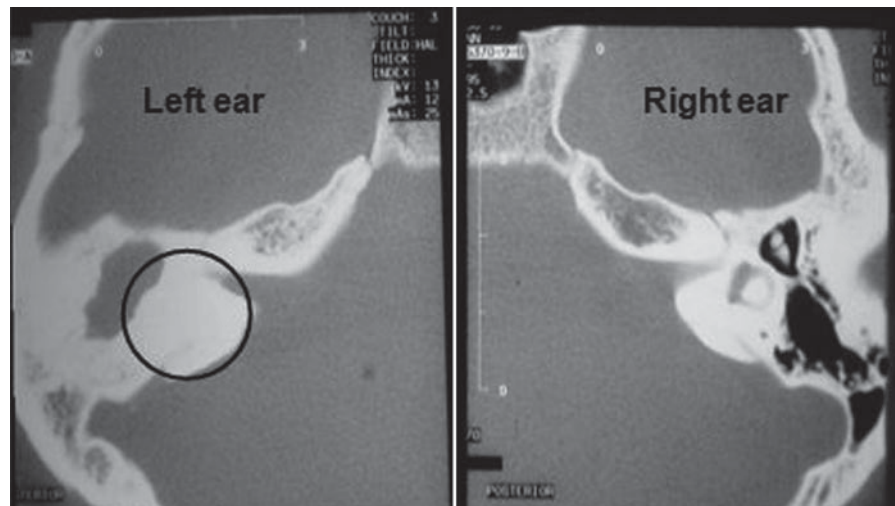


Fig. 2.15 Labyrinthitis ossificans (see circle) secondary to cholesteatoma in the left ear (same patient as in Fig. 2.14). Note the normal lateral SCC and ossicles in right ear

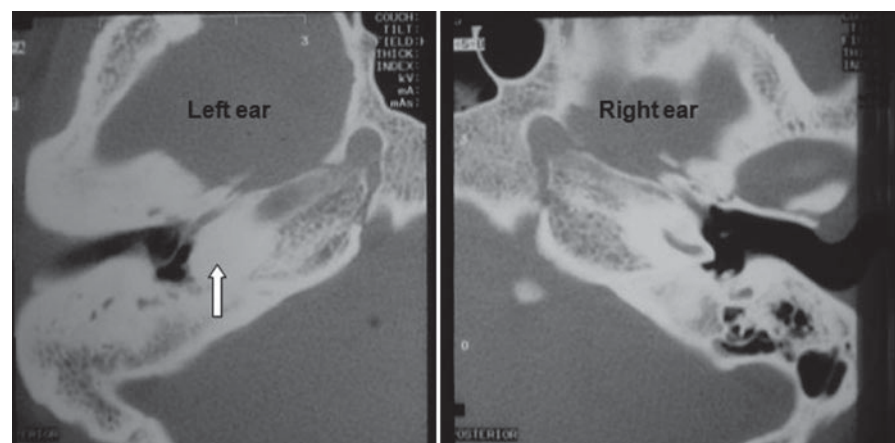


Fig. 2.16 Labyrinthitis ossificans from cholesteatoma (same patient as in Figs. 2.14 and 2.15). Note the absence of cochlea in the left ear compared to the right side

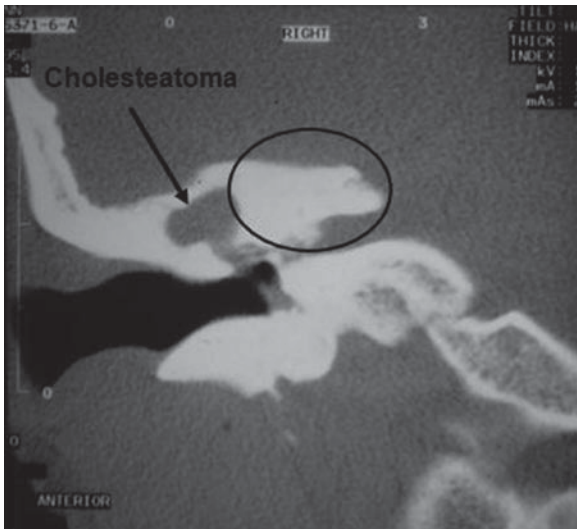

Fig. 2.17 Coronal CT scan demonstrating labyrinthitis ossificans of semicircular canals (see *circle*) (same patient as in Figs. 2.14 and 2.15)

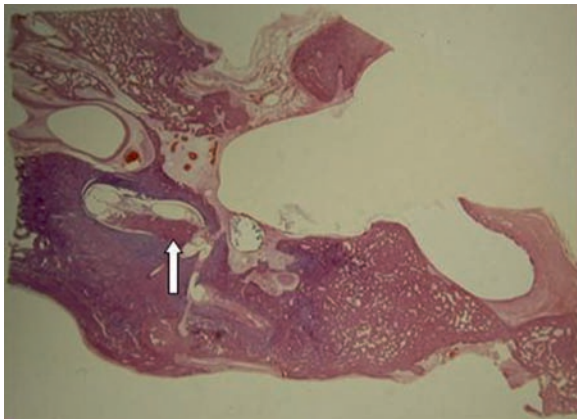


Fig. 2.18 Labyrinthitis ossificans from cholesteatoma. The ossification process (osteoneogenesis) usually starts in the basal turn of the cochlea closest to the round window membrane. See *arrow*. Note that a previous mastoidectomy had been performed

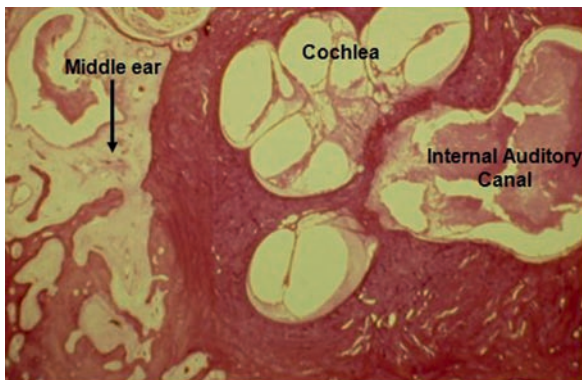

Fig. 2.19 Meningitis secondary to cholesteatoma

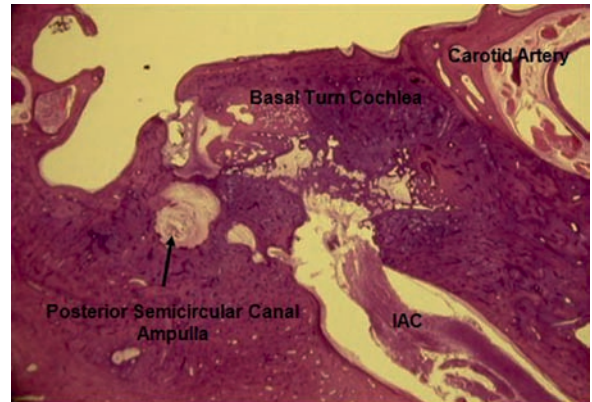


Fig. 2.20 Labyrinthitis ossificans demonstrating osteoneogenesis postmeningitis. The patient survived the meningitis but developed a complete cochleovestibular loss

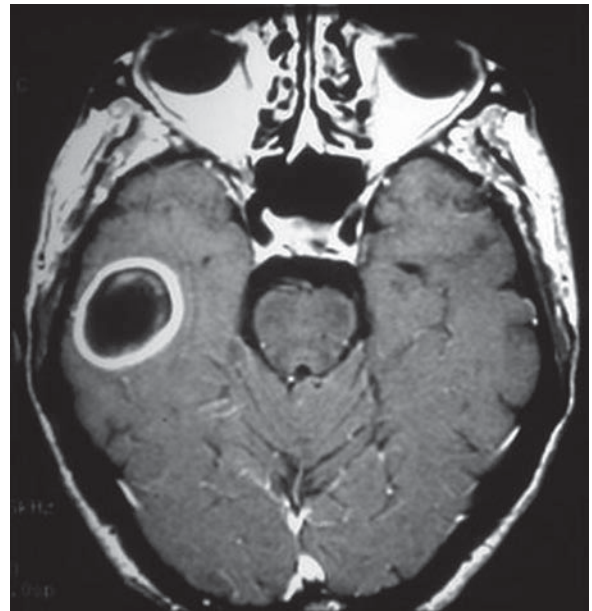


Fig. 2.21 Intracranial complication of cholesteatoma. Temporal lobe brain abscess, secondary to cholesteatoma

Petrous apex cholesterol granulomas share many similar clinical features with cholesteatomas in the petrous apex. However, their pathogenesis appears very different. A cholesterol granuloma specifically represents a foreign body granulomatous response to cholesterol crystals in the submucosal tissues of air cells in the temporal bone. While cholesterol granulomas are frequently found in patients with chronic otitis media, it is thought that petrous apex cholesterol

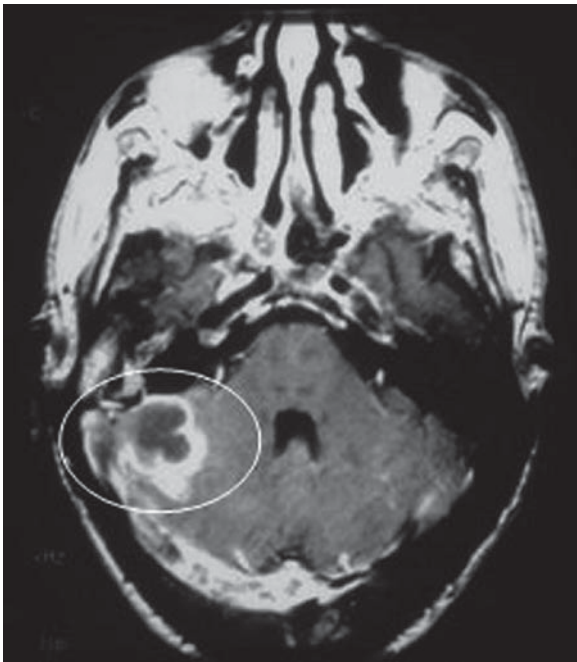


Fig. 2.22 Intracranial complications of cholesteatoma. Cerebellar abscess and sigmoid sinus thrombophlebitis (see circle) as complications of cholesteatoma

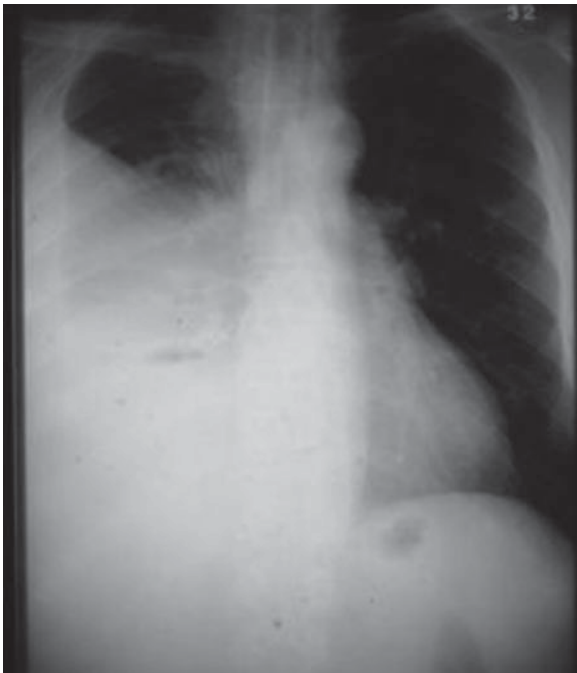

Fig. 2.23 Lung abscess secondary to infected thromboemboli from sigmoid sinus thrombophlebitis (same patient as in Fig. 2.21). Le Meriere's disease is used to describe this phenomenon

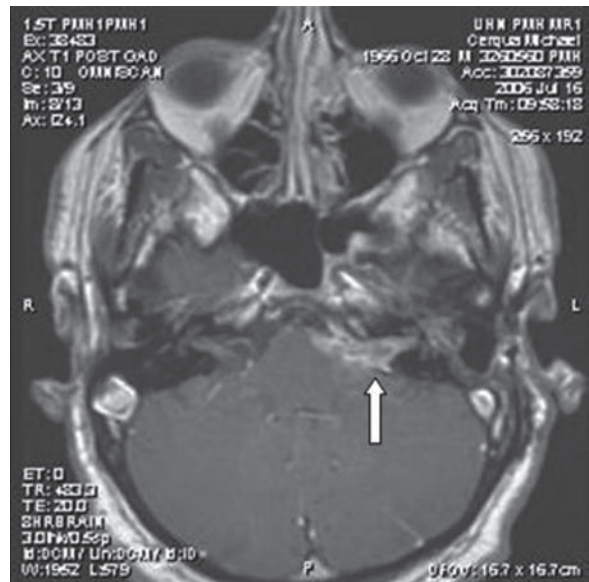


Fig. 2.24 Intracranial complication. Abscess in the internal auditory canal secondary to cholesteatoma (see arrow)

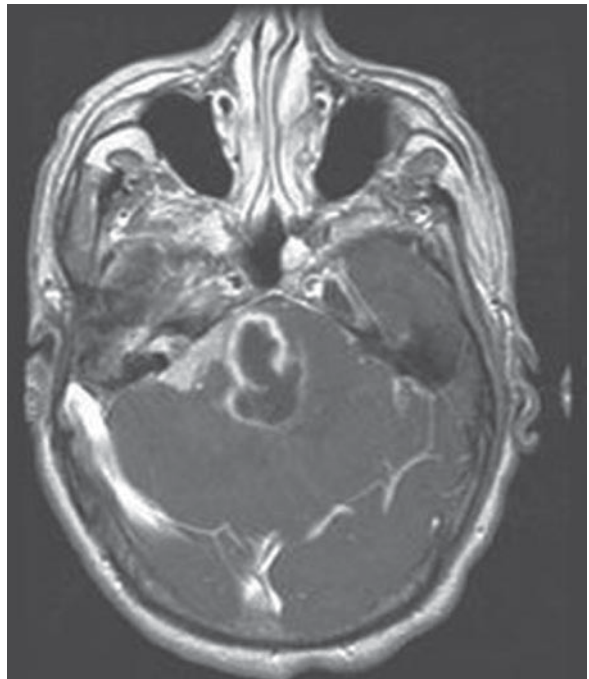


Fig. 2.25 Intracranial complication. Pontine abscess secondary to cholesteatoma

granulomas arise when a normally pneumatized air cell becomes isolated from its air supply.

Progressive growth of a petrous apex cholesterol granuloma may result in a petrous apex syndrome with diplopia from the abducens nerve involvement and the

trigeminal and facial nerve palsies. The onset of the sensorineural hearing loss and vertigo implies erosion into the inner ear. Treatment requires extensive surgical drainage following the pneumatized perilymphatic air

cell tracts surrounding the otic capsule when inner ear function is present. However, recurrences are not infrequent and multiple surgeries are often required [2, 9] (Figs. 2.26–2.31).

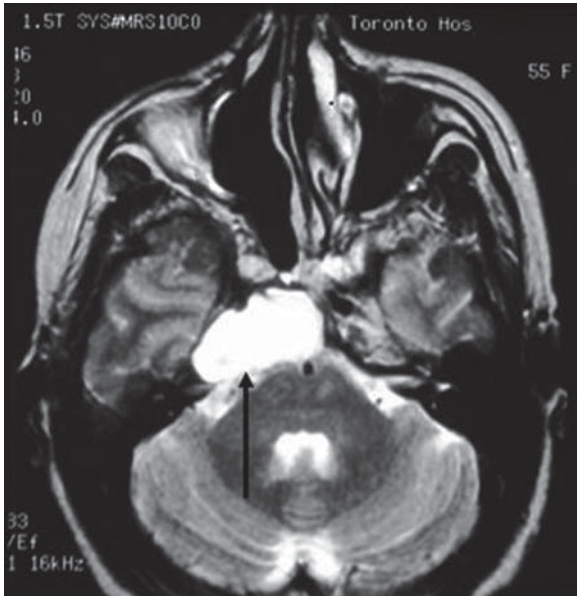


Fig. 2.26 MRI scan demonstrating clival epidermoid (arrow). Example of a congenital rest of epithelial cells remote from the middle ear and mastoid

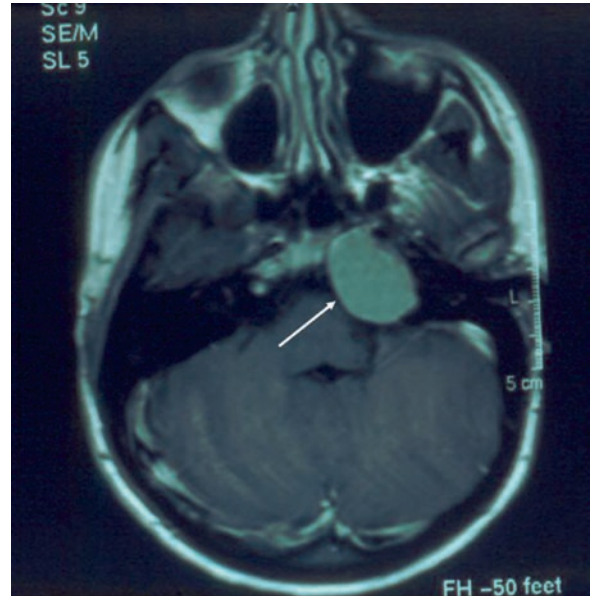


Fig. 2.28 MRI scan demonstrating a large left petrous apex cholesteral granuloma in a patient presenting with diplopia from an abducens nerve palsy. See arrow

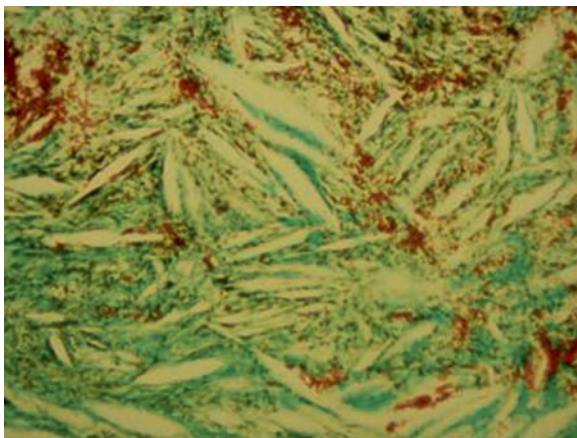


Fig. 2.27 Cholesterol granulomas are characterized by numerous empty, ovoid, slit-like spaces that are surrounded by foreign body giant cells and fibrous tissue

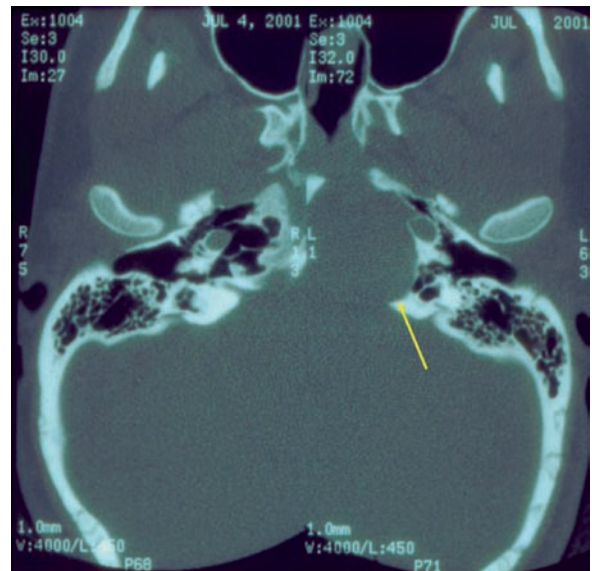
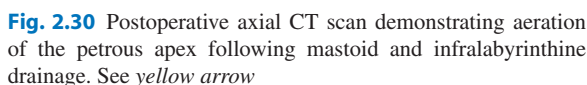


Fig. 2.29 CT demonstrating smooth expansile mass in the petrous apex. Same patient as in Fig. 2.28. See yellow arrow



1. Cummings CW (1991) Otolaryngology, head and neck surgery. In: Chronic otitis media, mastoiditis, and petrositis, 3rd edn. Mosby, Philadelphia
2. Edamatsu H, Aoki F, Mitsu T, Yamaguti H, Tokumaru A, Watanabe K, Fukazawa T (2002) Navigation-aided surgery for congenital cholesteatoma at the petrous apex. *Nippon Jibiinkoka Gakkai Kaiho* 105(12):1212–1215
3. Faramarzi A, Motasaddi-Zarandy M, Khorsandi MT (2008) Intraoperative finding in revision chronic otitis media surgery. *Arch Iran Med* 11(2):196–199
4. Karmody CS, Byahatti SV, Blevins N, Valtonen H, Northrop C (1998) The origin of congenital cholesteatoma. *Am J Otol* 19(3):292–297
5. Kazahaya K, Potsic WP (2004) Congenital cholesteatoma. *Curr Opin Otolaryngol Head Neck Surg* 12(5):398–403
6. Koltai PJ, Nelson M, Castellon RJ, Garabedian EN, Triglia JM, Roman S, Roger G (2002) The natural history of congenital cholesteatoma. *Arch Otolaryngol Head Neck Surg* 128(7):804–809
7. Kuczkowski J, Babinski D, Stodulski D (2004) Congenital and acquired cholesteatoma middle ear in children [Polish]. *Otolaryngol Pol* 58(5):957–964
8. Lesinskas E, Kasinskas R, Vainutiene V (2002) Middle ear cholesteatoma: present-day concepts of etiology and pathogenesis [Lithuanian]. *Medicina (Kaunas)* 38(11):1066–1071; quiz 1141
9. Nelson M, Roger G, Koltai PJ, Garabedian EN, Triglia JM, Roman S, Castellon RJ, Hammel JP (2002) Congenital cholesteatoma: classification, management, and outcome. *Arch Otolaryngol Head Neck Surg* 128(7):810–814
10. Nishizaki K, Yamamoto S, Fukazawa M, Yuen K, Ohmichi T, Masuda Y (1996) Bilateral congenital cholesteatoma. *Int J Pediatr Otorhinolaryngol* 34(3):259–264
11. Okano T, Iwanaga M, Yonamine Y, Minoyama M, Kakinoki Y, Tahara C, Tanabe M (2004) Clinical study of congenital cholesteatoma of the middle ear [Japanese]. *Nippon Jibiinkoka Gakkai Kaiho* 107(11):998–1003
12. Sudhoff H, Liang J, Dazert S, Borkowski G, Michaels L (1999) Epidermoid formation in the pathogenesis of congenital cholesteatoma – a current review [German]. *Laryngorhinootologie* 78(2):63–67
13. Zarandy MM, Rajati M, Khorsandi MT (2007) Recurrent meningitis due to spontaneous cerebrospinal fluid otorrhea in adults. *Int J Pediatr Otorhinolaryngol* 3:113–116