

# Chemicals in Surgical Periodontal Therapy

von  
Alexandrina L. Dumitrescu

1. Auflage

Chemicals in Surgical Periodontal Therapy – Dumitrescu

schnell und portofrei erhältlich bei [beck-shop.de](http://beck-shop.de) DIE FACHBUCHHANDLUNG

Thematische Gliederung:

Zahnmedizin

Springer 2011

Verlag C.H. Beck im Internet:

[www.beck.de](http://www.beck.de)

ISBN 978 3 642 18224 2

Bone replacement grafts are widely used to promote bone formation and periodontal regeneration. Conventional surgical approaches, such as open flap debridement, provide critical access to evaluate and detoxify root surfaces as well as establish improved periodontal form and architecture; however, these surgical techniques offer only limited potential in restoring or reconstituting component periodontal tissues (Fig. 2.1). Bone grafting materials function, in part, as structural scaffolds and matrices for attachment and proliferation of anchorage-dependent osteoblasts. Multiple classification systems have been used to organize bone replacement grafts, which commonly include source (e.g., allograft), chemical composition (e.g., calcium phosphate) and physical properties (e.g., ceramic). Advances in material sciences, however, have increasingly blurred such boundaries between types of bone replacement grafts (Reynolds et al. 2010).

Bone replacement grafts (bone grafts and bone graft substitutes) provide a structural framework for clot development, maturation and remodeling that supports bone formation in osseous defects. Bone grafting materials also exhibit a variable capacity to promote the coordinated formation of bone, cementum and periodontal ligament (PDL) when placed and retained in periodontal defects. Bone grafting materials must possess the attributes of biocompatibility (lacking an immunogenic response) and osteoconductivity (providing a structure and surface topography that permit cellular attachment, proliferation and migration). Bone replacement grafts may also possess other properties that support osteogenesis (Reynolds et al. 2010). Ideal characteristics of a bone graft are: nontoxic, nonantigenic, resistant to infection, no root resorption or ankylosis, strong and resilient, easily adaptable, ready and sufficiently available, minimal

surgical procedure, stimulate new attachment and be able to trigger osteogenesis, cementogenesis and formation of a functional periodontal ligament (Rosenberg and Rose 1998; Nasr et al. 1999).

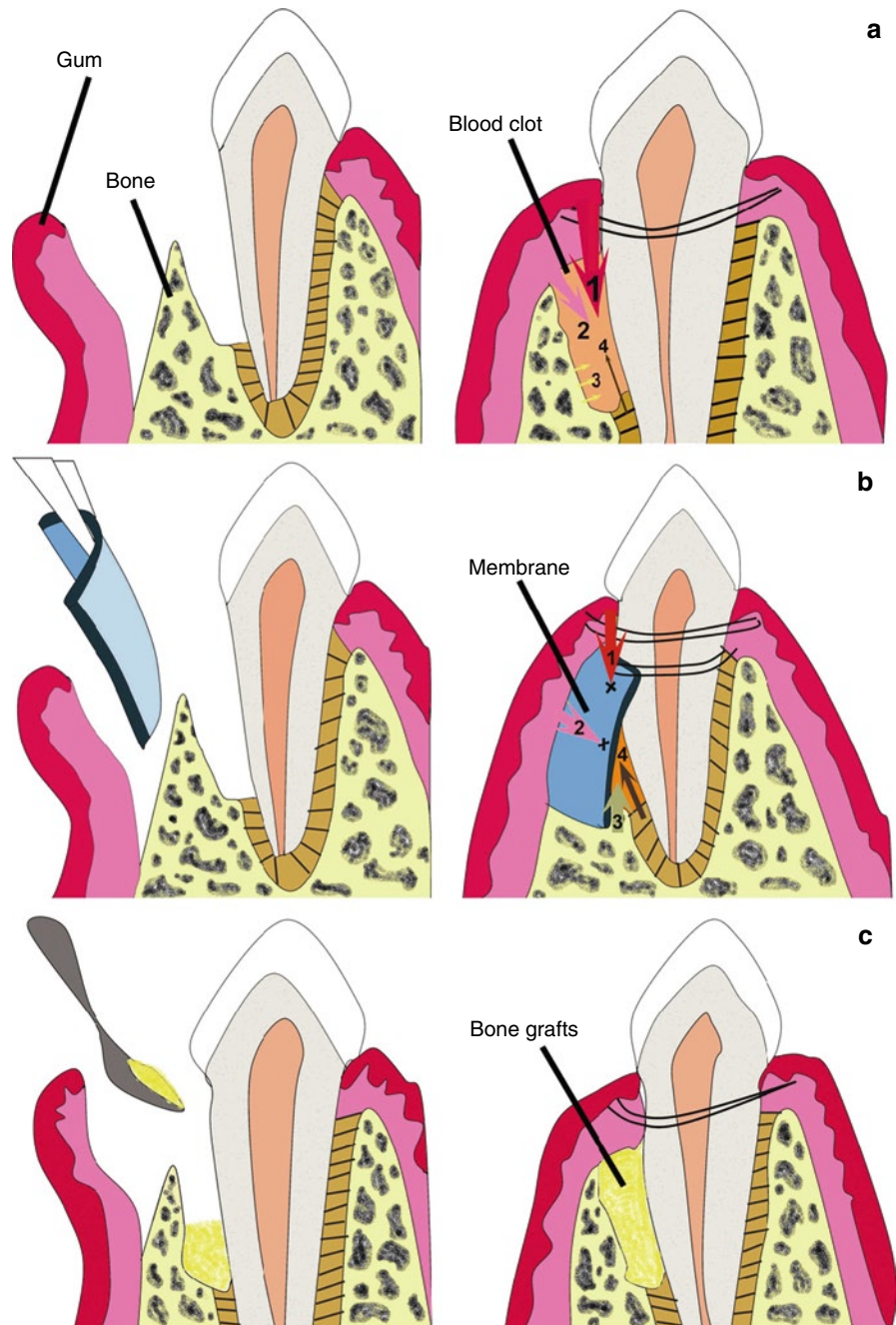
Osteogenic grafting materials, such as cancellous bone/bone marrow, contain living cells that are capable of differentiation and formation of bone. Osteoinductive grafting materials, such as demineralized bone matrix (DBM), provide a biologic stimulus (proteins and growth factors) that induces the progression of mesenchymal stem cells and other osteoprogenitor cells toward the osteoblast lineage (Reynolds et al. 2010). *Osteoinduction* is a process or a set of processes that stimulate the phenotypic conversion of progenitor cells within the healing wound to those that can form osseous tissue (Nasr et al. 1999). Most bone replacement grafts are osteoconductive, relatively inert filling materials and integrate with new bone. *Osteoconduction* defines the process that permits osteogenesis when cells already committed to bone formation are present in a closed environment (Nasr et al. 1999).

In general, bone replacement grafts can be categorized into autogenous, allograft, alloplast and xenograft sources.

## 2.1 Autogenous Grafts

Autogenous bone graft, which is harvested from the patient's own body, is considered ideal because of its osteoconductive and osteoinductive properties and because it contains a source of osteoprogenitor cells. It is still considered the gold standard by which other grafting materials are compared (Rosenberg and Rose 1998).

**Fig. 2.1** Schematic diagrams of several techniques commonly used in periodontal surgery. (a) Open flap debridement (OFD) procedure involves the periodontal surgeon lifting the gum away from the tooth and surrounding bone, providing increased access for scaling and root planing. However, periodontal defects, if left empty after OFD, fill with the first cells to reach the area, that is, epithelial cells (1) and fibroblasts (2), after cell proliferation, which generates a core of fibro-epithelial tissues that attach to the root surface, hence bone (3) and periodontal ligament (4) regeneration are hampered. (b) Guided tissue regeneration (GTR) is a surgical procedure that utilizes a barrier membrane which is placed under the gum and over the remaining bone to prevent epithelial down-growth (1) and fibroblast transgrowth (2) into the wound space, thereby maintaining a space for true periodontal tissue regeneration (3 and 4). (c) The use of bone grafts is a surgical procedure that replaces missing bone with material from the patient's own body (autogenous bone) or an artificial, synthetic or natural substitute. Bone growth may be stimulated by the grafts and new bone fills the defect which may provide support for the tooth (Chen et al. 2010) (Reprinted with permission from Elsevier)

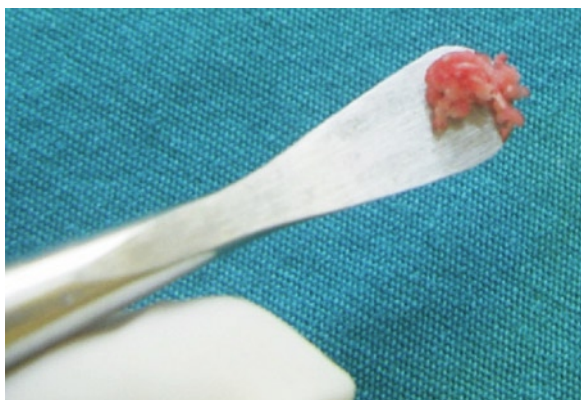


### 2.1.1 Intraoral Autografts

Intraoral autogenous bone grafts harvested from the maxillary tuberosity, edentulous alveolar areas, healing bony wound, extraction sites and mental and retro-molar areas (Nasr et al. 1999, Rosenberg and Rose 1998) (Fig. 2.2).

Several types of autogenous bone grafts can be used (Rosenberg and Rose 1998; Mellonig 1992):

- (a) *Cortical bone chips* – These are not used today because they are generally much longer particles  $1,559.6 \times 183 \mu\text{m}$  and have a higher potential for sequestration (Zaner and Yukna 1984).



**Fig. 2.2** The collected bone particles were carried by sterile periosteal elevator (Tezulas et al. 2009) (Reprinted with permission from Elsevier)

- (b) *Osseous coagulum* – This is made by harvesting intraoral bone with round burns, and then mixing it with blood (Robinson 1969; Jacobs and Rosenberg 1984). Early studies in monkeys showed that small particle size (100  $\mu\text{m}$ ) led to earlier and higher osteogenic activity than did the larger particles (Rivault et al. 1971). The disadvantages in using the osseous coagulum are the patient's inability to aspirate during the collecting process, the unknown quality of the collected bone fragments, and the material's fluidity (Diem et al. 1972).
- (c) *Blend of cortical and cancellous intraoral bone* – Bone blend is the combination of cortical and cancellous bone that is procured with a trephine or rongeurs, placed in an amalgam capsule, and triturated to the consistency of a slushy osseous mass. The final particle size is about  $210 \times 105 \mu\text{m}$  (Zaner and Yukna 1984).

A technique based on the use of bone collectors for obtaining autogenous bone material, which allowed us to fill small bone defects, such as fenestrations and dehiscences, without having to involve a second (intraoral or extraoral) surgical area for obtaining autogenous bone was recently presented Blay et al. (2003).

Bone collected through bone filters appears to be sufficient for small regenerative procedures. Clinicians should bear in mind that the presence of bacterial pathogens is always shown with the use of bone collectors (Graziani et al. 2007). The stringent aspiration protocol, preoperative oral chlorhexidine rinse and antibiotic prophylaxis are important precautions to be implemented if collected bone articles will be implanted. With the

use of these methods, however, the risk of infectious complications remains. Therefore, decontamination processes are thought to only reduce microbial contamination (Tezulas and Dilek 2008). In order to overcome some of these problems, a newly developed piezoelectric device (Piezosurgery) has been recently introduced for different bone augmentation procedures. The main advantages of the piezoelectric device may be because of its modulated ultrasound microvibrations (29 kHz, ranging from 60 to 200 Hz) which should prevent damages to the adjacent soft tissues during osteotomy procedures. However, both the harvesting methods, piezoelectric device or conventional rotating drills, are not different from each other concerning their detrimental effect on viability and differentiation of cells growing out of autogenous bone chips derived from intraoral cortical sites (Chiriac et al. 2005).

### 2.1.2 Extraoral Autografts

Extraoral autografts from iliac cancellous bone and marrow provide a great osteogenic potential, being able to induce cementogenesis, bone regeneration and Sharpey's fibers reattachment (Rosen et al. 2000).

Among the biomaterials, autogenous bone has been adopted as the gold standard because: (1) autograft bone includes cells participating in osteogenesis, (2) a tissue reaction is induced without inducing immunological reactions, (3) there is a minimal inflammatory reaction, (4) there is rapid revascularization around the graft particles and (5) a potential release of growth and differentiation factors sequestered within the grafts (Marx 1994; Kim et al. 2005). Histological studies show that intraoral autografts are able to form new connective tissue attachment when implanted in intra-bony defects (Froum et al. 1983). In baboons, Cochran et al. (2003) showed that the combination of enamel matrix derivative and autogenous bone represents a therapeutic combination that can be highly effective in stimulating significant amounts of periodontal regeneration (Fig. 2.3).

In perspective, autograft bone has been considered to yield a high osteogenic potential and has thus been used with the intent to improve outcomes of periodontal regenerative procedures (Dragoo and Sullivan 1973a; Froum et al. 1975a, 1975b, 1976; Hiatt and Schallhorn 1973; Ogawa et al. 1985; Renvert et al. 1985a;

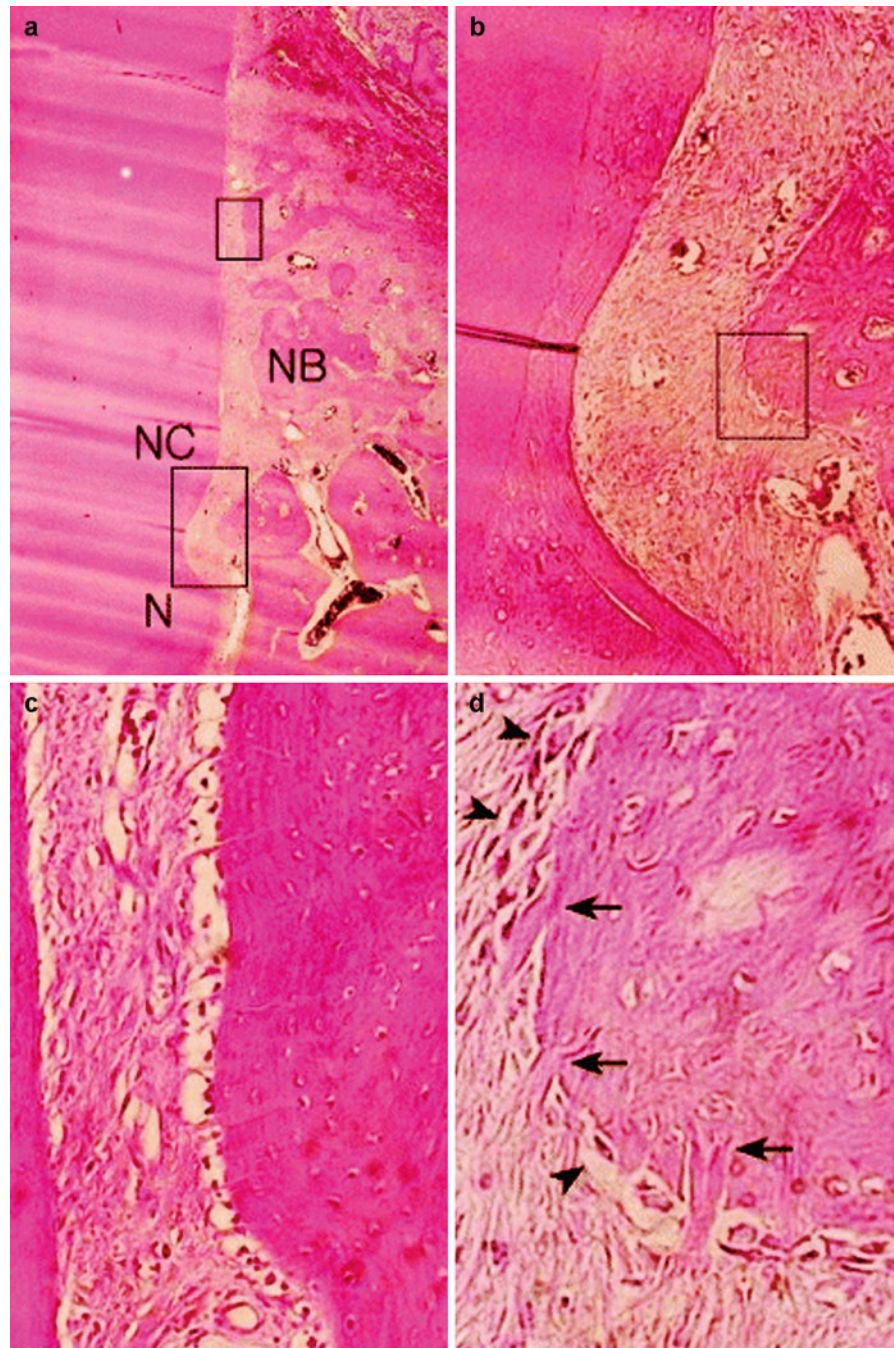
**Fig. 2.3** Periodontal healing in one-wall intrabony defects in dogs following implantation of autogenous bone.

(a) Photomicrograph of site receiving autologous bone showing new bone (NB) and cementum (NC) formation in the notch area (N) (H-E, original magnification  $\times 20$ ).

The higher magnifications show the oblique or perpendicular collagen fiber arrangement. (b) A thick layer of new cementum with an oblique or perpendicular collagen fiber arrangement was observed in the notch area (H-E, original magnification  $\times 100$ ).

(c) A well-organized periodontal ligament exhibiting a thinner new cementum layer was observed more coronally (H-E, original magnification  $\times 200$ ).

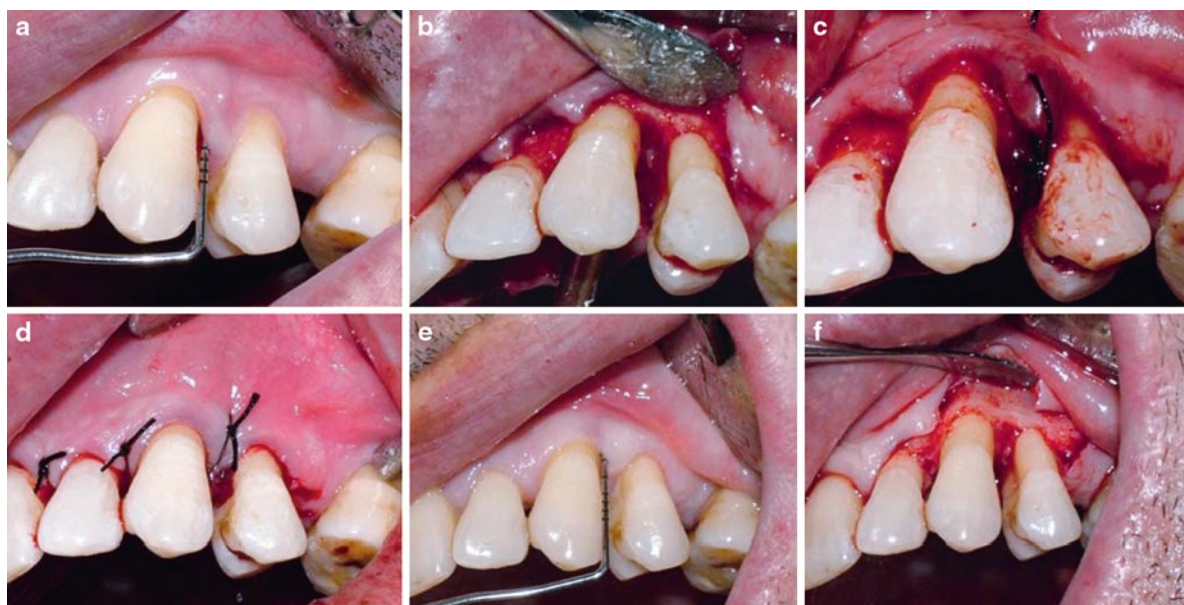
(d) Newly formed bone trabeculae were lined with osteoblast-like cells (arrowhead) and exhibited perpendicularly oriented fibers (arrows) (H-E, original magnification  $\times 400$ ) (Kim et al. 2005) (Reprinted with permission from John Wiley & Sons)



Kim et al. 2005) (Fig. 2.4). Combined therapies using autogenous bone grafts with guided tissue regeneration (GTR) (Orsini et al. 2001, 2008; Camelo et al. 2001; Nygaard-Østby et al. 2008, 2010; Lindfors et al. 2010), Emdogain (Leung and Jin 2003; Trombelli et al. 2006; Guida et al. 2007; Yilmaz et al. 2010), platelet-rich plasma (Czuryszkiewicz-Cyrana and Banach 2006) and

autogenous periodontal ligament graft (Shirmohammadi et al. 2009) in the treatment of intrabony, furcation defects or peri-implantitis have been investigated.

In the review performed by Trombelli et al. (2002), only one parallel-arm trial (Movin and Borring-Møller 1982) comparing autogenous bone grafts to open flap debridement procedure was selected. The results



**Fig. 2.4** Case from autogenous bone graft group: (a) clinical appearance of the intrabony defect at tooth 23 at the time of surgery, (b) appearance of the defect, (c) placement of the autog-

enous bone graft, (d) suturing, (e) clinical appearance at 6 months posttreatment and (f) reentry (Shirmohammadi et al. 2009) (Reprinted with permission from Springer)

indicated a greater clinical attachment level (CAL) gain for grafted group (CAL gain: 3.2 mm, SD 0.5) compared with controls (CAL gain: 2.0 mm, SD 0.8). The difference in CAL gain between groups (1.20 mm, SE 0.39) was not statistically significant. In the systematic review by Reynolds et al. (2003), two studies were included: Froum et al. (1976) and Renvert et al. (1985b). Autogenous bone treatment resulted in significantly greater clinical attachment level gain (weighted mean difference: 0.72 mm, SD 1.82) and bone fill (weighted mean difference: 1.62 mm, SD 1.53) for autogenous bone compared to open flap debridement (Table 2.1).

Although autograft procedures fulfill many of the characteristics of an ideal bone graft material, autografts are more invasive due to the additional surgical manipulations required to obtain donor tissue, and are limited by the relatively small quantity of bone that can be obtained from such techniques. These procedures also have been associated with postoperative root resorption. As a result, autografts may not be routinely practical in severe periodontitis cases involving multiple teeth and severe defects (Cohen et al. 1994). Root resorption and ankylosis in human after the transplantation of fresh iliac marrow and cancellous bone has been reported (Dragoo and Sullivan 1973b; Schallhorn and Hiatt 1972).

## 2.2 Allografts

The allografts are obtained from other individuals of the same species but disparate genotype. They include freeze-dried bone allografts (FDBA) and demineralized freeze-dried bone allograft (DFDBA). Bone allograft is the most frequently used alternative to autogenous bone for bone grafting procedures in the USA (Reynolds et al. 2010).

The two types of allografts work by different mechanisms. FDBA provides an osteoconductive scaffold and elicits resorption when implanted in mesenchymal tissues. DFDBA also provides an osteoconductive surface. In addition, it provides a source of osteoinductive factors. Therefore, it elicits mesenchymal cell migration, attachment and osteogenesis when implanted in well-vascularized bone, and it induces endochondral bone formation when implanted in tissues that would otherwise not form bone (Committee on Research, Science and Therapy of the American Academy of Periodontology 2001).

Under FDA regulations, facilities engaged in procuring and processing human tissues for transplantation must ensure that specified minimum medical screening and infectious disease testing have been performed, and that records exist and are maintained to

**Table 2.1** Mean differences (in mm) in clinical outcomes between reconstructive procedure and control (open flap debridement) procedures as assessed in systematic reviews

Reconstructive procedure	Systematic reviews	Outcome	No. of studies	Weighted mean difference (mm)	95% CI (SD) [SE]	P-value for difference	P-value for heterogeneity
GTR	Murphy and Gunsolley (2003)	CAL change	18	1.15	N/A	<0.0001	N/A
		PD change	15	1.04	N/A	<0.0001	<0.01
	Needleman et al. (2001)	CAL change	10	1.11	0.63, 1.59	*	<0.001
		PD change	5	0.80	0.14, 1.46	*	0.04
		Bone gain at re-entry	3	1.39	1.08, 1.71	*	0.65
GTR + bone substitutes	Needleman et al. (2001)	CAL change	2	1.25	0.89, 1.61	*	0.91
		PD change	2	1.24	0.89, 1.59	*	0.85
		Bone gain at reentry	1	3.37	3.14, 3.61	*	–
Autogenous bone graft	Trombelli et al. (2002)	CAL change	1	1.20	[0.39]	>0.20	–
	Reynolds et al. (2003)	CAL change	3	0.72	(1.82)	0.030	NS
		PD change	1	0.60	(1.35)	0.062	–
		Bone fill	2	1.62	(1.53)	0.058	≤0.004
Bone allograft	Trombelli et al. (2002)	CAL change	6	0.36	–0.16, 0.87	0.174	0.013
		PD change	6	0.41	0.16, 0.66	0.001	0.067
	Reynolds et al. (2003)	CAL change	11	0.44	(2.25)	0.008	NS
		PD change	9	0.43	(2.25)	0.032	NS
		Bone fill	12	1.06	(1.97)	<0.0001	NS
Dentalallograft	Trombelli et al. (2002)	CAL change	1	0.80	[0.38]	>0.50	–
Coralline calcium carbonate	Trombelli et al. (2002)	CAL change	4	0.90	0.53, 1.27	<0.001	0.104
		PD change	4	0.04	–1.78, 1.87	0.962	<0.001
	Reynolds et al. (2003)	CAL change	4	0.91	(1.94)	0.004	NS
		PD change	4	0.09	(2.16)	0.886	NS
		Bone fill	3	2.21	(1.82)	<0.0001	NS
Bioactive glass	Trombelli et al. (2002)	CAL change	4	1.04	0.31, 1.76	0.005	0.024
		PD change	4	0.60	0.20, 1.00	0.003	0.684
	Reynolds et al. (2003)	CAL change	4	1.05	(1.89)	0.022	NS
		PD change	4	0.71	(2.22)	0.018	NS
		Bone fill	4	1.61	(1.47)	0.086	0.006

**Table 2.1** (continued)

Reconstructive procedure	Systematic reviews	Outcome	No. of studies	Weighted mean difference (mm)	95% CI (SD) [SE]	P-value for difference	P-value for heterogeneity
Porous/nonporous hydroxyapatite	Trombelli et al. (2002)	CAL change	4	1.40	0.64, 2.16	<0.001	0.013
		PD change	5	0.98	0.67, 1.29	<0.000	0.070
	Reynolds et al. (2003)	CAL change	4	1.20	(2.22)	0.003	NS
		PD change	6	0.74	(2.12)	0.030	NS
		Bone fill	5	1.58	(1.77)	<0.000	≤0.04
PMMA-PHEMA	Trombelli et al. (2002)	CAL change	1	0.90	[0.22]	0.001	–
		PD change	1	0.90	N/A	0.003	–
	Reynolds et al. (2003)	Bone fill	1	1.26	N/A	0.001	–
Polylactic acid granules	Trombelli et al. (2002)	CAL change	1	–1.45	N/A	N/A	–
		PD change	1	–1.60	(0.55)	N/A	–
	Reynolds et al. (2003)	Bone fill	1	–0.28	N/A	0.519	–
Enamel matrix proteins	Trombelli et al. (2002)	CAL change	5	1.33	0.78, 1.88	<0.000	<0.001
		PD change	5	1.60	0.59, 2.62	0.002	<0.001
	Esposito et al. (2003)	CAL change	8	1.31	0.84, 1.78	<0.001	<0.001
		PD change	8	0.96	0.50, 1.41	<0.001	0.002
		Radiographic bone level	1	2.0	0.88, 3.12	<0.001	–

Source: Trombelli et al. (2005). Reprinted with permission from John Wiley & Sons

CAL clinical attachment level, CI confidence interval, GTR guided tissue regeneration, PD probing depth, PMMA-PHEMA polymethylmethacrylate and polyhydroxyethylmethacrylate, SD standard deviation, SE standard error, NS not significant

\*P values are not given for Needleman et al. (2001) because the 95% confidence interval was reported

document screening and testing for each human tissue. The American Association of Tissue Banks also sets standards, inspects facilities and accredits tissue banks in North America (Reynolds et al. 2010).

Both FDBA and DFDBA materials are widely used in periodontal therapy and there are no reports of disease transmission during the 30-year history of using freeze-dried bone allografts. Most bone banks adhere to the guidelines of the American Association of Tissue Banks (AATB) with respect to procurement, processing and sterilization of bone grafts (Centers for Disease Control and Prevention 2010). The AATB advocates excluding collection of bone under the following circumstances:

1. Donors from high-risk groups, as determined by medical testing and behavioral risk assessments
2. Donors test positive for HIV antibody by ELISA
3. Autopsy of donor reveals occult disease

4. Donor bone tests positive for bacterial contamination
5. Donor and bone test positive for hepatitis B surface antigen (HBsAG) or hepatitis C virus (HCV)
6. Donor tests positive for syphilis

The net result of human bone allograft processing is an exponential reduction in the potential for graft contamination, disease transfer or both. Initial processing of human bone allografts typically involves stripping the bone of its soft tissue and sectioning it into smaller, more manageable pieces of approximately 5 mm in diameter. After the technician has cleansed the bone of soft tissue and has decontaminated it, proprietary processing takes place via one of many paths; some tissue-processing techniques involve liquid nitrogen freezing followed by lyophilization, whereas others involve repetitious wash treatments with solvents such as acetone. Although different, these procedures

produce similar results by eliminating nearly all of the moisture content from the bone, reducing antigenicity and facilitating extremely lengthy shelf storage at room temperature. If the final product is a freeze-dried bone allograft (FDBA), processing technicians reduce the processed bone to a particle size usually ranging between 250 and 750  $\mu\text{m}$ , resample it for quality control, package it in sterile containers and may terminally sterilize it with low-dose  $\gamma$  irradiation (Table 2.2). If the final product is intended to be a demineralized freeze-dried bone allograft (DFDBA), the technician typically immerses the bone in a hydrochloric acid bath for various lengths of time to demineralize the bone by removing calcium. After acid treatment, the technician washes the newly demineralized bone allograft in

various buffer solutions to remove residual acid, rinses it to remove the buffer and terminally processes it in a fashion similar to that used for FDBA (Table 2.3).

**Table 2.2** Steps in the processing of freeze-dried bone allograft (Holtzclaw et al. 2008) (Copyright © 2008 American Dental Association. All rights reserved. Reproduced by permission)

<i>Processing step 1. Soft tissue stripping</i>
The technician removes residual muscle, tendon, ligament and so forth.
<i>Processing step 2. Initial size reduction</i>
The technician reduces the bone to pieces of approximately 5 mm diameter for easier processing.
<i>Processing step 3. Initial cleansing and decontamination</i>
The technician flushes, agitates, centrifugates or does all of these to the bone particles using various solutions such as saline, acetone, ethanol or hydrogen peroxide to remove residual bioburden and reduce antigenicity.
<i>Processing step 4. Microbiological treatment</i>
The technician treats the bone particles with antimicrobial, antimycotic and antifungal solutions.
<i>Processing step 5. Freezing</i>
The technician freezes the bone particles in liquid nitrogen of a temperature as low as $-80^{\circ}\text{C}$ .
<i>Processing step 6. Dehydration</i>
The technician lyophilizes or treats the bone particles with repetitive solvent washes to eliminate moisture content and reduce antigenicity.
<i>Processing step 7. Secondary size reduction</i>
The technician reduces the bone particles to final particulate sizes ranging between approximately 250 and 750 $\mu\text{m}$ .
<i>Processing step 8. Packaging</i>
The technician packages the bone allograft in sterile containers.
<i>Processing step 9. Terminal sterilization</i>
The technician applies low-dose $\gamma$ irradiation at low temperatures to ensure sterility (sterility assurance level, 10–6).

**Table 2.3** Steps in the processing of demineralized freeze-dried bone allograft (Holtzclaw et al. 2008) (Copyright © 2008 American Dental Association. All rights reserved. Reproduced by permission)

<i>Processing step 1. Soft tissue stripping</i>
The technician removes residual muscle, tendon, ligament and so forth.
<i>Processing step 2. Initial size reduction</i>
The technician reduces the bone to pieces of approximately 5 mm diameter for easier processing.
<i>Processing step 3. Initial cleansing and decontamination</i>
The technician flushes, agitates, centrifugates or does all of these to the bone particles using various solutions such as saline, acetone, ethanol or hydrogen peroxide to remove residual bioburden and reduce antigenicity.
<i>Processing step 4. Microbiological treatment</i>
The technician treats the bone particles with antimicrobial, antimycotic and antifungal solutions.
<i>Processing step 5. Freezing</i>
The technician freezes the bone particles in liquid nitrogen of a temperature as low as $-80^{\circ}\text{C}$ .
<i>Processing step 6. Dehydration</i>
The technician lyophilizes or treats the bone particles with repetitive solvent washes to eliminate moisture content and reduce antigenicity.
<i>Processing step 7. Secondary size reduction</i>
The technician reduces the bone particles to final particulate sizes ranging between approximately 250 and 750 $\mu\text{m}$ .
<i>Processing step 8. Demineralization</i>
The technician immerses the allograft particles in a hydrochloric acid bath at concentrations ranging from 0.5 to 0.6 normal for various lengths of time.
<i>Processing step 9. Buffering</i>
The technician again immerses the demineralized allograft particles in buffering solution to remove residual acid.
<i>Processing step 10. Final rinse</i>
The technician again rinses the demineralized allograft with various solutions (e.g., distilled water) to remove residual buffer solution.
<i>Processing step 11. Packaging</i>
The technician packages the bone allograft in sterile containers.
<i>Processing step 12. Terminal sterilization</i>
The technician applies low-dose $\gamma$ irradiation at low temperatures to ensure sterility (sterility assurance level 10–6).

Thus, rigorous donor screening and aseptic proprietary processing programs have rendered the use of human bone allografts safe and effective as a treatment option (Holtzclaw et al. 2008).

### **2.2.1 Freeze-Dried Bone Allografts (FDBA)**

FDBA, which is not demineralized, works primarily through *osteoconduction*, a process in which the graft does not activate bone growth, but instead acts like a scaffold for the patient's own natural bone to grow onto and within. Over time, the graft is resorbed and replaced by new bone (Rosenberg and Rose 1998; Nasr et al. 1999).

FDBA is also a useful material clinically. There have been no reports of virus contamination or acquired pathology from FDBA, although this material is in wide use clinically (Committee on Research, Science and Therapy of the American Academy of Periodontology 2001). It was used in the treatment of three-wall intrabony defects adjacent to implants in dogs (Choi et al. 2010), in maxillary sinus-augmentation procedures (Kolerman et al. 2008), in alveolar ridge augmentation alone (Fagan et al. 2008) or associated with platelet-rich plasma (Kassolis et al. 2000), in the treatment of periodontal defects, alone (Nevins et al. 2007; Laurell et al. 1998), combined with enamel matrix derivative (Rosen and Reynolds 2002) or with barrier membrane (Rosen and Reynolds 2001). FDBA can be combined with antimicrobial therapy, and has been used with tetracycline to regenerate experimental defects in baboons (Drury and Yukna 1991) or during treatment of localized juvenile periodontitis (Evans et al. 1989; Mabry et al. 1985). FDBA may be regarded as a graft material lacking clinically significant antigenicity (Quattlebaum et al. 1988).

### **2.2.2 Demineralized Freeze-Dried Bone Allografts (DFDBA)**

Demineralization of a bone allograft exposes bone morphogenetic proteins within the bone matrix. These inductive proteins induce a cascade of events leading to cellular differentiation and the formation of bone

through osteoinduction by inducing pluripotential stem cells to differentiate into osteoblasts (Mellonig et al. 1992; Nasr et al. 1999).

It is important to evaluate the methods, procurement, processing and particle size of the demineralized freeze-dried bone allograft used in a study. When DFDBA is used in particulate form, *particle size appears to be an important variable in the success of DFDBA as a bone-inductive material*. Particles in the range of 125–1,000  $\mu\text{m}$  possess a higher osteogenic potential than do particles below 125  $\mu\text{m}$ . Optimal particle size appears to be between 100 and 300  $\mu\text{m}$ . This may be due to a combination of surface area and packing density. Very small DFDBA particles elicit a macrophage response and are rapidly resorbed with little or no new bone formation. Tissue banks providing DFDBA for dental use will usually have this graft material in various particle sizes, and the range from 250 to 750  $\mu\text{m}$  is the most frequently available (Committee on Research, Science and Therapy of the American Academy of Periodontology 2001). Schwartz et al. (1996) had shown a wide variation in commercial bone bank preparation of demineralized freeze-dried bone allograft and the ability to induce new bone formation. Particle size before implantation correlated with particle size after implantation. However, particle size did not correlate with ability to induce bone. The results show that commercial DFDBA differs in both size and ability to induce new bone formation, but that the two are not related.

*Donor variability, however, also limits the predictability of DFDBA as an osteoinductive material* (Boyan et al. 2006). The ability to induce bone appears to be age dependent, with DFDBA from older donors being less likely to have strong bone-inducing activity (Schwartz et al. 1998a).

*The degree of DFDBA demineralization varies between tissue banks and may also affect clinical regeneration*. A 2% residual calcium level in DFDBA has been shown to result in the highest alkaline phosphatase activity levels in cultured human periosteal cells and is optimally osteoinductive or osteoconductive for new bone formation (Herold et al. 2002).

*Histological studies* in humans performed by Bowers et al. (1989a, 1989b) revealed the formation of new attachment apparatus in intrabony defects grafted with DFDBA. At this time, demineralized freeze-dried bone allograft remains the only bone replacement graft proven to result in periodontal regeneration in a

controlled human histological study and is recognized in the consensus report by the 1996 World Workshop in Periodontics to fulfill all criteria considered for the promotion of periodontal regeneration (Nasr et al. 1999). The ability of demineralized bone to induce new bone formation in soft tissues and to enhance bone formation in osseous tissues is believed to be due to the content and diffusibility of bone morphogenetic proteins (BMPs) present in the material (Lohmann et al. 2001). The BMPs and other growth factors and cytokines interact with mesenchymal stem cells or undifferentiated osteogenic precursors in the host tissue, causing them to differentiate into bone-forming cells (Li et al. 2000; Lohmann et al. 2001; Schwartz et al. 1998b). Several other growth factors were identified: FGF $\alpha$  (fibroblast growth factor), IGF-I (insulin-like growth factor-beta1), TGF- $\beta$ 1 (transforming growth factor-beta1), VEGF (vascular endothelial growth factor) and PDGF (platelet-derived growth factor) (Wildemann et al. 2007).

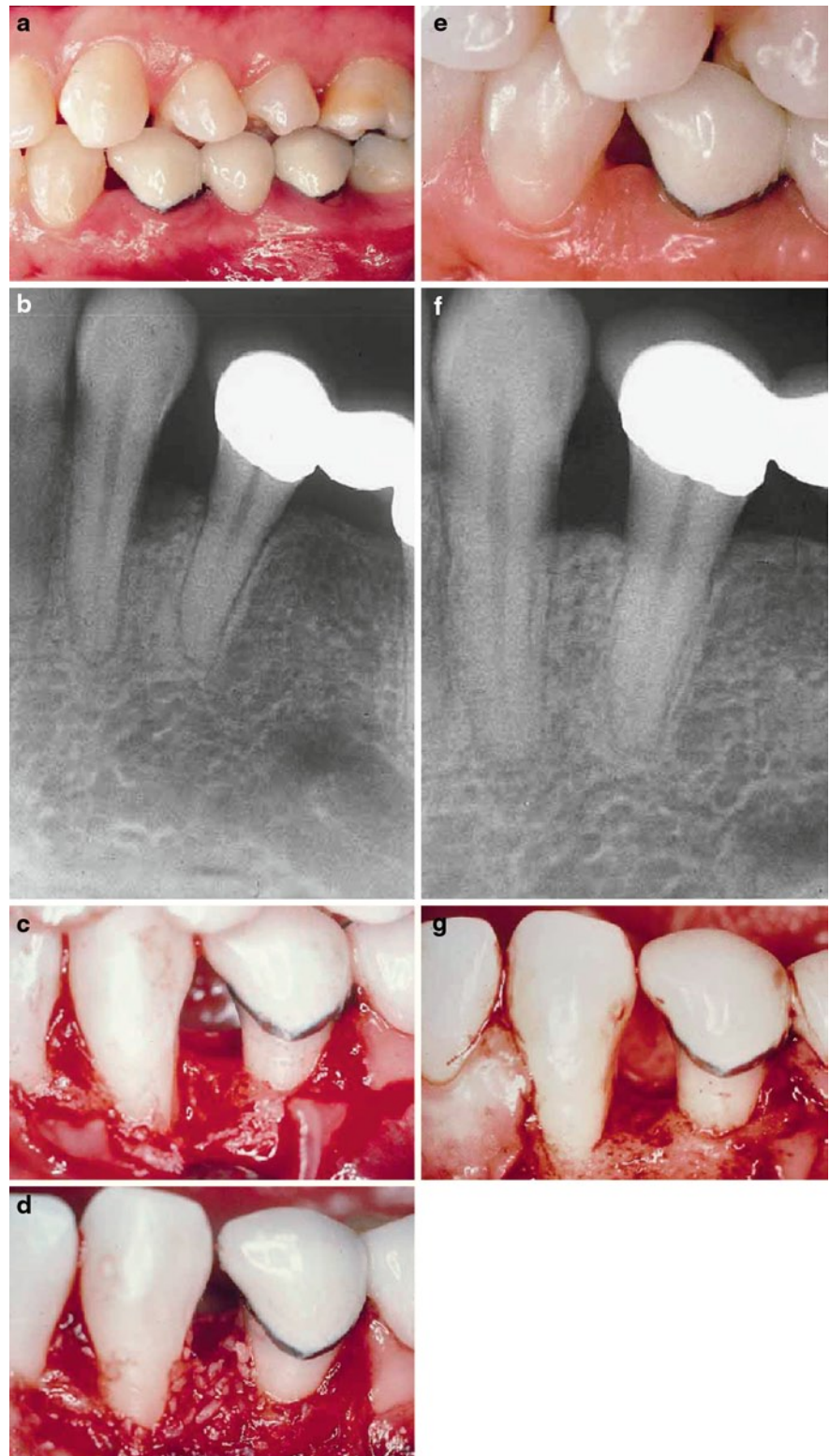Six studies (Altiere et al. 1979; Blumenthal and Steinberg 1990; Borghetti et al. 1993; Flemmig et al. 1998; Masters et al. 1996; Yukna et al. 1998) comparing *bone allograft with open flap debridement* (OFD) procedure were included and pooled for meta-analysis by Trombelli et al. (2002). The results showed a limited, not statistically significant, greater CAL gain for grafted group with respect to OFD. Weighted mean difference between grafted and control was 0.36 mm (95% CI: -0.16 to 0.87; Q-test for heterogeneity, 14.40 (df=5),  $P=0.01$ ). A significantly greater probing depth reduction was reported for bone allograft treatment: 0.41 mm (95% CI: 0.16–0.66) compared to OFD. Meta-analysis performed by Reynolds et al. (2003) on 12 studies (Altiere et al. 1979; Blumenthal and Steinberg 1990; Borghetti et al. 1993; Brown et al. 1998; Flemmig et al. 1998; Mabry et al. 1985; Masters et al. 1996; Meadows et al. 1993; Mellonig 1984; Mora and Ouhayoun 1995; Schrad and Tussing 1986; Yukna et al. 1998) showed a greater clinical attachment level gain for the grafted group with respect to OFD. Weighted mean difference between graft and control was 0.44 mm (SD 2.25). Adjunctive defect fill amounted to 1.06 mm (SD 1.97) with the use of bone allograft. A significantly greater probing depth reduction was reported for bone allograft treatment 0.43 mm, SD 2.25 compared to OFD (Fig. 2.5).

It may be possible to enhance the amount of bone fill obtained with bone replacement grafts such as DFDBA by combining regenerative therapies (Hanes 2007). *The use of replacement grafts (DFDBA) in an aim to improve the results of GTR therapy* for the treatment of intrabony or mucogingival defects was evaluated by several studies (Chen et al. 1995; Trejo et al. 2000; Lamb et al. 2001; Duval et al. 2000; Wang et al. 2002; Couri et al. 2002; Bowers et al. 2003; Kimble et al. 2004; Aichelmann-Reidy et al. 2004; Kothiwale et al. 2009). In studies where demineralized freeze-dried bone has been combined with barriers of cross-linked bovine collagen or expanded polytetrafluoroethylene membranes, the results tend to indicate that combined therapy is also a successful therapeutic approach (Rosen et al. 2000).

*Recent studies suggest that the addition of enamel matrix derivative (EMD) to demineralized freeze-dried bone allograft may enhance osteoinduction* (Boyan et al. 2000, 2006; Rosen and Reynolds 2002; Gurinsky et al. 2004; Harris et al. 2007; Hoidal et al. 2008; Aspriello et al. 2010). Venezia et al. (2004) concluded that EMD combination with allograft materials may be of additional benefit but still needs to be further investigated. Emdogain is composed primarily of amelogenin and other proteins present in embryonic porcine tooth germs. It is possible that a trace component of Emdogain possesses osteoinductive properties. During embryonic development, the interaction of epithelial and mesenchymal tissues is critical for tissue morphogenesis. It was suggested that Emdogain ability to enhance the osteoinductivity of DFDBA is the result of its properties as a bioactive matrix. Emdogain also delayed the rate at which DFDBA was resorbed, suggesting that factors present in this complex agent might modulate bone remodeling in addition to bone formation (Boyan et al. 2006). In contrast with previous results, it was also reported that DFDBA combined with EMD compared to DFDBA alone in the treatment of intraosseous defects of chronic periodontitis provided no statistically significant improvement to the soft and hard tissue parameters measured (Hoidal et al. 2008).

*Several authors have investigated the impact of growth factors to demineralized freeze-dried bone allograft (DFDBA)* (Bowers et al. 1991; Danesh-Meyer et al. 2001; Mott et al. 2002; Markopoulou

**Fig. 2.5** (a) Preoperative view of the mandibular left canine in a 39-year-old Caucasian woman. The patient is a nonsmoker. (b) Preoperative radiograph suggests that there is an intrabony lesion at the distal of the left premolar. (c) Full-thickness flap reflection reveals a combination two- and three-wall lesion. (d) After root planing, scaling, citric acid root surface treatment and intramarrow penetration, demineralized freeze-dried bone allograft is placed to fill the entire defect. (e) View of the site at 48 months postsurgery. There has been some loss in height of the interdental papilla. (f) Postoperative radiograph taken at 48 months suggests complete bone fill of the defect at the distal of the canine. (g) Reentry performed at 48 months postsurgery shows hard tissue fill of the defect. There has been a slight loss of facial bone on the cuspid (Rosen et al. 2000) (Reprinted with permission from John Wiley & Sons)



et al. 2003; Camelo et al. 2003; Papadopoulos et al. 2003; Nevins et al. 2003a, 2007; Dereka et al. 2006, 2009; ; Markou et al. 2009, 2010). It has been showed that addition of BMP-2 increased osteoinduction of DFDBA by almost 50% based on the bone induction score (Boyan et al. 2006). DFDBA contains BMP-2, but the amount seems to vary among individuals. Moreover, the formatting of BMP-2 within DFDBA is different from that of BMP-2 adsorbed to the surface of the graft particles. Studies suggest that the DFDBA particles must be resorbed for the BMP contained within the matrix to be released. DFDBA becomes, in effect, a time-release carrier for these factors. Surface-adsorbed BMP-2 is released in a burst and, as a result, has its greatest effects on cells present at the implant site. Thus, the two forms of the morphogen work on distinctly different cell populations, and the combined effect is additive, if not synergistic. Other factors present in DFDBA also may contribute to the overall tissue response (Boyan et al. 2006). The evaluation of the effect of a combination of BMPs with a graft/bone substitute relates to one single histomorphometric study in humans where the association of BMP-3 (osteogenin) and two different biomaterials (purified bovine collagen and DFDBA) has been evaluated (Bowers et al. 1991). Test treatments consisted of the association of BMP-3 with DFDBA or bovine collagen; control groups consisted of the grafts used alone. Histologic evaluation at 6 months indicated that osteogenin combined with DFDBA significantly enhanced regeneration of a new attachment apparatus and component tissues in a submerged environment. DFDBA plus osteogenin and DFDBA alone formed significantly more new attachment apparatus and component tissues than either the tendon-derived matrix plus osteogenin or the tendon-derived matrix alone in both submerged and nonsubmerged environments. There were no significant differences between the tendon-derived matrix plus osteogenin and the tendon-derived matrix alone in either the submerged or nonsubmerged environment (Bowers et al. 1991). The combination of BMPs and allograft is a promising step forward in improving allograft treatment. As the number of allograft procedures performed per year increases worldwide, the outcome for many could be influenced by the addition of BMPs. Still, safety concerns as well as availability

of allograft is a continuous source of inspiration for those investigating alternative bone sources (Blokhuis and Lindner 2008).

Osteoblast proliferation rates indicate that the in vitro supplementation of 2% residual calcium-DFDBA with the combination of insulin-like growth factor (IGF) and transforming growth factor- $\beta$  (TGF- $\beta$ ), IGF and platelet-derived growth factor (PDGF), and PDGF and TGF- $\beta$  significantly ( $P \leq 0.05$ ) enhances murine osteoblast activity and proliferation at 7 days compared with the control containing no exogenous growth factors (Mott et al. 2002). In contrast with these reports and to the increase in osteoinduction seen when DFDBA is implanted with BMP-2 or Emdogain, PDGF and PRP reduced osteoinductivity by approximately 20%. The inhibitory effect of PDGF-BB on DFDBA-induced bone formation is concentration dependent and, at high concentrations, causes the chondrogenic phase of endochondral bone formation to persist. At low concentrations, PDGF-BB does not inhibit DFDBA activity and, in an orthotopic site where other osteogenic signals are present, its effect on mesenchymal cell proliferation may result in increased bone formation (Boyan et al. 2006). Nevins et al. (2003a) revealed a robust regeneration of a complete new attachment apparatus, including bone, periodontal ligament and cementum in human interproximal intrabony defects and molar Class II furcation lesions following the application of purified recombinant human platelet-derived growth factor BB (rhPDGF-BB) incorporated in demineralized freeze-dried bone allograft (DFDBA) (Nevins et al. 2003a). In a randomized, double-masked, clinical trial, Piemontese et al. (2008) compared platelet-rich plasma (PRP) combined with a demineralized freeze-dried bone allograft (DFDBA) to DFDBA mixed with a saline solution in the treatment of human intrabony defects. No statistically significant differences were observed in the hard tissue response between the two treatment groups, which confirmed that PRP had no effect on hard tissue fill or gain in new hard tissue formation. It was recently demonstrated that both PRP and PRP combined with DFDBA resulted in significant clinical and radiographic improvement in human periodontal endosseous defects at 6 and 12 months (Piemontese et al. 2008; Markou et al. 2009, 2010), and the addition of DFDBA to PRP did not significantly enhance the treatment outcome

(Markou et al. 2009). A recent randomized, double-masked, clinical trial compared platelet-rich plasma (PRP) combined with a demineralized freeze-dried bone allograft (DFDBA) to DFDBA mixed with a saline solution in the treatment of human intrabony defects. The test group (PRP+DFDBA) exhibited statistically significantly greater changes compared to the control group in probing depth reduction ( $4.3 \pm 1.7$  mm versus  $2.6 \pm 2.2$  mm;  $P < 0.05$ ) and clinical attachment gain ( $3.5 \pm 2.1$  mm versus  $2.3 \pm 2.4$  mm;  $P < 0.001$ ). No statistically significant differences were observed in the hard tissue response between the two treatment groups (Piemontese et al. 2008).

Demineralized bone matrix is produced by acid extraction of allograft. It contains type-1 collagen, non-collagenous proteins and osteoinductive growth factors. There are numerous demineralized bone matrix formulations based on refinements of the manufacturing process. They are available as freeze-dried powder, granules, gel, putty or strips. They have also been developed as combination products with other materials such as allogeneic bone chips and calcium sulfate granules (De Long et al. 2007). Demineralized bone matrix paste and putty are particulate demineralized bone matrices in a 2% or 4% hyaluronate carrier, respectively. When compared with demineralized freeze-dried bone allografts, all demonstrated similar favorable improvements in soft and hard tissue parameters in the treatment of human intraosseous defects (Bender et al. 2005).

Examples of commercially available products are Grafton® DBM (Osteotech, Inc. American Association of Tissue Banks), Grafton Plus® DBM Paste (Osteotech, Inc. American Association of Tissue Banks), Osseograft (Advanced Biotech Products (P) Ltd. India), Accell Connexus™ (Accell® technology +DBM particles+reverse phase medium for optimal handling) (IsoTis Orthobiologics/GenSci Regeneration Technologies), Accell® DBM100® (Accell® technology+DBM particles in putty) (IsoTis Orthobiologics/GenSci Regeneration Technologies), DBX® Demineralized Bone Matrix (Musculoskeletal Transplant Foundation, USA), Dynagraft putty (Gen-Sci, Regeneration Laboratories, CA) and Osteofil allograft bone paste (Regeneration Technologies, FL). Regenafil®, Altiva DBM Paste, BioSet™, RTI Allograft Paste and Osteofil® contain human demineralized freeze-dried bone allograft (DFDBA, also known as demineralized

bone matrix, DBM) in an inert porcine gelatin carrier. Regenafil®, Altiva DBM with cortical cancellous chips, BioSet™ IC, RTI Allograft Paste IC and Osteofil® ICM contain human DFDBA and human cortical-cancellous bone chips in an inert porcine gelatin carrier. Regenafil and Regenafil Frozen Allograft Paste should be stored frozen. It may be stored for 6 months at  $-20$  to  $-40^\circ\text{C}$  (conventional freezer) or up to 5 years if stored at  $-40^\circ\text{C}$  or colder (see expiration date on label). Regenafil and Regenafil Frozen Allograft Paste must be warmed prior to use. Detailed instructions for warming the graft are included in the package insert that accompanies each graft (<http://www.exac.com/products/dental-biologics>).

The decision about which form of allograft to use should be based on the clinical condition of the site to be grafted. Because it is still mineralized, FDBA may have better physical characteristics. However, FDBA is not osteoinductive. Although no significant differences have been found clinically between FDBA and DFDBA in primarily intraosseous defects (Piattelli et al. 1996a; Rummelhart et al. 1989; Francis et al. 1995) in sites where regeneration may be more problematic, DFDBA may be a more appropriate choice (Committee on Research, Science and Therapy of the American Academy of Periodontology 2001). However, recent histological study suggested that FDBA may stimulate earlier, more rapid and more substantial new bone formation than DFDBA in a monkey jaw defect model system (Yukna and Vastardis 2005). A trend was observed toward greater improvement in clinical attachment level gain in advanced infrabony defects when EMD was combined with FDBA ( $57.3\% \pm 9.4\%$ ) as compared to DFDBA ( $49.1\% \pm 11.0\%$ ) (Rosen and Reynolds 2002).

### 2.3 Xenografts

Xenografts are grafts shared between different species. Currently, there are two available sources of xenografts used as bone replacement grafts in periodontics: bovine bone and natural coral. Both sources, through different processing techniques, provide products which are biocompatible and structurally similar to human bone. Recently, porcine bone xenografts have also been described. Xenografts are osteoconductive, readily

available and risk free of disease transmission. The latter point has been questioned with the discovery of bovine spongiform encephalopathy, particularly in Great Britain (Nasr et al. 1999).

### **2.3.1 Anorganic Bovine-Derived Bone Xenograft (BDX)**

The BDX is a xenograft consisting of deproteinized, sterilized bovine bone with 75–80% porosity and a crystal size of approximately 10  $\mu\text{m}$  in the form of cortical granules (Hürzeler et al. 1997; Piattelli et al. 1999). Regarding both the chemical and physical features, BDX is considered identical to the human bone (Berglundh and Lindhe 1997; Piattelli et al. 1999).

BDX has several characteristics and advantages when compared with freeze-dried demineralized bone: no donor site is required from the patients; unlimited supplies of the material are available; the material is easily handled and used as freeze-dried demineralized bone; and the results are predictable when good surgical principles are observed, a sterile environment is maintained and tissue is handled properly as recommended by the manufacturer (Callan et al. 1993).

Xenografts are bovine in origin and carry the theoretical risk of transmission of bovine spongiform encephalopathy (Precheur 2007). Several studies, however, indicate that the use of these materials does not carry a risk for transmitting bovine spongiform encephalopathy (BSE) to humans (Hönig et al. 1999; Wenz et al. 2001; Precheur 2007). Sogal and Tofe (1999) conducted an extensive review of current literature on the status of risk assessment of BSE transmission and two risk assessment models were identified as applicable to the present study. Risk assessment models developed by the German Federal Ministry of Health and by the Pharmaceutical Research and Manufacturers Association of America were applied to BGS. Results from the analyses conducted using both models showed that the risk of disease (BSE) transmission from BGS was negligible and could be attributed to the stringent protocols followed in sourcing and processing of the raw bovine bone used in the commercial product.

Several histological studies in animals and humans have revealed that BDX possesses excellent

osteoconductive properties (Berglundh and Lindhe 1997; Skoglund et al. 1997; Camelo et al. 1998, 2001; Hämmerle et al. 1998; Mellonig 2000; Zitzmann et al. 2001; Paolantonio 2002; Nevins et al. 2003a, 2003b; Sculean et al. 2003b, 2004a). The large-mesh interconnecting pore system facilitates angiogenesis and migration of osteoblasts (Orsini et al. 2005). Several histological studies have shown that BDX particles were surrounded for the most part by mature, compact bone. In some Haversian canals, it was possible to observe small capillaries, mesenchymal cells and osteoblasts in conjunction with new bone. No gaps were present at the interface between the BDX particles and newly formed bone, the BDX granules being interconnected by bridges of vital newly formed bone (Piattelli et al. 1999; Tadjoeidin et al. 2003). With time, BDX becomes integrated and subsequently replaced by newly formed bone (Berglundh and Lindhe 1997). In histological specimens retrieved after 18 months and 4 years, it was possible to observe the presence of osteoclasts in the process of resorbing the BDX particles and neighboring newly formed bone (Piattelli et al. 1999). It has been reported that BDX has a very low resorption rate (Valentini and Abensur 1997). However, how this biomaterial enhances osteoblast activity to promote bone formation is not completely understood. MicroRNAs (miRNAs) represent a class of small, functional, noncoding RNAs of 19–23 nucleotides that regulate the transcription of messenger RNAs (mRNAs) in proteins. The miRNA microarray technique was used to investigate translation regulation in an osteoblast-like cell line (MG63) exposed to Bio-Oss. It was showed that the vast majority of detected mRNAs were downregulated, including some homeobox genes (genes that regulate the morphogenesis of an entire segment of the body), such as *noggin* and *EN1*. An indirect positive effect was demonstrated on bone morphogenetic protein-4 (Palmieri et al. 2010). It was indicated that BDX and Perioglas act on different miRNAs. Globally, Perioglas causes activation of bone-forming signaling, whereas BDX also activates cartilage-related pathways (Annalisa et al. 2008).

Because all the protein is removed, this 100% crystalline hydroxyapatite grafting material is considered biocompatible (Cohen et al. 1994; Callan et al. 1993), is very well tolerated, and, until now, no adverse reactions such as allergies or rejection of the graft particles related to the material have been reported (Camelo et al. 1998; Richardson et al. 1999;

Camargo et al. 2000; Mellonig 2000; Zitzmann et al. 2001; Sculean et al. 2003, 2004a, 2004b, 2005a, 2005b, 2007b; Tonetti et al. 2004; Liñares et al. 2006). However, recently, Bannister and Powell (2008) presented an unusual reaction to BDX after a ridge augmentation by a mixture of autogenous bone and anorganic bovine bone with platelet-rich plasma and a bioabsorbable collagen membrane. Healing was uneventful, although after 4 months, upon flap reflection, no regenerated hard tissue was found. At the histologic examination, it was observed that the majority of the graft material demonstrated an intimate association with multinucleated foreign body-type giant cells. However, at the second procedure, the site was regrafted with an allograft/xenograft mixture and covered by a bioabsorbable collagen membrane and wound healing was uneventful.

BDX has demonstrated efficacy for:

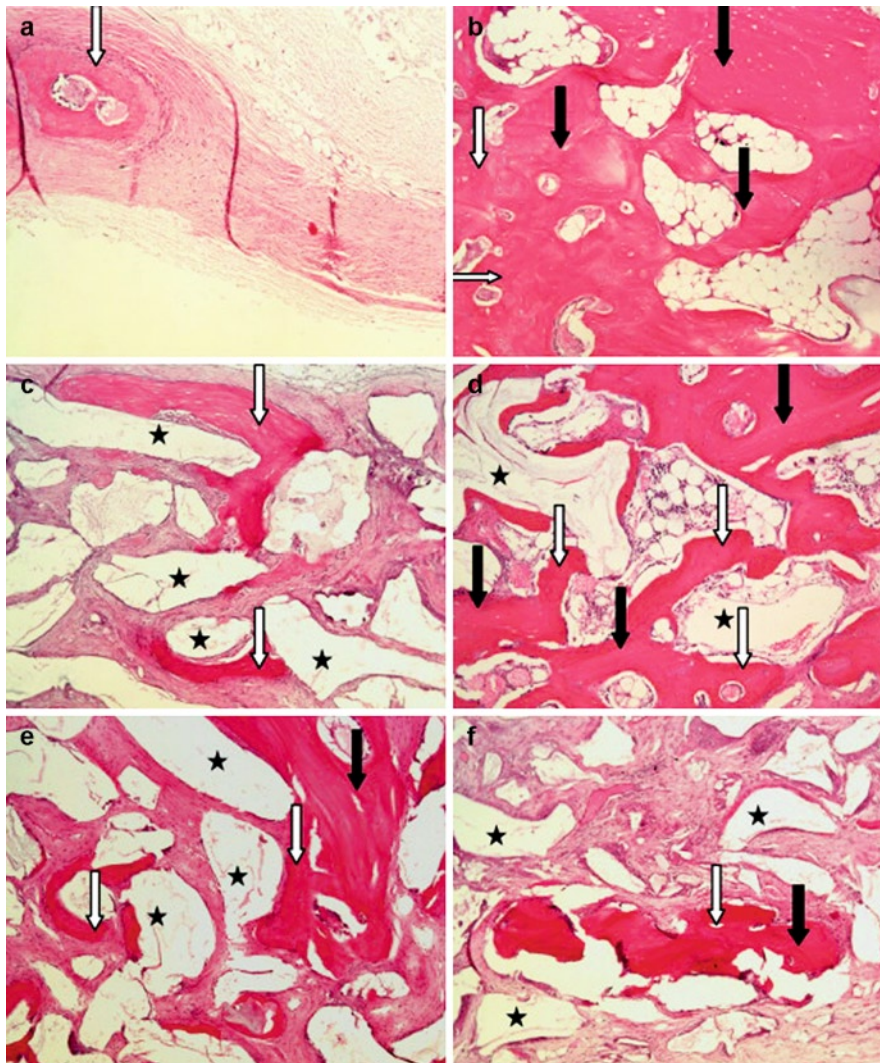
- *Reconstruction of atrophied alveolar ridges* (Callan and Rohrer 1993; Artzi and Nemcovsky 1998; Zitzmann et al. 2001; Kotschy and Laky 2006; Esposito et al. 2006; Cardaropoli et al. 2005; Lang et al. 2007)
- *Around endosseous implants* (Berglundh and Lindhe 1997; Skoglund et al. 1997; Zitzmann et al. 1997; Hämmerle et al. 1998; Schlegel and Donath 1998; Juodzbaly and Wang 2007)
- *Sinus elevation floor procedures* (Valentini et al. 1998, 2000; Valentini and Abensur 2003; Piattelli et al. 1999; Hallman et al. 2001; Wallace and Froum 2003; Orsini et al. 2005; Handschel et al. 2009; Bornstein et al. 2008; Beloti et al. 2008)
- *Healing of intrabony peri-implantitis defects* (Schou et al. 2003; Schwarz et al. 2006a, 2008, 2009; Esposito et al. 2008)
- *Periradicular surgery in large periapical lesions* (Dietrich et al. 2003; Taschieri et al. 2007)
- *Periodontal bone defects* where BDX has been evaluated when used alone (Hutchens 1999; Richardson et al. 1999; Scheyer et al. 2002; Scabbia and Trombelli 2004; Gupta et al. 2007), in association with membranes (Hutchens 1999; Camelo et al. 1998, 2001; Camargo et al. 2000; Simonpietri-C et al. 2000; Paolantonio et al. 2001; Pietruska 2001; Paolantonio 2002; Sculean et al. 2003, 2004a, 2005a, 2007b; Stavropoulos and Karring 2005;

Stavropoulos et al. 2003; Stavropoulos et al. 2004; Vouros et al. 2004; Tonetti et al. 2004; Reddy et al. 2006; Sakata et al. 2006; Liñares et al. 2006) and in combination with enamel matrix protein derivative (Lekovic et al. 2000; Lekovic et al. 2001; Scheyer et al. 2002; Velasquez-Plata et al. 2002; Zucchelli et al. 2003; Sculean et al. 2002b, 2004b)

A composite of autogenous bone and bone substitute is widely used in oral surgery procedures because it combines the osteogenic property of autogenous bone and the osteoconductive property of BDX (Fig. 2.6). It contains osteogenic cells and provides a scaffold and internal pores for bone cells to grow and remineralize to new bone. The relative proportions of autogenous bone and bone substitute vary (Pripatnanont et al. 2009). A systematic review recommended a proportion of 1:2 (Merckx et al. 2003). Pripatnanont et al. (2009) assessed new bone formation generated using three different proportions of autogenous bone (AB) and deproteinized bovine bone (BDX) in cortical skull defects in rabbits. The 1:2 group had significantly higher bone content than the 1:4 group. The proportions of 1:1 and 1:2 resulted in greater bone formation than the proportion of 1:4 (Pripatnanont et al. 2009). In deep intrabony defects treatment, at 12 months evaluation, the combined use of autogenous spongiosa with bovine-derived xenograft led to significantly greater gain of clinical attachment and hard tissue formation compared to the use of autogenous spongiosa alone (Zafropoulos et al. 2007).

Examples of commercially available bovine-derived bone replacement grafts are Bio-Oss® (Osteohealth Co., Shirley, NY), Bio-Oss Collagen® (Osteohealth Co., Shirley, NY), OsteoGraf/N® (CeraMed Dental, LLC, Lakewood, CO) and PepGen P-15® (Dentsply Friadent, Mannheim, Germany) (Sukumar and Drízhal 2008).

*Bio-Oss*® (Osteohealth Co., Shirley, NY) is a natural, nonantigenic, porous bone mineral matrix. It is produced by the removal of all organic components from bovine bone (Fig. 2.7). It is available in cancellous (spongiosa) and cortical granules and blocks. Bio-Oss undergoes a low-heat (3,000°C) chemical extraction process by which all organic components are removed, but maintains the natural architecture of bone (Richardson et al. 1999). This material is essentially



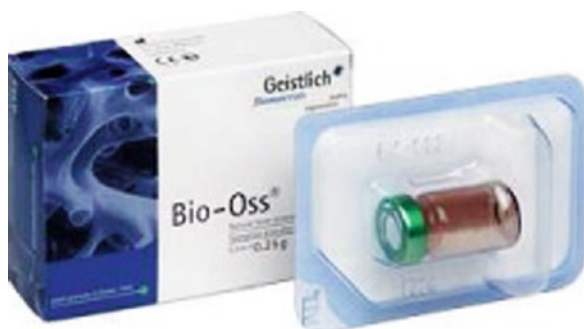**Fig. 2.6** Proportion of deproteinized bovine bone and autogenous bone affects bone formation in the treatment of calvarial defects in rabbits: (a) a critical size defect, (b) an autogenous bone chip, (c) BDX alone, (d) a composite graft of autogenous bone and BDX at 1:1 ratio, (e) a composite graft of autogenous bone and

BDX at 1:2 ratio, (f) a composite graft of autogenous bone to BDX at 1:4 ratio. *White arrows* indicate new bone, *black arrows* indicate bone chips, *black stars* indicate BDX particles (Hematoxylin and Eosin, original magnification  $\times 10$ ) (Pripatnanont et al. 2009) (Reprinted with permission from Elsevier)


carbonate-containing apatite with few hydroxyl groups, and possesses a crystalline architecture and calcium:phosphate ratio similar to natural bone mineral in humans (Cohen et al. 1994). Due to its natural structure Bio-Oss is physically and chemically comparable to the mineralized matrix of human bone (Fig. 2.8). Chemically, Bio-Oss is a low crystalline apatite (crystallite size of approximately  $100 \times 200 \times 500 \text{ \AA}$ ) with a

7% content of carbonate (Benke et al. 2001). The infrared spectra and X-ray diffraction patterns show a calcium content of  $37.1 \pm 0.7\%$  and a phosphorous content of  $17.8 \pm 0.5\%$ , corresponding to a Ca-P ratio of  $2.1 \pm 0.1$  (Jensen et al. 1996; Scabbia 2004 Sculean et al. 2007b).

*Bio-Oss Collagen*<sup>®</sup> (Osteohealth Co., Shirley, NY) consists of Bio-Oss Spongiosa granules (0.25–1 mm)



**Fig. 2.7** Bio-Oss® (Osteohealth Co., Shirley, NY)

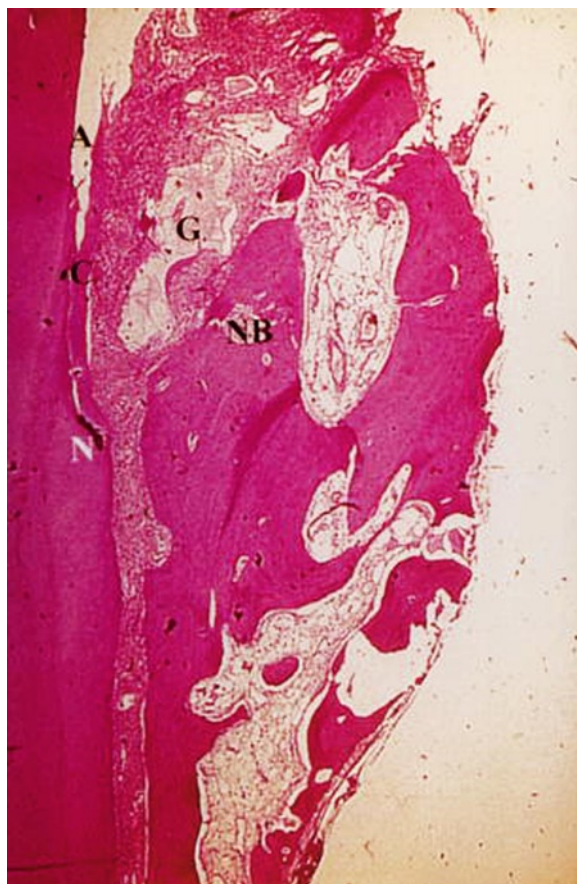

**Fig. 2.8** SEM photographs of deproteinized bovine bone (DBB) granules showing the pore structure, size 200–500 µm (original magnification, ×400) (Pripatnanont et al. 2009) (Reprinted with permission from Elsevier)

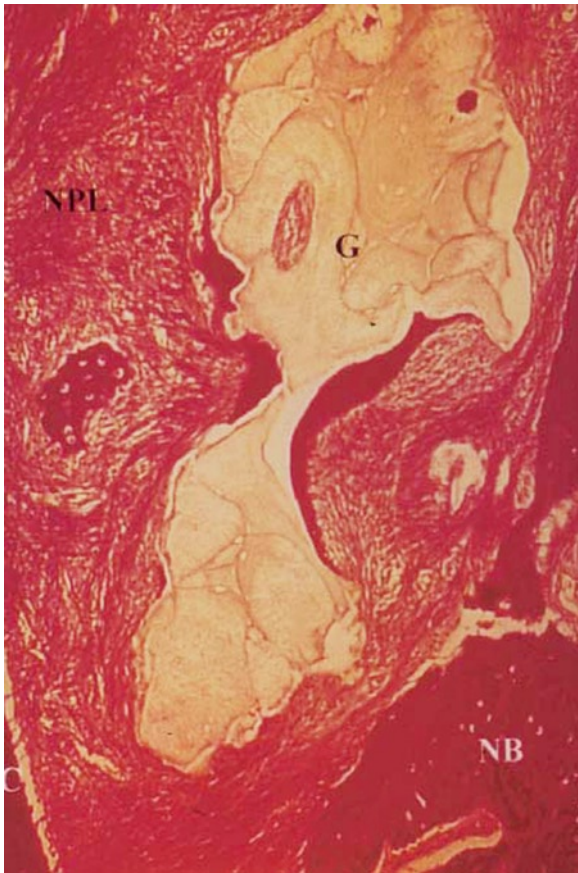with the addition of 10% highly purified porcine collagen. As with Bio-Oss, the mineral structure of Bio-Oss Collagen is highly porous, possesses a large internal surface area and functions as a scaffold for bony ingrowth. The collagen component enables convenient handling and simple application but does not function as a barrier. The collagen component allows Bio-Oss Collagen to be easily adapted into the defect. The cohesion of the particles is ensured, even without a membrane. The collagen component is resorbed within 4–6 weeks (<http://www.ostehealth.com>). Bio-Oss Collagen has the capacity to facilitate regeneration of the periodontal attachment apparatus when placed in intrabony defects (Nevins et al. 2005b). No differences in the histological findings were observed following treatment of human intrabony defects with either a bovine-derived xenograft and GTR or a bovine-derived

xenograft mixed with collagen and GTR. Healing was characterized by the formation of new cementum, new periodontal ligament and new bone (Figs. 2.9 and 2.10). Most of the graft particles were surrounded by bone, which in turn points to the highly osteoconductive potential of the graft material (Sculean et al. 2004a).

*OsteoGraf/N*® (CeraMed Dental, LLC, Lakewood, CO) is a pure, natural form of hydroxylapatite, the major mineral component of tooth enamel and bone. OsteoGraf/N is completely biocompatible and remodels to vital bone at the same rate as host bone.



**Fig. 2.9** Healing of human intrabony defects following regenerative periodontal therapy with a bovine-derived xenograft and guided tissue regeneration. Representative histologic view of a healing following treatment with bovine-derived xenograft (BDX) Collagen + guided tissue regeneration (GTR). The healing occurred in formation of new cementum with inserting collagen fibers (C) and new bone (NB) coronally to the notch (N) in the root surface. BDX (G) particles are surrounded by bone. A artifact (Original magnification ×50; van Giesson's connective tissues stain) (Sculean et al. 2004a) (Reprinted with permission from Springer)



**Fig. 2.10** Healing of human intrabony defects following regenerative periodontal therapy with a bovine-derived xenograft and guided tissue regeneration. High-power magnification of the regenerated area shown in Fig. 2.9. Bovine-derived xenograft (BDX) particle (G) is surrounded by bone. C new cementum, NPL new periodontal ligament, NB new bone (Original magnification  $\times 250$ ; van Giesson's connective tissues stain) (Sculean et al. 2004a) (Reprinted with permission from Springer)

OsteoGraf/N is the only xenograft that meets all ASTM standards for “Composition of Anorganic Bone for Surgical Implants (F1581-95).” The product is hydrophilic – cohesive consistency when hydrated. It is manufactured as radiopaque, rounded particles and is available in two particle sizes:


- OsteoGraf/N-300 (250–420  $\mu\text{m}$ ) packaged in 1-g and 3-g vials
- OsteoGraf/N-700 (420–1,000  $\mu\text{m}$ ) packaged in 1-g and 3-g vials

A unique regenerative product is *PepGen P-15*<sup>®</sup> (Dentsply Friadent, Mannheim, Germany), a calcined bovine bone (1,100°C; hydroxyapatite) coated with a pentadecapeptide (P-15, a part of the sequence of collagen). It is available as granulate with a particle size of 0.25–0.42  $\mu\text{m}$  and used in dental applications (Tadic and Epple 2004). The product is described in more detail in Chap. 5.

### 2.3.2 Anorganic Porcine-Derived Bone Xenograft

A natural replicate of autologous bone, OsteoBiol<sup>®</sup> Gen-Os (TecnoDental, Turin, Italy) conserves the same intimate structures (matrix and porous form) and presents a high osteoconductive activity (Fig. 2.11). It is biocompatible and bioavailable, as recognized by tests made according to the ISO 10993 method conducted at the Università degli Studi di Torino. Gen-Os is gradually resorbable and provides support in bone neoformation helping to preserve the original graft shape and volume (osteoconductive property). Moreover, thanks to its collagen content, the product facilitates blood clotting and the subsequent invasion of repairing and regenerative cells, favoring restitutio ad integrum of missing bone. Because of its marked “hydrophilia,” it can function as a carrier for selected medication and drugs. Gen-Os must always be hydrated and thoroughly mixed with a few drops of sterile physiological solution to activate its collagen matrix and to enhance its adhesivity; it can also be mixed either with OsteoBiol Gel or with patient's blood. If necessary it can as well be mixed with the drug selected for surgery. Gen-Os expands up to 50% in volume after hydration with sterile saline: hydrated collagen contained in each granule also increases sensibly biomaterial adhesivity (<http://www.osteobiol.com/products.php>). The particle sizes of the commercialized product are 250–1,000  $\mu\text{m}$  and its porosity 33% (Figueiredo et al. 2010).

The material showed good clinical results when used for augmentation of the alveolar crest and maxillary sinus (Pagliani et al. 2010; Barone et al. 2010), as a filler in postextractive alveolus (Arcuri et al. 2005) and for implant treatment (Fernández et al., 2011;



**Fig. 2.11** Morphology of the commercial granular samples: (a) Bio-Oss®, (b) PepGen P-15®, (c) OsteoBiol® and (d) Biocoral®. The SEM images show different shapes and structural features

for various particulate materials (Figueiredo et al. 2010) (Reprinted with permission from John Wiley & Sons)

Calvo Guirado et al., 2011). Clinical and histological study suggest that the use of a mixture of collagen gel (OsteoBiol 0, Tecnos) and a collagenated porcine bone (OsteoBiol Gen Os, Tecnos) as a grafting material in combination with a bone cortical lamina (OsteoBiol Lamina Cortical Soft Tecnos) can lead to the

augmentation of the alveolar crest or the maxillary sinus floor prior to or in conjunction with implant placement (Pagliani and Volpe 2010). Histology revealed new bone formation at porcine bone surface, which formed bridges between particles and between particles and preexisting bone. The presence of scalloped

resorption lacunae and new osteons inside the particles indicated ongoing resorption/remodeling of the particles. The histomorphometric analyses showed that the total specimen area consisted of, in average,  $56.5 \pm 15.7\%$  of mineralized tissue of which  $24.8 \pm 13.9\%$  of the total area was porcine bone particles. Similar data were reported also by Nannmark and Sennerby (2008) who evaluated the response of the bone tissue to prehydrated and collagenated porcine bone, with or without a collagen gel, covered with a collagen membrane (OsteoBiol Evolution, TecnoSS). The histological examinations, performed after 8 weeks, showed an active reabsorption of the materials, by osteoclasts as well as part of remodeling with the formation of osteons within the particles, the presence of mature bone and vascularization of the mineralized part and of the soft tissue, and, finally, the active degradation of the collagen in an animal model. Different collagen/collagenated porcine bone ratios do not influence the bone tissue responses to collagenated porcine bone. Both materials exhibited osteoconductive properties and were starting to be resorbed at 8 weeks (Nannmark and Azarmehr 2010). No studies are presently available for the treatment of periodontal bony defects.

### 2.3.3 Coralline Calcium Carbonate

Natural coral graft substitutes are derived from the exoskeleton of marine madreporic corals. Researchers first started evaluating corals as potential bone graft substitutes in the early 1970s in animals and in 1979 in humans. The structure of the commonly used coral, *Porites*, is similar to that of cancellous bone, and its initial mechanical properties resemble those of bone. Polyps absorb the calcium ions and carbonic acid present in the seawater to produce aragonite crystals of calcium carbonate, representing 97–99% of the coral exoskeleton. The remaining balance is made up from various elements, such as oligoelements comprising 0.5–1%, magnesium varying from 0.05% to 0.2%, sodium in quantities of 0.4–0.5%, amino acids representing 0.07% and the remainder consisting of traces of potassium (0.02–0.03%), strontium, fluorine and phosphorous in the phosphate form. The oligoelements found in coral are known to play a critical role in the bone mineralization process and in the activation of enzymatic reactions with osteoid cells. Strontium contributes to the mineralization process

and protects calcification. Fluorine, present 1.25–2.5 times more in coral than in bone, helps bone formation through its effects on osteoblast proliferation. The main differences between natural coral and bone include the organic content and the mineral composition. One third of the total weight in bone is composed of organic components, while the coral organic content is limited to 1–1.5%. The mineral composition of bone is mainly hydroxyapatite and amorphous calcium phosphate associated with calcium carbonate, while coral is essentially calcium carbonate (Demers et al. 2002).

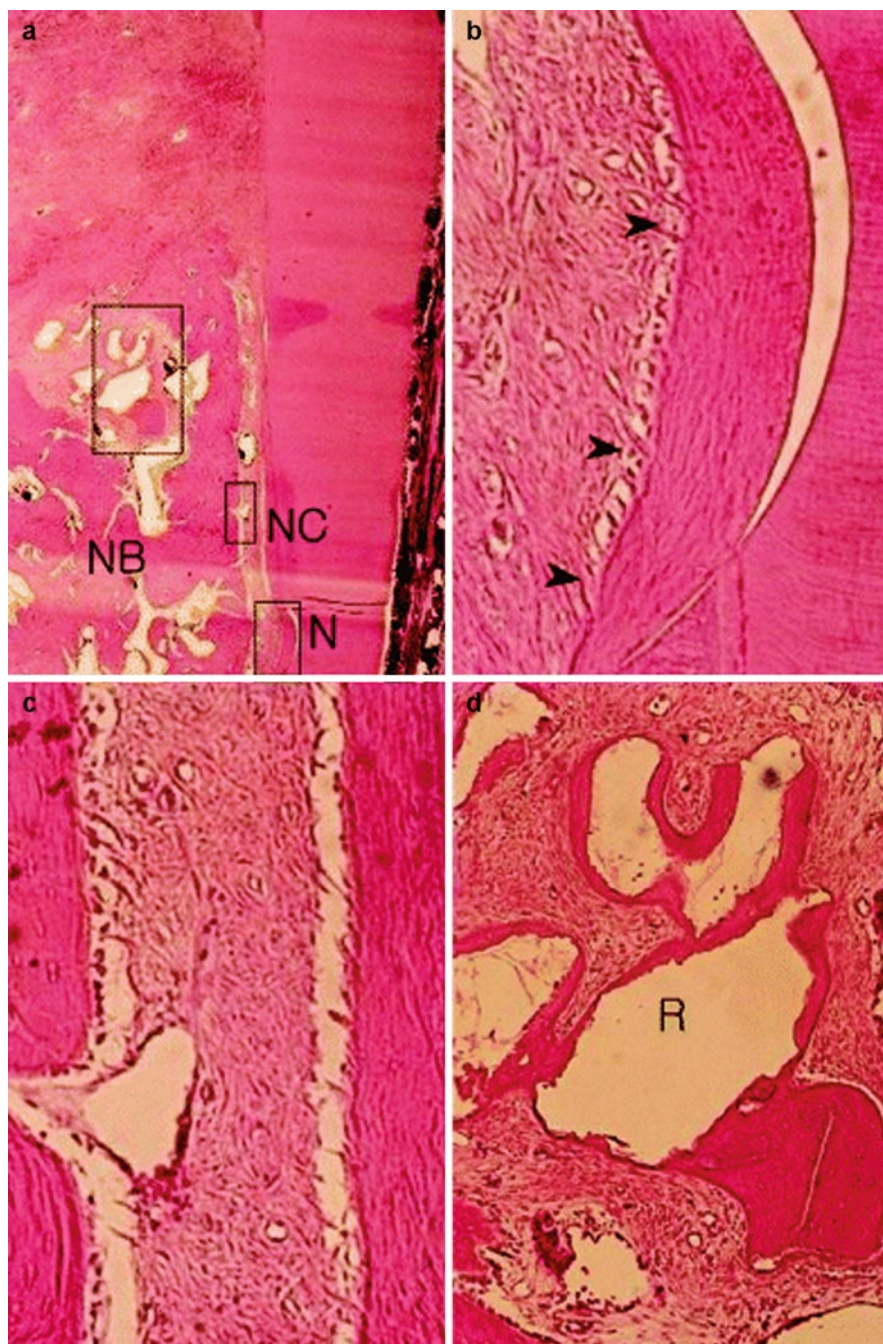
Biocoral (Inoteb, Saint Gonnerly, France) is a commercially available product.

Biocoral is a resorbable bone graft substitute that belongs to the *Porites* group and had an architecture very similar to that of spongy bone, with a porosity >45% and interconnecting pores of diameter 100–200  $\mu\text{m}$  (Mora and Ouhayoun 1995; Yukna 1994a). Coral-derived calcium carbonate constructs can be converted to hydroxyapatite by hydrothermal exchange (Ripamonti et al. 2009). The porosity, especially open porosity, of the material seems to influence the speed of colonization and the resorption rate (Piattelli et al. 1997). Quantitative results showed that the larger the porosity volume, the greater was the coral resorption as well as the new bone apposition (Guillemin et al. 1989). The concavities of the matrices biomimeticize the remodeling cycle of the osteonic primate cortico-cancellous bone and promote the ripple-like cascade of the induction of bone formation (Ripamonti et al. 2009).

Biocoral particles had a very high osteoconductive potential because no fibrous encapsulation has been reported (Piattelli et al. 1997) (Fig. 2.12). Unlike porous hydroxyapatite, derived from the same coral by heat conversion and made non-resorbable, calcium carbonate is resorbable. When implanted into bone tissue, the calcium carbonate crystals gradually resorb to be replaced by mature bone; no fibrous tissue encapsulation, like that reported with hydroxyapatite, was seen (Kim et al. 1996; Piattelli et al. 1997; Gao et al. 1997; Ning et al. 2009). The degradation of Biocoral has been reported to be species specific: 100% degradation in a 3-month period has been reported in a rabbit tibia model (Pollick et al. 1995), while in man most of the particles were present after a 6-month period (Piattelli et al. 1997).

Porous hydroxyapatite (Interpore 200, Irvine, CA) is obtained by the hydrothermal conversion of the calcium carbonate exoskeleton of natural coral into calcium phosphate hydroxyapatite (Saad AlGhamdi et al. 2010b).

**Fig. 2.12** (a) Photomicrograph of site implanted with the coral-derived biomaterial showing new bone (NB) and cementum (NC) formation in the notch area (N) (H-E, original magnification  $\times 20$ ). The higher magnifications show the oblique or perpendicular collagen fiber arrangement. (b) A thick layer of new cementum with an oblique or perpendicular collagen fiber arrangement (*arrowheads*) was observed in the notch area (H-E, original magnification  $\times 100$ ). (c) A well-organized periodontal ligament exhibiting a thinner new cementum layer was observed more coronally (H-E, original magnification  $\times 200$ ). (d) Newly formed osteoid tissue and bone with enclosed osteocytes were deposited around coral-derived biomaterial particles (R) (H-E original magnification  $\times 200$ ) (Kim et al. 2005) (Reprinted with permission from John Wiley & Sons)



Meta-analysis performed by Trombelli et al. (2002) on four selected studies (Kim et al. 1996; Mora and Ouhayoun 1995; Schulz et al. 2000; Yukna 1994a) resulted in a statistically significant difference in CAL gain between coralline calcium carbonate and OFD (weighted mean difference 0.90 mm [95% CI: 0.53–1.27; Q-test for heterogeneity: 6.16 (df = 3),  $P = 0.10$ ]. No significant improvement in probing depth

reduction was observed (weighted mean difference: 0.04 mm).

Reynolds et al. (2003) consistently reported a weighted mean difference in clinical attachment level gain of  $0.91 \pm 1.94$  mm. When changes in bone level were considered, the analysis from three studies (Kim et al. 1996; Mora and Ouhayoun 1995; Yukna 1994a) suggested that coralline calcium carbonate produces a

significant ( $P=0.001$ ) and consistent (heterogeneity not significant) treatment effect (gain in bone fill:  $2.21 \pm 1.82$  mm) (Reynolds et al. 2003). Similar with the previous meta-analysis, no significant improvement in probing depth reduction was noted when treatment with coralline calcium carbonate was compared with OFD (weighted mean difference: 0.09 mm).

Several studies suggested that a bioresorbable calcium carbonate coral implant significantly enhanced space provision for GTR, while alveolar bone formation appeared to be enhanced by its use (Wikesjö et al. 2003; Koo et al. 2005; Polimeni et al. 2004).

## 2.4 Alloplasts (Alloplastic Synthetic Grafts)

An alloplast is a biocompatible, inorganic synthetic bone grafting material. At present, alloplasts marketed for periodontal regeneration fall into two broad classes: ceramics and polymers. The fate of an alloplastic bone grafting material is dependent primarily on its chemical composition, structure and physical properties (Reynolds et al. 2010).

According to Ashman (1992), an ideal synthetic bone material should be:

1. Biocompatible
2. Able to serve as a framework for new bone formation
3. Resorbable in the long term and have potential for replacement by host bone
4. Osteogenic, or at least facilitate new bone formation
5. Radiopaque
6. Easy to manipulate clinically
7. Not support the growth of oral pathogens
8. Hydrophilic
9. Available in particulate and molded forms
10. Have surface electrical activity (i.e., be charged negatively)
11. Microporous and provide added strength to the regenerating host bone matrix, and permit biological fixation
12. Readily available
13. Nonallergenic
14. Adapt to be effective in a broad range of medical situations (e.g., cancer, trauma and infective bone-destroying diseases)
15. Have a surface that is amenable to grafting
16. Act as matrix or vehicle for other materials (e.g., bone protein inducers, antibiotics and steroids)
17. Have high compressive strength

### 2.4.1 Polymethylmethacrylate and Polyhydroxyethylmethacrylate (PMMA-PHEMA) Polymers

Polymers present some options that the other groups do not. Like many polymers are potential candidates for bone graft substitutes represent different physical, mechanical, and chemical properties. The polymers used today can be loosely divided into natural polymers and synthetic polymers. These, in turn, can be divided further into degradable and nondegradable types (Nandi et al. 2010).

At present, a biocompatible microporous polymer containing polymethylmethacrylate (PMMA), polyhydroxyethylmethacrylate (PHEMA) and calcium hydroxide is available as a bone grafting material for the treatment of periodontal defects (HTR™ Synthetic Bone – Biopiant, Norwalk, CT). This composite is prepared from a core of PMMA and PHEMA with a coating of calcium hydroxide (Reynolds et al. 2010). It forms calcium carbonate apatite when introduced into the body and interfaces with bleeding marrow (Gross 1997).

The properties of PMMA-PHEMA polymer include a marked hydrophobicity that facilitates hemostasis, extensive microporosity (150–350  $\mu$ m interled pore size, which results in a 20–30% material porosity), biocompatibility, an important compressive strength (50,000–60,000 psi) and a negative surface charge (–8 to –10 mV), which is believed to impede development of infection (Ashman 1988). The polymer is hydrophilic and osteophilic, which purportedly aids in stabilization of the healing clot (Reynolds et al. 2010). Its hydrophilicity enhances clotting, and its negative particle surface charge allows adherence to bone. It appears to serve as a scaffold for bone formation when in close contact with alveolar bone (Nasr et al. 1999). PMMA-PHEMA polymer does not produce an inflammatory or immune response after prolonged contact with bone or soft tissue (Ashman and Moss 1977).

Histological evidence of new bone formation on PMMA-PHEMA particles has been reported (Stahl

et al. 1990; Froum 1996; Al Ruhaimi 2001; Haris et al. 1998). Histologic responses varied from gain in closure by epithelial adhesion to new attachment of varying magnitude. At the periphery of some particles, limited bone formation was present. The alveolar bed was remodeling, at times surrounding specific particles (Stahl et al. 1990). Froum (1996) showed that PMMA-PHEMA particles were present and surrounded by connective tissue or bone. PMMA-PHEMA appears to serve as a scaffold for new bone formation when in close contact with alveolar bone.

More clinical studies have provided evidence for the effectiveness of this polymeric grafting material in improving clinical parameters in the treatment of furcations and intrabony defects parameters, relative to open flap debridement (Shahmiri et al. 1992; Yukna 1990, 1994b; Yukna 1994b; Yukna and Yukna 1997; Yukna and Greer 1992; Calongne et al. 2001; Prakash et al. 2010).

In a systematic review (Trombelli et al. 2002), a clinical attachment level gain of  $1.9 \pm 1.1$  mm in the test group, PMMA-PHEMA, and  $1.0 \pm 0.9$  mm in the control group, open flap debridement, was found. The difference between treatments (0.90 mm, SE 0.22) was statistically significant ( $P < 0.001$ ) (Trombelli et al. 2005).

### 2.4.2 Demineralized Dentin Matrix (DDM)

The organic component of dentin, which accounts for approximately 20% of dentin weight, is mainly type I collagen, a component of bone. Dentin also contains bone morphogenetic proteins (BMPs), which promote the differentiation of mesenchymal stem cells into chondrocytes, and thus enhance bone formation, non-collagen proteins such as osteocalcin and osteonectin, which have been implicated in calcification and dentin-specific proteins including dentin phosphoprotein, also known as phosphophoryn, and dentin sialoprotein (Yagihashi et al. 2009; Kawai and Urist 1989; Feng et al. 1998; Ritchie et al. 1998).

Studies of various mammalian demineralized dentins have shown to be biocompatible, are able to induce differentiation of undifferentiated mesenchymal cells into osteogenic cells, and thus bone and cartilage formation, and are resorbed during the bone remodeling process (Reddi and Huggins 1973; Inoue et al. 1986a, 1986b; Ihoki 1991; Muramatsu et al. 1993; Beertsen et al. 1993; Ymane et al. 1998; Gomes et al. 2001;

Carvalho et al. 2004; Machado et al. 2006; Yagihashi et al. 2009).

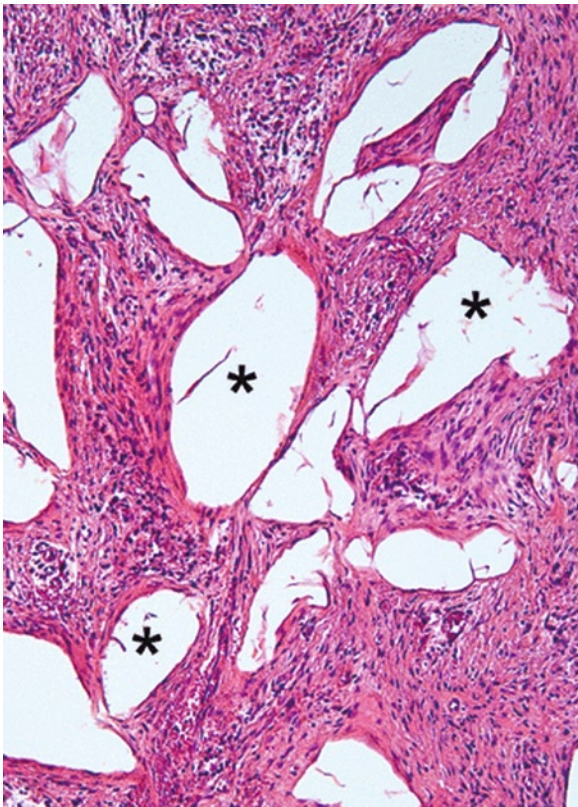
Only one study evaluated the effect of implants of allogenic demineralized dentin on bone regeneration and healing in the treatment of infrabony periodontal defects (Movin et al. 1982). The defects were classified as two-wall and combined three- and two-wall bony defects. During healing, no clinical signs of rejection of the dentin implants were observed, but the soft tissue healing was delayed, probably due to a slow resorption of the dentin implants. No conclusive evidence regarding the capacity of allogenic demineralized dentin to induce new connective tissue attachment could be drawn.

### 2.4.3 Hydroxylapatite (HA)

Synthetic hydroxyapatite,  $\text{Ca}_{10}(\text{PO}_4)_6(\text{OH})_2$ , has been available for more than 30 years. It is the primary mineral found in bone. Synthetic hydroxyapatite can be found as porous or nonporous and in ceramic or non-ceramic forms (Kuo et al. 2007).

HAs present remarkable biocompatibility with little inflammatory response when implanted within connective and bone tissues (Froum et al. 1982; Beckham et al. 1971; Jarcho et al. 1977; de Putter et al. 1983). Histologic studies (Froum et al. 1982; Sapkos 1986; Stahl and Froum 1987) demonstrated that healing often occurred with encapsulation of HA graft materials in connective tissue with no indication of new periodontal attachment, osteogenesis or cementogenesis, in the host tissues adjacent to the graft particles. Healing was characterized primarily by formation of a long junctional epithelium. The graft material therefore acted as a biocompatible foreign body within the gingival tissue (Fig. 2.13).

The advantages of using hydroxyapatite are: (1) immunoreaction can be ignored; (2) postoperative morphologic changes and volume decreases do not occur if small blocks and chips are adequately packed during surgery; (3) postoperative adsorption of hydroxyapatite, if any, is slight and slow and is replaced by bone; and (4) cement fixation performed on a layer of hydroxyapatite particles prevents the harmful influence of polyethylene wear particles of cement interface. The clinical disadvantages hydroxyapatite particles are that they tend not to stay in place in a bleeding site, and there is a relatively slow restoration of bone within the assemblage of particles (Oonishi et al. 1997).



**Fig. 2.13** Light micrograph demonstrating fibrous encapsulation of an alloplastic bone-substitute material (*asterisks*). There is no new bone formation at all (paraffin section stained with hematoxylin and eosin) (Bosshardt and Sculean 2009) (Reprinted with permission from John Wiley & Sons)

Meta-analysis of controlled clinical studies (Galgut et al. 1992; Kenney et al. 1985; Mora and Ouhayoun 1995, Yukna et al. 1998) performed by Trombelli et al. (2002) reported that various forms of HA (porous/non-porous) resulted in significantly greater attachment gain with respect to conventional open flap debridement (OFD) alone (weighted mean difference 1.40 mm, 95% CI: 0.64–2.16). However, meta-analysis revealed that there was highly significant evidence of heterogeneity among studies (Q-test for heterogeneity: 10.72 (df=3),  $P=0.01$ ). Meta-analysis showed also that hydroxyapatite resulted in significantly greater probing depth reduction than the OFD procedure (weighted mean difference 0.98 mm, 95% CI: 0.67–1.29).

The meta-analysis of Reynolds et al. (2003) revealed also the beneficial effect of HA treatment compared with the OFD relative to clinical attachment level gain ( $1.20 \pm 2.22$  mm) and probing depth reduction ( $1.58 \pm 1.77$  mm), the difference being statistically significant.


Similar positive clinical results were reported when HA grafts were compared to osseous allografts in human vertical lesions. Bowen et al. (1989) reported no significant difference in any of the soft tissue measurements when decalcified freeze-dried bone (DFDBA) and HA were compared. However, both treatment modalities reduced pocket depth and demonstrated a gain in clinical attachment levels. There was 2.2 mm of bone repair with DFDBA and 2.1 mm with HA. These values corresponded to a percent defect fill of 61% for DFDBA and 53% for HA. These values were likewise not statistically different (Bowen et al. 1989). In contrast, Oreamuno et al. (1990) indicated that more clinical resolution of interproximal periodontal defects in humans can be obtained with the use of porous HA than with the use of DFDB.

However, the data and clinical findings suggested that FDBA may have some enhanced reparative potential when compared to granular porous HA in the treatment of periodontal defects in humans. Results showed a mean osseous fill of 2.1 mm for FDBA versus 1.3 mm for granular porous hydroxylapatite ( $P=0.07$ ). A mean clinical attachment gain of 2.2 mm for FDBA versus 1.3 mm for granular porous hydroxylapatite ( $P<0.05$ ), and a mean decrease in probing depths of 3.0 mm for FDBA versus 1.4 mm for granular porous hydroxylapatite ( $P<0.5$ ) was found. FDBA was clinically indistinguishable from host bone, whereas porous hydroxylapatite appeared to be separated from host bone by soft tissue (Barnett et al. 1989).

No significant difference in the use of natural coral skeleton or porous hydroxyapatite for treating 1, 2 wall or combined periodontal bone defects for the clinical parameters was reported (clinical probing depth, clinical attachment, gingival recession, bone fill, % bone fill and crest remodeling). Beneficial effects of using each of the biomaterials were revealed (57.4% for natural coral skeleton, 58.1% for porous hydroxyapatite,  $P<0.86$ ) as opposed to simple debridement (22.2%;  $P<0.002$ ;  $P<0.004$ ) (Mora and Ouhayoun 1995).

There are several available forms of hydroxyapatite:

1. *The polycrystalline ceramic form of pure densely sintered HA* is non-resorbable, osteoconductive, has a low microporosity and act primarily as inert biocompatible fillers (Aichelmann-Reidy and Yukna 1998) (Fig. 2.14). It is prepared in relatively large particle size (18–40 mesh) in most commercially available alloplastic preparations: Calcitite (20–40 Mesh (420–840  $\mu\text{m}$ ) and 40–60 Mesh (250–420  $\mu\text{m}$ )) (Calcitek,



**Fig. 2.14** Scanning electron microscopical observation of an osteoinductive HA ceramic (S-HA) and a non-osteoinductive HA ceramic (J-HA). Note the micropores in osteoinductive HA and the absence of micropores (the dense wall) in non-osteoinductive HA (c) magnification of the square in (a); (e) magnification of the square in (c); (d) magnification of the square in (b); (f) magnification of the square in (d). As described by the producer, S-HA: Hydroxyapatite ceramic rods, 5×6 mm, average

pore size 400 μm, porosity 60–70%, sintered at 1,100°C, prepared by Sichuan Union University (gdu, China); J-HA: Hydroxyapatite ceramic rods,  $\phi 3.5 \times 8.5$  mm, provided by Mitsubishi Ceramic Int. (Japan), had a average pore size of 200 μm, a porosity of 70%, and was sintered at 1,200°C (Yuan et al. 1999; Yuan and De Groot 2004) (Reprinted with permission from Elsevier)

Inc., Carlsbad, CA), OsteoGraf/D300 (particle size 250–420  $\mu\text{m}$ ) or OsteoGraf/D700 (particle size 420–1,000  $\mu\text{m}$ ) (CeraMed Corp., Lakewood, CO).

2. *The coralline porous non-resorbable hydroxylapatite* is a replica of a marine coral skeleton, Porites. After the organic components of the coral have been removed, the aragonite of the coral skeleton is converted to HA by treatment with an ammonium phosphate at elevated temperature and pressure. This hydroxylapatite is formed as small crystals in contrast with the large fused crystals found in the sintered or ceramic-like forms of artificial HA (Kenney et al. 1985).

Human histological studies have revealed ossification in the pores of the hydroxylapatite, along their internal lining with bands of bone varying in width from 20 to 150  $\mu\text{m}$  (Carranza et al. 1987). The ossification of the implant pores and the implant periphery as early as 3 months after implantation became pronounced 12 months after placement (Stahl and Froum 1987). These findings provide evidence that the porous HA has the ability to facilitate osteogenesis within the porous structure of the implant when placed in human periodontal defects (Kenney et al. 1986).

It is marketed in different trade names like Interpore 200 (Interpore International, Irvine, CA) and Pro-Osteon 500R (Interpore Cross International, Irvine, CA, USA).

3. *The resorbable nonceramic hydroxylapatite* is highly microporous, non-sintered (nonceramic), composed of small particles measuring 300–400  $\mu\text{m}$  (35–60 mesh), with a controlled, predictable rate of resorption. As the material resorbs, it acts as a mineral reservoir and predictably induces new bone formation via osteoconductive mechanisms. The material appears to be very biocompatible in both hard and soft tissues (Wagner 1989).

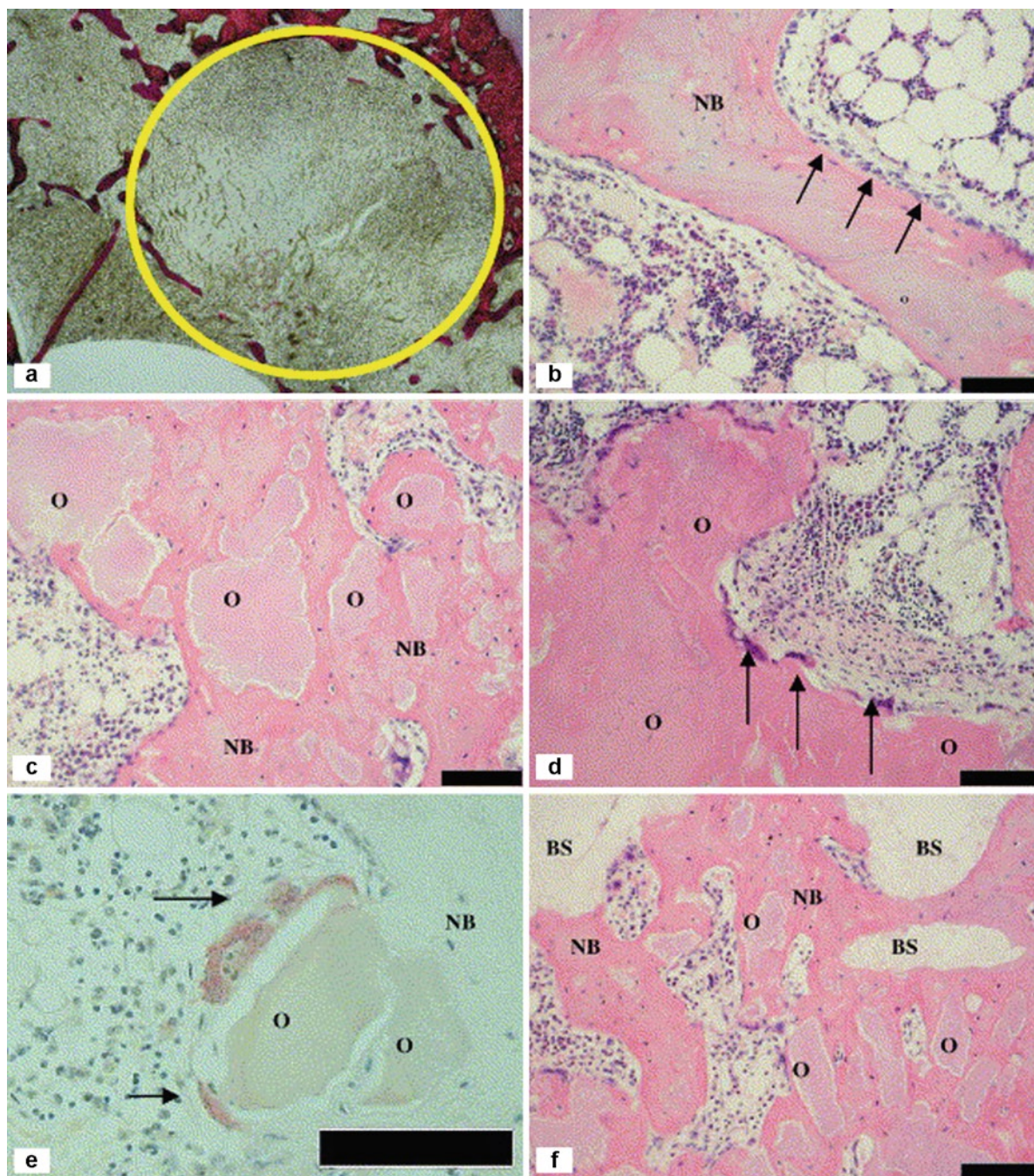
It is marketed in different trade names like Osteogen<sup>®</sup> (Impladent, NY, USA), OsteoGraf/LD-300 (particles are sized between 250 and 420  $\mu\text{m}$ ) (CeraMed Corp., Lakewood, CO) and Cerabone<sup>®</sup> (Coripharm GmbH & Co. KG, Dieburg, Germany).

4. *Nanocrystalline hydroxyapatite (NHA)*. Researchers have found that nanoparticulate hydroxyapatite not only provides the benefits of traditional hydroxyapatites, but also resorbs (Kuo et al. 2007).

Preliminary experimental studies have shown that nanosized ceramics may represent a promising class of bone graft substitutes due to their improved osseointegrative properties and complete resorption


of the material within 12 weeks, being resorbed by osteoclasts (Thorwarth et al. 2005; Chris Arts et al. 2006; Laschke et al. 2007). NHA exhibited good biocompatibility comparable to that of cancellous bone, as indicated by a lack of venular leukocyte activation after implantation (Laschke et al. 2007) and can promote proliferation and osteogenic differentiation of periodontal ligament cells (Kasaj et al. 2008a; Sun et al. 2007). Biopsy specimens taken at different time intervals from human patients with various types of fractures revealed that the studied nanocrystalline hydroxyapatite paste showed good tissue incorporation and bone regeneration: well-structured cortical and cancellous bone tissue with focal fibrosis of the medullary space. Bone healing and ramifications of trabecular bone could be seen between the implant particles. In all specimens, new bone formation was clearly visible beginning with the deposition of osteoid directly onto the substitute material and secondary mineralization in the presence of cell layers resembling osteoblasts (Huber et al. 2006; Huber et al. 2008). Histological studies of intraosseous periodontal defects treated with NHA revealed, after 7 months, an almost complete resorption of the graft. The healing was characterized by the formation of new connective tissue or long epithelial attachment. New cementum and new bone varied from 0 to 0.86 mm and from 0 to 1.33 mm, respectively (Horvath et al. 2009).

A ready-to-use paste in a syringe, available under the name Ostim<sup>™</sup> (Heraeus Kulzer, Hanau, Germany) (NHA), synthetic nanocrystalline hydroxyapatite (NHA) paste containing 65% water and 35% nanostructured apatite particles has been recently introduced in the market. Advantages of this material are the close contact with surrounding tissues, quick resorption characteristics and the large number of molecules on the surface (Schwarz et al. 2006a; Kasaj et al. 2008a) (Fig. 2.15). The needle-shaped HA crystals form agglomerates in transmission electron microscopy (Fig. 2.16). The average crystallite size is 100 nm/20 nm/3 nm, the atomic ratio of calcium phosphorus is 1.67. Ostim paste does not harden after application into the bone and is free of endothermal heating. It is characterized by a large bioactive specific surface area of 106 m<sup>2</sup>/g. The Ostim syringe in the double-sterile pack can be used to apply paste to the bone defect directly or by means of applicators (Huber et al. 2006).



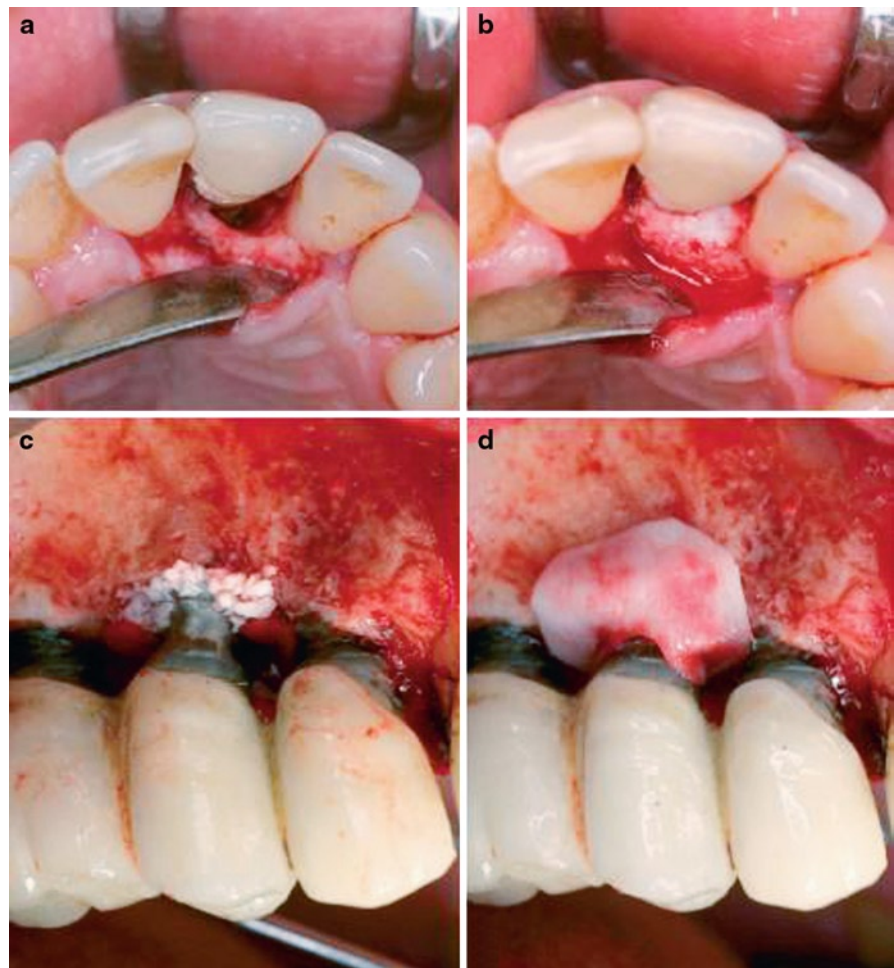
**Fig. 2.15** The use of a bioresorbable nanocrystalline hydroxyapatite paste in acetabular bone impaction grafting. Histology results: (a) Section of an empty defect after 8 weeks. The defect borders are denoted by the circle (+ represents 5.5 mm). (b) New bone formation (NB) on a bone graft remnant (BG) with osteoblasts lining the bone graft (arrows) (c) Areas of non-resorbed

Ostim (O) integrated in new bone (NB). (d) Osteoclasts (arrows) against islands of Ostim (O). (e) TRAP staining confirmed the presence of osteoclasts (arrows) on Ostim (O). (f) New bone (NB) osseous-integrated with Ostim (O) and TCP-HA granules (BS). Bar scale B–F 0.1 mm (Chris Arts et al. 2006) (Reprinted with permission from Elsevier)

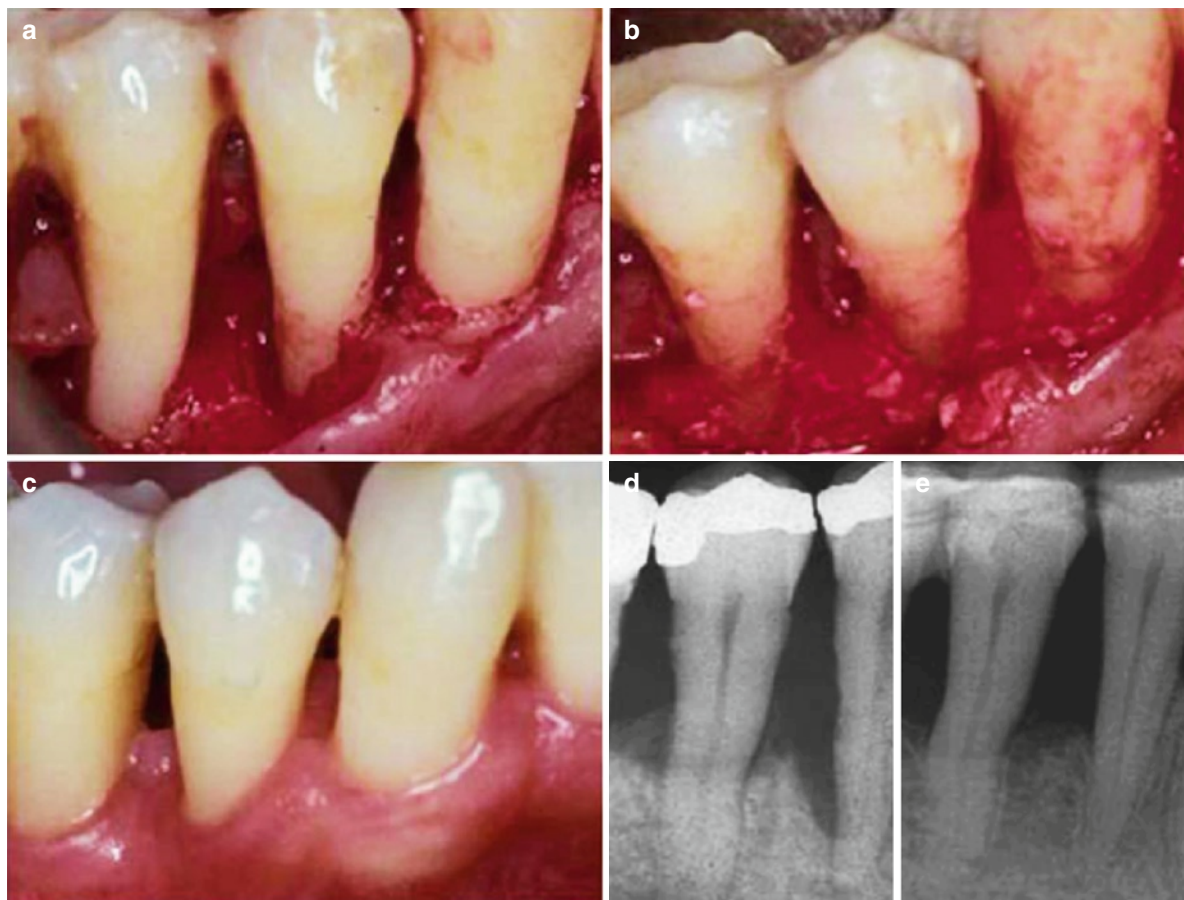


**Fig. 2.16** SEM image of Ostim® (a) and REM image of Cerabone® (b). Ostim is a viscous paste, which contains phase pure nanosize hydroxyapatite crystals as a suspension in water (a). In contrast, the granules of Cerabone are synthesized of a

solid hydroxyapatite ceramic (pentacalcium hydroxide triphosphate) with a pore size of ~0.1–1.5 mm (b). Scale bars: A=250 µm; B=350 µm (Laschke et al. 2007) (Reprinted with permission from John Wiley & Sons)



**Fig. 2.17** (a) Semi-circumferential intrabony defect. (b) Situation following application of nanocrystalline hydroxyapatite. (c) Situation following application of bovine-derived xenograft in the circumferential bone defect. Bio-Gide collagen membrane was trimmed and adapted over the oral and (d) the vestibular aspect of the defect (Schwarz et al. 2006a) (Reprinted with permission from John Wiley & Sons)



**Fig. 2.18** Surgical treatment of intrabony periodontal defects with a fully synthetic nanocrystalline hydroxyapatite (nano-HA) paste (Ostim®; Heraeus Kulzer, Hanau, Germany) containing 65% water and 35% of nanostructured apatite. (a) The intraoperative clinical image shows a deep intrabony defect distal of the

lower right first premolar. (b) Nano-HA paste placed. (c) Clinical situation 6-month postoperative. (d) Presurgical radiograph. (e) 6-month postoperative radiograph (Heinz et al. 2010) (Reprinted with permission from Springer)

The NHA has been proven to be useful for augmentation procedures in osseous defects (Moghadam et al. 2004; Thorwarth et al. 2005) (Fig. 2.17), in the peri-implantitis lesions (Schwarz et al. 2006a; Schwarz et al. 2008; Schwarz et al. 2009) and intraosseous periodontal defects (Fig. 2.18) (Kasaj et al. 2008a; Horvath et al. 2009; Heinz et al. 2010). After 6 months, the treatment of intrabony periodontal defects with an NHA paste led to significantly improved clinical outcomes when compared with open flap debridement alone. Kasaj et al. (2008a) reported a reduction in mean PD from  $7.4 \pm 1.3$  mm to  $3.4 \pm 1.2$  mm and a change in mean CAL from  $8.0 \pm 1.3$  mm to  $4.4 \pm 1.7$  mm for the test group, whereas in the control group the mean PD decreased


from  $7.4 \pm 0.8$  mm to  $4.9 \pm 0.9$  mm, and mean CAL decreased from  $8.1 \pm 1.2$  mm to  $6.4 \pm 1.3$  mm. Similar results were reported by Heinz et al. (2010) who showed that the sites treated with NHA paste showed a reduction in mean PPD from  $8.3 \pm 1.2$  to  $4.0 \pm 1.1$  mm and a gain in PBL of  $4.3 \pm 1.4$  mm, whereas in the control group, the mean PPD changed from  $7.9 \pm 1.2$  mm to  $5.0 \pm 1.2$  mm and PBL gain was  $2.6 \pm 1.4$  mm. Horvath et al. (2009) reported a PD reduction of  $4.0 \pm 0.9$  mm and a CAL gain of  $2.5 \pm 0.8$  mm, on average after the NHA treatment.

5. *Fluorohydroxyapatitic (FHA) biomaterial.* The natural architecture of some calcified algae offers a surface that is similar to that of bone (Kasperk et al. 1988) Damien and Revell 2004.

The commercially available porous biomaterial FRIOS® Algipore® (Friident GmbH, Mannheim, Germany) is manufactured from calcifying marine algae (*Corallina officinalis*). The particles contain a pore system with a mean diameter of 10  $\mu\text{m}$  that is periodically septated (mean interval 30  $\mu\text{m}$ ) and interconnectively microperforated (mean diameter of perforations 1  $\mu\text{m}$ ). Every pore is limited by one layer of small FHA crystallites with a size of 25–35 nm (Fig. 2.19). The impression of a bilayer texture of the walls arises by the contact of the layers of adjacent pores (Schopper et al. 2003). This material is biocompatible, osteoconductive and has an additional desirable property of being slowly resorbable and replaced by newly formed bone (Ricci et al. 1992; Schopper et al. 2003; Ewers et al. 2004; Klongnoi et al. 2006). Clinical investigations demonstrated good results in sinus augmentation (Ricci et al. 1992; Schopper et al. 2003; Klongnoi et al. 2006; Lee et al. 2009). In an animal model, they suggest that C-Graft particles provide a scaffold for the regeneration of new bone and cementum in periodontal bone defects in dog (Nakanishi et al. 2009).

*Biosite*® (Vebas s.r.l., S. Giuliano Milanese, Italy) is a mixture of synthetic HA (88.0%, granulometry of 160–200  $\mu\text{m}$ , total porosity of 60%), equine type I collagen (9.5%) and chondroitin sulfate (2.5%). Chemically, Biosites particles demonstrated a major phase represented by polycrystalline synthetic HA ( $\geq 99\%$ ), little presence of  $\beta$ -tricalcium phosphate and CaO ( $\leq 1\%$ ) and a Ca–P ratio ranging from 1.665 to 1.697 (Scabbia and Trombelli 2004). The material has proved to be highly biocompatible and osteoconductive (Benqué et al. 1985; Serre et al. 1993), as well as actively reabsorbable (Parodi et al. 1996). It has been shown that Biosite®, may directly affect osteoblasts by enhancing chondro/osteogenic gene expression and cytoskeleton-related signaling pathways, which may contribute to its clinical efficacy (Sibilla et al. 2006). Clinical studies have shown favorable effects of Biosite® in improving attachment and probing depth when used for the treatment of intraosseous defects, similar with those obtained with an inorganic xenograft (Bio-Oss®, Geistlich Pharma AG, Wolhusen, Switzerland) (Scabbia and Trombelli 2004).

*Biphasic alloplastic materials* produced by sintering hydroxyapatite (HA) and tricalcium



**Fig. 2.19** (a) Scanning electronmicroscopic examination visualizes the spatial arrangement of the pore system within the fluoro-hydroxyapatite (FHA) FRIOS Algipore biomaterial particles. Arrows show the periodical septation of the pores. (b) Microperforations (arrows) within the fragile walls of the pores connect adjacent pores with each other. (c) Small FHA crystallites are assembled within the walls of the pores. Every pore is limited by one FHA layer. The impression of a bilayer texture of the walls (arrows) arises by the contact of the layers of adjacent pores. (a) Bar = 100  $\mu\text{m}$ . (b, c) Bar = 10  $\mu\text{m}$  (Schopper et al. 2003) (Reprinted with permission from John Wiley & Sons)

phosphate include Calcitec® Inc. (Austin, TX), Osteogen® (Impladent Ltd, Holliswood, NY), Tricos® (Baxter, Bern, Switzerland), MBCP (Biomatlante, Vigneux de Bretagne, France), Ceraform® (Teknimed SA, Vic-en Bigorre, France) and Bone Ceramic® (Straumann, Basel, Switzerland).

#### 2.4.4 Calcium Phosphate Cement (CPC)

Among the materials used for bone and tissue regeneration, calcium phosphate cements are gaining special interest due to their biomimetic nature and potential use as controlled release systems (Table 2.4). These cements are prepared by mixing a liquid phase with a solid phase to create a workable paste that sets into a solid material (Ambard and Mueninghoff 2006; Tamimi et al. 2008; Burguera et al. 2008). The injectable CPC required minimal manipulation to fill and mold the defect wall compared to the placement of a membrane with the GTR procedure (Shirakata et al. 2007). Unfortunately, CPCs have been reported to suffer from some problems, such as prolonged setting time and the inability to set in the presence of blood. Recently, new improved cements have been developed, especially suited for the filling of peri-implant and periodontal defects. They are reported to have a short setting time (around 10 min), fast biodegradation and the possibility to be applied with a syringe (Comuzzi et al. 2002). Premixed calcium phosphate cements were also developed (Xu et al. 2007).

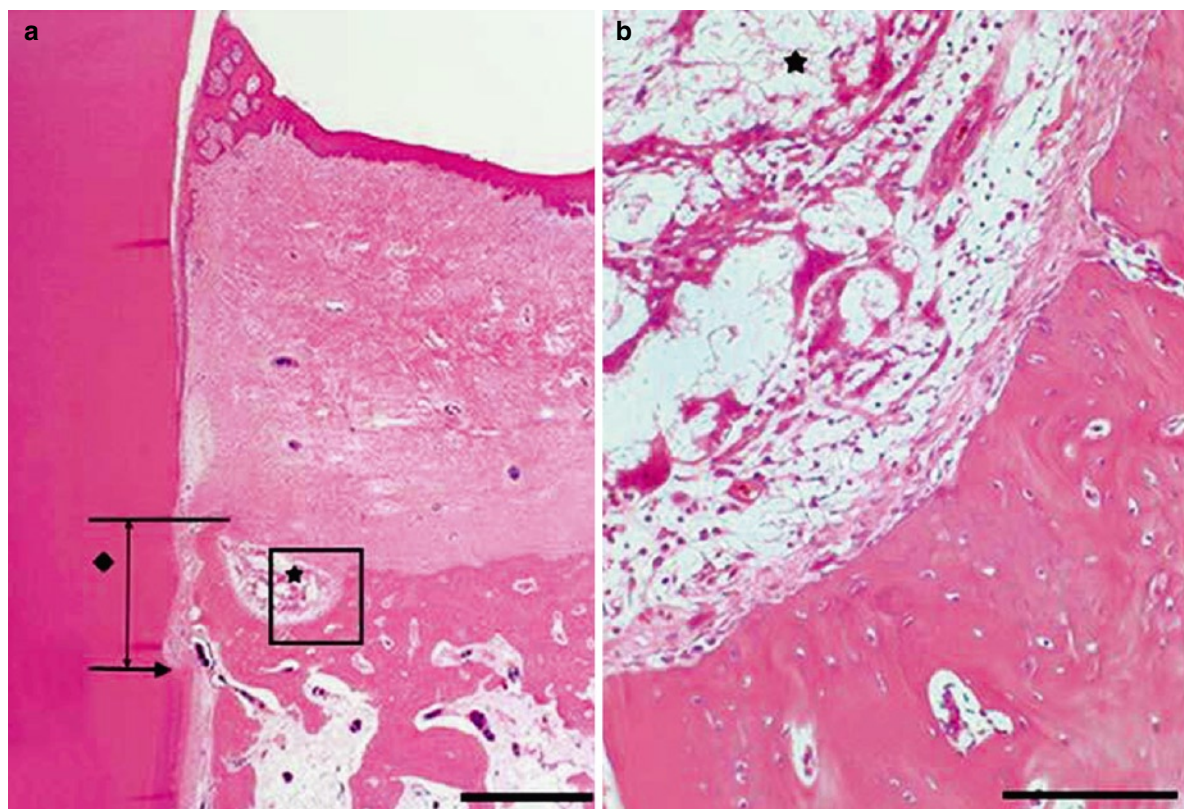
The histological and histomorphometrical examinations confirmed the excellent bone biocompatibility

and osteoconductive properties of the used CaP cement. The material did not evoke any inflammatory response, but favored new bone formation comparable with autologous bone grafting (Aral et al. 2008; Yuan et al. 2000) (Fig. 2.20). This material had been used as a bioabsorbable barrier for guided tissue regeneration in periodontal defects (AlGhamdi et al. 2010b). Animal models revealed that CPC have a high biocompatibility and has an ability to act as a stable scaffold for bone formation and provide adequate space for periodontal tissue regeneration (Fujikawa et al. 1995; Shirakata et al. 2002; Hayashi et al. 2006; Shirakata et al. 2007; Sugawara et al. 2008; Lee et al. 2010). Moreover, in vivo, it cures into an osteoconductive carbonated apatite with chemical and physical characteristics similar to the mineral phase of bone, which subsequently is replaced by natural bone (Shirakata et al. 2008; Constantz et al. 1995; Cohen and Whitman 1997; Elder et al. 2000). Resorption of calcium phosphate ceramics occurs by dissolution or is cell mediated, for example, by foreign body giant cells and osteoclasts (Aral et al. 2008; Yuan et al. 2000). Fast resorption of residual material is desirable to avoid the risk for infection and increase the amount of regenerated periodontal tissue. In line with this, histologic results indicated that when holes were drilled into the hardened CPC, resorption of the CPC mass improved, supposedly by increasing the surface area of the material and allowing increased vascular supply (Shirakata et al. 2002). Experimental studies have proposed the CPCs as a suitable graft for repairing root perforations (Noetzel et al. 2006), sinus augmentation (Aral et al. 2008), as a filler for bone defects around oral implants (Comuzzi et al. 2002) and in alveolar ridge augmentation (Sato et al. 2009).

**Table 2.4** Main calcium phosphate compounds

Ca/P molar ratio	Compound	Formula	Symbol
0.5	Monocalcium phosphate monohydrate	$\text{Ca}(\text{H}_2\text{PO}_4)_2 \cdot \text{H}_2\text{O}$	MCPM
0.5	Monocalcium phosphate anhydrous	$\text{Ca}(\text{H}_2\text{PO}_4)_2$	MCPA
1.0	Dicalcium phosphate dihydrate	$\text{CaHPO}_4 \cdot 2\text{H}_2\text{O}$	DCPD
1.0	Dicalcium phosphate anhydrous	$\text{CaHPO}_4$	D CPA
1.33	Octacalcium phosphate	$\text{Ca}_8(\text{HPO}_4)_2(\text{PO}_4)_4 \cdot 5\text{H}_2\text{O}$	OCP
1.5	$\alpha$ -Tricalcium phosphate	$\alpha\text{-Ca}_3(\text{PO}_4)_2$	$\alpha$ -TCP
1.5	$\beta$ -Tricalcium phosphate	$\beta\text{-Ca}_3(\text{PO}_4)_2$	$\beta$ -TCP
1.67	Hydroxyapatite	$\text{Ca}_{10}(\text{PO}_4)_6(\text{OH})_2$	HA
2.0	Tetracalcium phosphate	$\text{Ca}_4(\text{PO}_4)_2\text{O}$	TTCP or TetCP

Source: Kamitakahara et al. (2008). Reprinted with permission from Sage Publications



**Fig. 2.20** Osteoconductive effects of calcium phosphate glass cement grafts in rabbit calvarial defects. Surgical sections from the calcium phosphate glass cement (CPGC) group. (a) Histologic view of the CPGC group. Most particles were resorbed and new bone was formed above the notch (H–E,  $\times 20$ ; base of reference notch [bN]: arrow; height of new bone: black diamond; CPGC

particle: black star; bar=2 mm). (b) Histologic view of magnified black square area ( $\times 200$ ). Osteoblast-like cells were observed around remaining particles. Peripheral new bone was woven bone with isolated osteocytes (H–E,  $\times 200$ ; CPGC particle: black star; NB: new bone; WB: woven bone; bar = 0.1 mm) (Lim et al. 2010) (Reprinted with permission from John Wiley & Sons)

When CPC was used in human studies for periodontal bone repair, tooth mobility resulted in early fracture and eventual exfoliation of the rigid and brittle implants (Brown et al. 1998; Xu et al. 2002). Controversial results were obtained from clinical studies, CPCs being either significantly better than hydroxyapatite ceramic granules (Rajesh et al. 2009) either failing to demonstrate any superior clinical outcomes for the CPC compared to the OFD when used in treating intraosseous periodontal defects (Shirakata et al. 2008). Recently, Mellonig et al. (2010) evaluated the clinical and histologic results of a calcium phosphate bone cement in the treatment of human periodontal intraosseous defects. At 6 months, results demonstrated that all defects resulted in probing depth reduction and in clinical attachment level

gain. However, no site showed periodontal regeneration and there was no new bone formation. New cementum and connective tissue were limited to 0.2 mm or less. Large deposits of the bone cement were noted encapsulated in connective tissue (Mellonig et al. 2010).

In recent years, lots of phosphate cements have been developed and studied (Table 2.5). Common components besides tetracalcium phosphate, dicalcium phosphate dihydrate or anhydrous are monocalcium phosphate monohydrate and anhydrous, octacalcium phosphate, tricalcium phosphate, hydroxyapatite and fluorapatite, with different additives like carbonates, sulfates or metallic oxides. Water, calcium- or phosphate-containing solutions, organic acids or aqueous solutions of polymers are

**Table 2.5** List of commercial calcium phosphate cements with their composition (when available)

Company	Cement name	Components	End-product
ETEX	$\alpha$ -BSM	Powder: ACP (50%), DCPD (50%)	Apatite
	Embarc	Solution: H <sub>2</sub> O (unbuffered saline solution)	
	Biobon		
Stryker-Leibinger Corp.	BoneSource	Powder: TetCP (73%), DCP (27%) Solution: H <sub>2</sub> O, mixture of Na <sub>2</sub> HPO <sub>4</sub> and NaH <sub>2</sub> PO <sub>4</sub>	Apatite
Teknimed	Cementek®	Powder: $\alpha$ -TCP, TetCP, Na Glycerophosphate Solution: H <sub>2</sub> O, Ca(OH) <sub>2</sub> , H <sub>3</sub> PO <sub>4</sub>	Apatite
	Cementek® LV	Powder: $\alpha$ -TCP, TetCP, Na Glycerophosphate, dimethylsiloxane Solution: H <sub>2</sub> O, Ca(OH) <sub>2</sub> , H <sub>3</sub> PO <sub>4</sub>	Apatite
Biomet	Calcibon® (previously called "Biocement D")	Powder: $\alpha$ -TCP (61%), DCP (26%), CaCO <sub>3</sub> (10%), PHA (3%) Solution: H <sub>2</sub> O, Na <sub>2</sub> HPO <sub>4</sub>	Apatite
	Mimix™	Powder: TetCP, $\alpha$ -TCP, C <sub>6</sub> H <sub>5</sub> O <sub>7</sub> Na <sub>3</sub> · 2H <sub>2</sub> O Solution: H <sub>2</sub> O, C <sub>6</sub> H <sub>8</sub> O <sub>7</sub>	Apatite
	QuickSet Mimix™	Powder: n <sup>a</sup> Solution: n <sup>a</sup>	Apatite
Mitsubishi Materials	BiopeX®	Powder: $\alpha$ -TCP (75%), TetCP (20–18%), DCPD (5%), HA (0–2%) Solution: H <sub>2</sub> O, sodium succinate (12–13%), sodium chondroitinsulphate (5–5.4%)	Apatite
	BiopeX®-R	Powder: $\alpha$ -TCP, TetCP, DCPD, HA, Mg <sub>3</sub> (PO <sub>4</sub> ) <sub>2</sub> , NaHSO <sub>3</sub> Solution: H <sub>2</sub> O, sodium succinate, sodium chondroitin sulphate	Apatite
Kyphon	KyphOs™	Powder: $\alpha$ -TCP (77%), Mg <sub>3</sub> (PO <sub>4</sub> ) <sub>2</sub> (14%), MgHPO <sub>4</sub> (4.8%), SrCO <sub>3</sub> (3.6%) Solution: H <sub>2</sub> O, (NH <sub>4</sub> ) <sub>2</sub> HPO <sub>4</sub> (3.5 M)	Apatite
Skeletal Kinetics	Callos™	Powder: n <sup>a</sup> Solution: n <sup>a</sup>	Apatite
Shanghai Rebone Biomaterials Co, Ltd	Rebone	Powder: TetCP, DCP Solution: H <sub>2</sub> O <sup>b</sup>	Apatite
Synthes-Norian	Norian® SRS	Powder: $\alpha$ -TCP (85%), CaCO <sub>3</sub> (12%) MCPM (3%)	Apatite
	Norian® CRS	Solution: H <sub>2</sub> O, Na <sub>2</sub> HPO <sub>4</sub> <sup>c</sup>	
	Norian® SRS Fast Set Putty	Powder: n <sup>a</sup>	Apatite
	Norian® CRS Fast Set Putty	Solution: n <sup>a</sup>	
	chronOS™ chronOS™ Inject	Inject Powder: $\beta$ -TCP (73%), MCPM (21%), MgHPO <sub>4</sub> · 3H <sub>2</sub> O (5%), MgSO <sub>4</sub> (0.1%), Na <sub>2</sub> H <sub>2</sub> P <sub>2</sub> O <sub>7</sub> (<1%) Solution: H <sub>2</sub> O, sodium hyaluronate (0.5%)	Brushite

(continued)

**Table 2.5** (continued)

Company	Cement name	Components	End-product
Kasios	Eurobone®	Powder: $\beta$ -TCP (98%), $\text{Na}_4\text{P}_2\text{O}_7$ (2%) Solution: $\text{H}_2\text{O}$ , $\text{H}_3\text{PO}_4$ (3.0 M), $\text{H}_2\text{SO}_4$ (0.1 M)	Brushite
CalciphOs	VitalOs	Component 1: $\beta$ -TCP (1.34 g), $\text{Na}_2\text{H}_2\text{P}_2\text{O}_7$ (0.025 g), $\text{H}_2\text{O}$ , salts (0.05 M pH 7.4 PBS solution) Component 2: MCPM (0.78 g), $\text{CaSO}_4 \cdot 2\text{H}_2\text{O}$ (0.39 g), $\text{H}_2\text{O}$ , $\text{H}_3\text{PO}_4$ (0.05 M)	Brushite

Source: Bohner et al. (2005) (and references therein). Reprinted with permission from Elsevier

The end product of the reaction can be either an apatite (calcium deficient, carbonated, etc.) or brushite

<sup>a</sup>Not found in the literature or on the web

<sup>b</sup>Assumed composition based on the scientific literature

<sup>c</sup>Estimated composition


<sup>d</sup>The cement consists of two liquids in which the various powder components are dispersed

used as cement liquids. The primary role of the liquid is to provide a vehicle for the dissolution of the reactants and precipitation of the products, although it may sometimes contain a reactant for the cement setting reactions (Noetzel et al. 2006). A nonrigid and high-strength CPC by incorporating tetracalcium phosphate and chitosan, a natural elastomeric and biocompatible biopolymer, into the conventional CPC was developed (Xu et al. 2002; Xu et al. 2006). The powder of Augmentech AT (Wetzlar, Germany) consists of tricalcium phosphate (TCP), magnesium phosphate, magnesium hydrogen phosphate and strontium carbonate. The liquid is a watery solution of diammonium hydrogen phosphate (Noetzel et al. 2006). Norian® PDC™ (Shofu Inc., Kyoto, Japan) is injectable, moldable, fast setting, bioabsorbable and has high compressive strength. It is composed by a powder mix composed of  $\alpha$ -tricalcium phosphate (a  $\text{Ca}_3[\text{PO}_4]_2$ ), monocalcium phosphate monohydrate ( $\text{Ca}[\text{H}_2\text{PO}_4]_2 \cdot \text{H}_2\text{O}$ ) and calcium carbonate ( $\text{CaCO}_3$ ) mixed with a solution of sodium phosphate. It began to harden at a physiologic temperature and pH, and the final compressive strength was 55 MPa (compared to 1.9 MPa for cancellous bone). Its pore diameter was 300 Å. The powder and liquid are added separately in a sterile capsule and need to be blended inside the capsule using an amalgam mixer-like apparatus for 20 s. The mixed CPC should be injected into the defects within 5 min (Shirakata et al. 2008). Norian PDC is bioabsorbable and is provided as a capsule composed of powder and liquid. Once the paste sets, it is moldable and injectable within 5 min. Hardened Norian PDC has enough

compressive mechanical strength to be kept in the defect by itself without the use of a membrane. After solidification, the CPC can act as an occlusive space maintainer, providing adequate space for bone regeneration (Sato et al. 2009).

The fabrication of CPC is a versatile process which yields a variety of tailor-made injectable pastes and sets cement materials with different physicochemical and mechanical properties. The ultimate properties of the cement will depend on the characteristics of the solid and aqueous phase and the reaction conditions. One feature of special interest in cements is the fact that they are intrinsically porous. They have an important percentage of porosity within the nano/submicron size range. While porosity can be a limitation for the use of these materials in high-load-bearing applications, for example, vertebroplasty, it is vital for other applications. Porosity is sought to enhance a material's resorbability and the extent of bioactivity by increasing the surface area available for reaction. In the same way, their inherent porosity makes these materials good carriers for controlled drug delivery systems (Espanol et al. 2009; Ginebra et al. 2006a, b).

The possibility to use CPCs not only as bone substitutes but also as carriers for local and controlled supply of drugs is very attractive and can be useful in treatments of different skeletal diseases, such as bone tumors, osteoporosis or osteomyelitis, which normally require long and painful therapies. Unlike calcium phosphate ceramics employed as drug delivery systems, where the drugs are usually absorbed on



**Fig. 2.21** Microstructure of an apatitic calcium phosphate cement after setting, showing the micro-/nanoporous structure formed by the entanglement of the precipitated crystals (Ginebra et al. 2006a) (Reprinted with permission from Elsevier)

the surface, in CPCs the drugs can be incorporated throughout the whole material volume, by adding them into one of the two cement phases (Fig. 2.21). This fact can facilitate the release of drugs for more prolonged times (Ginebra et al. 2006a).

The studies about incorporation of drugs into CPC cover different aspects. In the first place, it is necessary to verify that the addition of the drug (either to the liquid or the solid phases of the cement) does not interfere in the setting reaction, modifying the physicochemical properties, not only in terms of the setting and hardening mechanisms but also with respect to the rheological behavior. Second, it is necessary to characterize the kinetics of drug release in vitro. Subsequently, the effectiveness of the cement to act as carrier for drug delivery in vivo must be assessed. And finally, the clinical performance of the drug delivery system must be evaluated (Ginebra et al. 2006a).

CPCs have been proposed as carriers for biologically active peptides, such as antibiotics (Yu et al. 1992; Bohner et al. 1997; Blom et al. 2001) and bone growth factors (Otsuka et al. 1994; Meraw et al. 2000; Wikesjö et al. 2002; Sorensen et al. 2004). A recent large-scale, prospective, blinded, and randomized controlled clinical trial study demonstrated that the use of rhPDGF-BB +  $\beta$ -TCP was safe and effective in the treatment of periodontal osseous defects (Nevins et al. 2005a). The incorporation of platelet-derived growth factor-BB (PDGF-BB) with  $\beta$ -tricalcium phosphate was approved by the FDA in 2004. GEM-21 S™ is a

completely synthetic grafting system for bone and periodontal regeneration launched in 2005. This system is composed of a purified platelet-derived growth factor-BB (PDGF-BB) and  $\beta$ -tricalcium phosphate matrix (AlGhamdi et al. 2010b).

### 2.4.5 $\beta$ -Tricalcium Phosphate (TCP)

Tricalcium phosphate is a porous calcium phosphate compounds (Yamada et al. 2010). Alpha and beta tricalcium phosphate are produced similarly, although they display different resorption properties. The crystal structure of alpha tricalcium phosphate ( $\alpha$ - $\text{Ca}_3(\text{PO}_4)_2$ ) is monoclinic and consists of columns of cations, while the beta tricalcium phosphate has a rhombohedral structure. The former is formed by heating the latter above 1,180°C and quenching in air to retain its structure. Alpha form is less stable than beta and forms the stiffer material calcium-deficient hydroxyapatite when mixed with water (Sukumar and Drízhal 2008; TenHuisen and Brown 1998).


$\beta$ -Tricalcium phosphate ( $\beta$ -TCP) is a porous form of calcium phosphate, with similar proportions of calcium and phosphate to cancellous bone (Reynolds et al. 2010). However, the compressive strength of porous TCP reaches only 1/20 of cortical bone (Gao et al. 1997; Jarcho 1981). Numerous studies have shown that calcium TCP support the attachment, proliferation and differentiation of osteoblasts and mesenchymal cells as well as *bone growth* (von Arx et al. 2001; Aybar et al. 2004; Haimi et al. 2009; Jang et al. 2008; Kamitakahara et al. 2008). Tricalcium phosphate ceramic is *biocompatible* (Metsger et al. 1982) and *osteoconductive* (Knabe et al. 2000; Ignatius et al. 2001; Hashimoto-Uoshima et al. 1995). The exact mechanism(s) by which  $\beta$ -TCP exerts osteoconductivity were documented only recently. It was showed that primary human osteoblasts (HOBs) seeded into the  $\beta$ -TCP scaffolds expressed significantly higher levels of osteogenic genes, compared to those cultured on tissue culture plastic; meanwhile, these cells showed sevenfold increase in  $\alpha 2$  integrin subunit gene expression and the activation of the mitogen-activated protein kinase (MAPK)/extracellular-related kinase (ERK) signaling pathway. In addition, the osteogenic conduction by  $\beta$ -TCP scaffolds was attenuated directly by

inhibiting MAPK/ERK or indirectly by blocking the  $\alpha 2\beta 1$  integrin signaling pathway. It seems that  $\beta$ -TCP scaffold exerts osteoconductivity through  $\alpha 2\beta 1$  integrin and downstream MAPK/ERK signaling pathway (Lu and Zreiqat 2010a, 2010b).

Physicochemically,  $\beta$ -TCP is a resorbable material with  $\geq 99\%$  phase purity (Tadic and Epple 2004), total microporosity and a homogeneous ceramic sinter structure. Thus, optimal matrix for the formation of new bone is available immediately after implantation. Bioresorbability of the calcium phosphate ceramics is governed not only by the solubility of the constituents of the material, but also by morphology implying porosity and pore structure (Kamitakahara et al. 2008). The intergranular spaces provide a scaffold for ingrowths of blood vessels for nutrition of the newly formed bony structures. From the initial stage of bone regeneration, the material is resorbed (Fig. 2.22). Its slow biodegradation property, within 24 months the material is completely metabolized, harmonizes with bone formation and remodeling process and results in a displacement of the material to bone (Ellinger et al. 1986; Artzi et al. 2004; Bokan et al. 2006; Kamitakahara et al. 2008). The resorption mechanism of the formal  $\beta$ -TCP is controversial. It was suggested that the mechanism is mainly dissolution in biological liquids because of the absence of osteoclasts around the materials in rabbit's experiments (Lu et al. 1998). Cell-mediated bioresorption was also proposed to be a predominant factor in the process of biodegradation of

$\beta$ -TCP in dog experiments, as considerable numbers of osteoclast-like giant cells and abundant new bone apposition were seen on the  $\beta$ -TCP-implanted defects (Renooji et al. 1985; Neamat et al. 2009).

Despite the promising results in orthopedic surgery (Larsson 2010),  $\beta$ -TCP has provided contradictory evidence in animal (Levin et al. 1974; Barney et al. 1986; Wong et al. 1989; Wada et al. 1989) and human histology studies (Baldock et al. 1985; Dragoo and Kaldahl 1983; Saffar et al. 1990; Froum and Stahl 1987; Stahl and Froum 1986). In dogs, at 16 weeks after the treatment of surgically created three-wall defects, TCP particles were actively resorbed by giant cells and macrophages and were incorporated into new bone matrix (Barney et al. 1986). Similar results were reported in monkeys, where TCP was biodegraded through phagocytosis by histiocytes and multinucleated giant cells. The residual particles were incorporated into the new bone matrix and displayed the bone growth guiding property. In the histological features and immunohistochemical analysis of proliferating cell nuclear antigen (PCNA) of the intrabony defects in dogs augmented with  $\beta$ -TCP, osteoid tissue with a platelike structure and cellular mesenchymal proliferation besides osteoid islands joined by bridges were observed after 3 months. Six months after the implantation, the  $\beta$ -TCP granules were replaced by abundant new platelike bone besides PCNA-enriched, small, oval-shaped mononuclear cells and multinucleated giant cells that were attached to newly formed bones.



**Fig. 2.22** SEM photographs of a commercially available porous  $\beta$ -TCP ceramic (Kamitakahara et al. 2008) (Reprinted with permission from Sage Publications)

No remains of the  $\beta$ -TCP granules could be seen after 3 and 6 months with the newly formed platelike bones and no histological sign of inflammatory reaction or formation of foreign body granulomas (Sugawara et al. 2008). In human histological studies, the TCP particles were encapsulated by fibrous connective tissue, but the particles did not stimulate new bone growth, with residual graft particles evident 18 months following treatment. Although new cementum was observed, there was limited evidence of new attachment (Baldock et al. 1985; Dragoo and Kaldahl 1983; Saffar et al. 1990; Froum and Stahl 1987; Stahl and Froum 1986). Stavropoulos et al. 2010 indicated that the clinical improvements (i.e., PD reduction and CAL gain) obtained after implantation of a granular  $\beta$ -TCP product adjunctively with open flap debridement of periodontal intrabony defects were, in part, characterized by regeneration (although minimal in amount), whereas the major portion of healing occurred with the formation of a long junctional epithelium on the previously affected root surface. In most specimens,  $\beta$ -TCP particles were embedded in the connective tissue, whereas the formation of a mineralized bone-like or cementum-like tissue around the particles was only occasionally observed. In all of the specimens, ghost images of graft particles, appearing as empty spaces due to the decalcification procedure, were observed. The graft particles appeared not to have any apparent association with bone formation, and the major portion of the periphery of the particles was in contact with fibrous connective tissue. A thin layer of a mineralized, occasionally cellular substance in direct contact with some portion of the periphery of the particles was only sporadically observed, and the presence of osteoclasts in contact with the particles was not obvious. The histologic evaluation indicated the formation of new cellular cementum with inserting collagen fibers to a varying extent (mean:  $1.9 \pm 0.7$  mm; range: 1.2–3.03 mm) coronal to the most apical extent of the root instrumentation. The mean new bone formation was  $1.0 \pm 0.7$  mm (range: 0.0–1.9 mm) (Stavropoulos et al. 2010).

Clinical studies reported improvements in clinical outcomes, including clinical attachment level, after the treatment of intrabony periodontal defects involving surgical implantation of  $\beta$ -TCP (Nery and Lynch 1978; Louise et al. 1985; Detienville et al. 1986; Evans et al. 1989; Snyder et al. 1984; Strub et al. 1979; Palti and Hoch 2002; Stavropoulos et al. 2010). Stavropoulos et al. (2010) reported a mean probing depth reduction

from  $10.8 \pm 2.3$  mm presurgically to  $4.6 \pm 2.1$  mm, and a mean clinical attachment level (CAL) gain of  $5.0 \pm 0.7$  mm was observed. The increase in gingival recession was  $1.2 \pm 3.2$  mm.


Bokan et al. (2006) found that the treatment of deep intrabony defects with Emdogain (EMD) either alone or in combination with  $\beta$ -TCP led to a clinically and statistically significant reduction of probing depth (PD) and gain in clinical attachment (CAL). The additional application of  $\beta$ -TCP showed no clear superiority to treatment with Emdogains alone. Treatment with EMD alone yielded a  $3.9 \pm 1.3$ -mm PD decrease and a  $3.7 \pm 1.0$ -mm CAL gain ( $P < 0.001$ ), whereas EMD+ $\beta$ -TCP produced a  $4.1 \pm 1.2$ -mm PD reduction and a  $4.0 \pm 1.0$ -mm PAL gain ( $P < 0.001$ ).

Several commercial available TPC products are available on the market: Bioresorb<sup>®</sup> is available as porous granulate (particle size: 0.5–2 mm) mainly for dental application. Chronos<sup>®</sup> and Ceros<sup>®</sup> (Mathys, Bettlach, Switzerland) are also granular materials with a particle size of 0.5–1.4 mm and pore sizes of 100–500  $\mu$ m (60% pore volume), also mainly for dental application. Cerasorb<sup>®</sup> (Curasan, Kleinostheim, Germany) is available as porous granulate (pore size  $> 5$   $\mu$ m) in particle sizes of 0.05–2 mm (grain sizes: 50–150  $\mu$ m, 150–500  $\mu$ m, 500–1,000  $\mu$ m, 1,000–2,000  $\mu$ m) for dental application and as machined macroporous blocks for orthopedic applications (Fig. 2.23). Vitoss<sup>®</sup> is a porous granulate (pore size 10–1,000  $\mu$ m; porosity approx. 90%; particle size 3–5 mm) for dental application (Tadic and Epple 2004). Synthograft<sup>™</sup> (Bicon, Boston MA, USA) is available in two particle sizes: 50–500  $\mu$ m and 500–1,000  $\mu$ m.

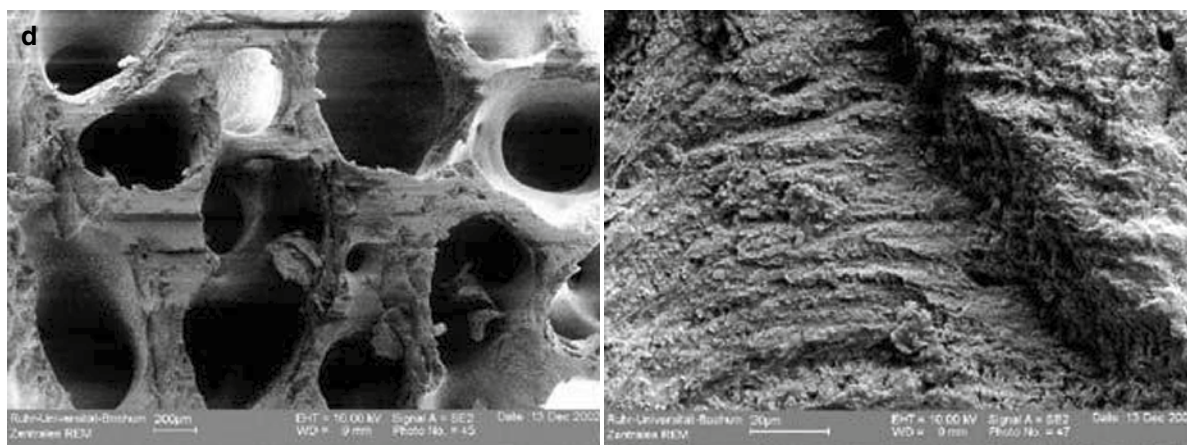
Biphasic alloplastic material is produced by sintering hydroxyapatite (HA) and tricalcium phosphate to a chemically united material, with pore sizes of  $> 100$   $\mu$ m (Fig. 2.24). Synthetically produced alloplasts used in implant dentistry include Calcitec<sup>®</sup> Inc. (Austin, TX), Osteogen<sup>®</sup> (Impladent Ltd, Holliswood, NY), Tricos<sup>®</sup> (Baxter, Bern, Switzerland), MBCP (Biomatlante, Vigneux de Bretagne, France), Osteon<sup>™</sup> (Genoss Co. Ltd., Suwon, Korea) and Bone Ceramic<sup>®</sup> (Straumann, Basel, Switzerland). However, sufficient documentation of the clinical utility of several of these alloplasts is still lacking (Hallman and Thor 2008). Osteon<sup>™</sup> (Genoss Co. Ltd., Suwon, Korea) is composed of 70% HA and 30%  $\beta$ -tricalcium phosphate ( $\beta$ -TCP). HA coated with  $\beta$ -TCP establishes an interconnected scaffold with a porosity of 300–500 nm (Lee et al. 2010).

Ceraform® is a commercially available ceramic, manufactured by Teknimed SA (Vic-en Bigorre, France). This material is a synthetic biphasic ceramic made of 65% HA and 35% TCP. The material is available as a block or granular form and sterilized by gamma radiation. The mean granular diameter is between 900 and

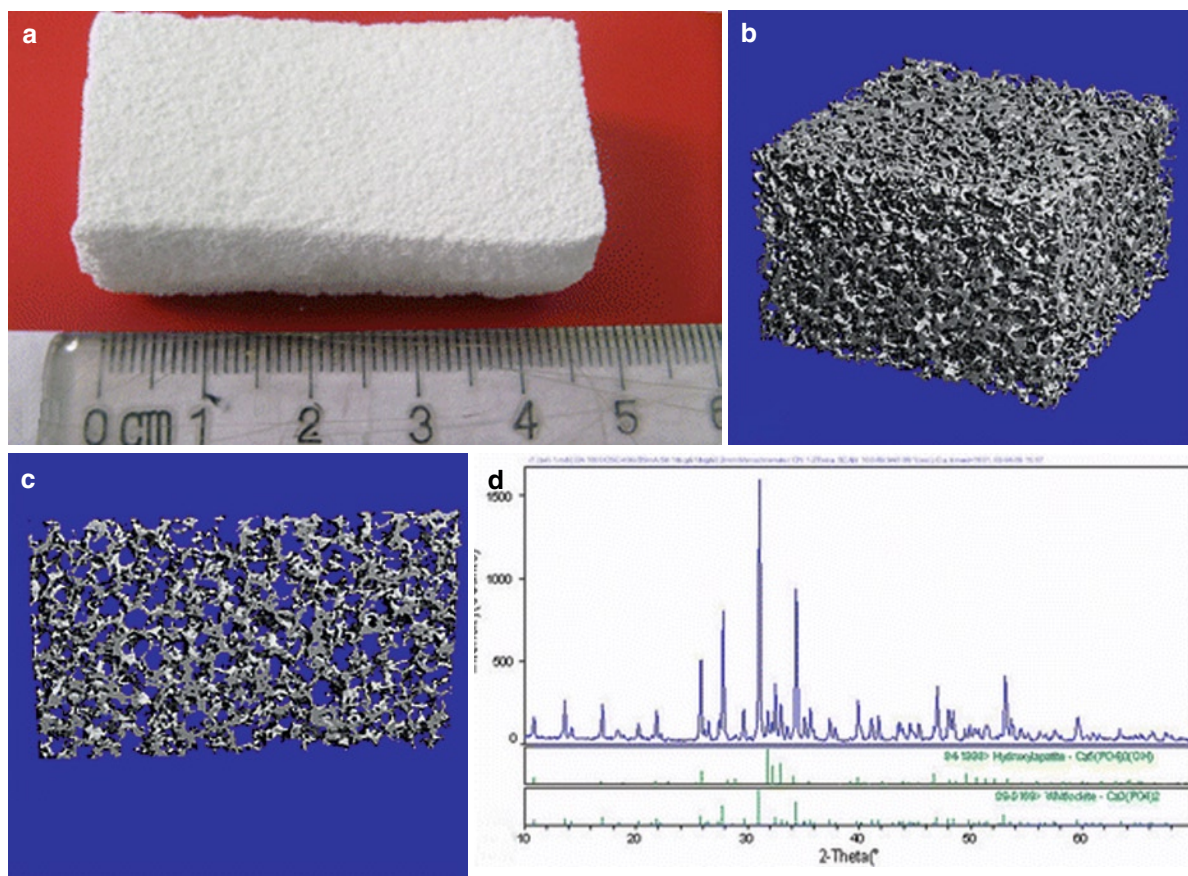
1,200  $\mu\text{m}$  (Develioğlu et al. 2006). BoneCeramic® is a composite of medical purity biphasic calcium phosphate: a mixture of 60% hydroxyapatite, which is 100% crystalline, and 40% of the  $\beta$  form of TCP in particulate form. The graft material is 90% porous with interconnected pores 100–500  $\mu\text{m}$  in diameter.



**Fig. 2.23** SEM pictures of four representative bone graft materials. (a) Cerasorb®, (b) Cerabone®, (c) Aligpore® and (d) Tutoplast® (bovine) (Tadic and Epple 2004) (Reprinted with permission from Elsevier)




**Fig. 2.23** (continued)



**Fig. 2.24** Structural profile of porous biphasic calcium phosphate (PBCP). **(a)** The aspect of PBCP sample. **(b)** 3D reconstruction image of BCP by  $\mu$ CT. **(c)** Reconstruction transect image of PBCP by  $\mu$ CT. **(d)** XRD photograph of PBCP showed that only HA and  $\beta$ -TCP phases were detected. **(e)** SEM micro-

graphs of macropores in PBCP block ( $\times 120$ ). Bar scales, 1 mm; **(f)** SEM micrographs of micropores in the wall of macropores, magnified view of **(b)** ( $\times 20,000$ ). Bar scales, 5  $\mu$ m (Wang et al. 2010) (Reprinted with permission from Springer)



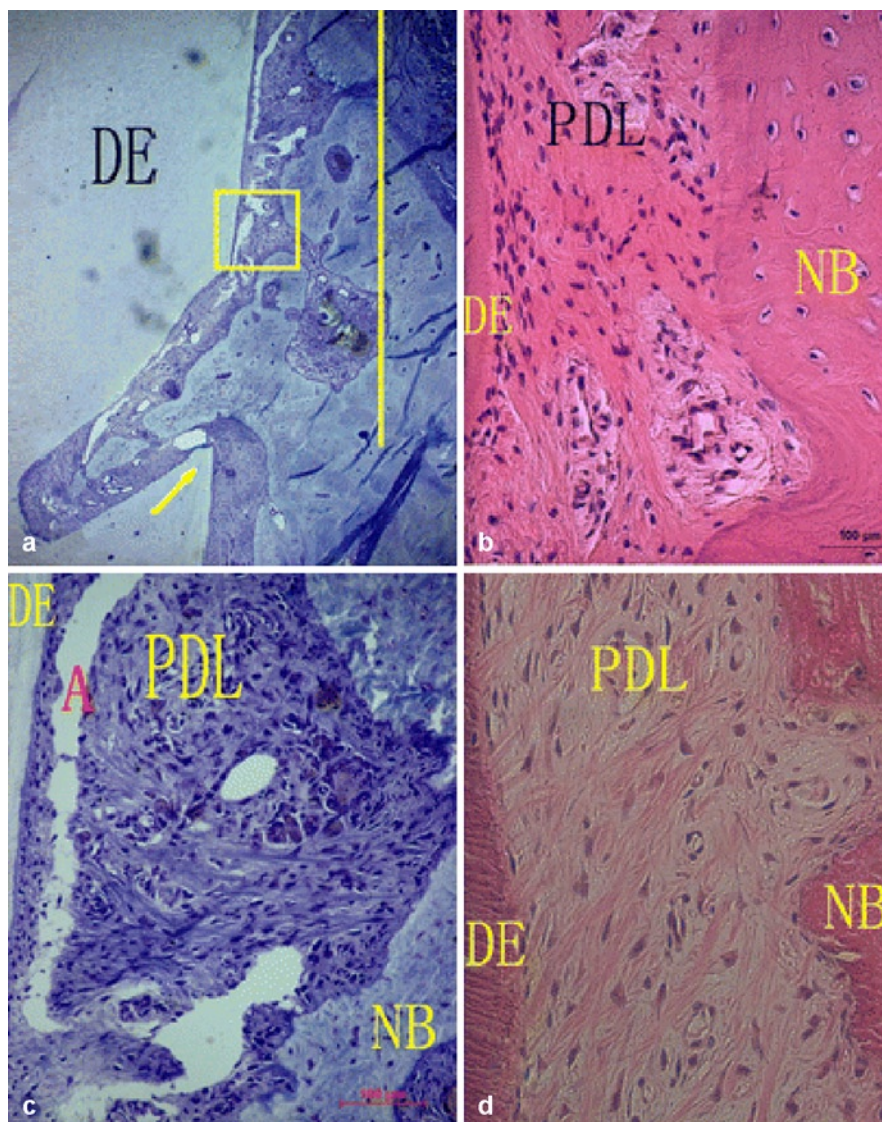
**Fig. 2.24** (continued)

Nery et al. (1992) suggested that higher HA ratio showed accelerated new bone formation and new attachment levels and demonstrated the superiority of using a composite of these two materials over the use of either material alone. This grafting material was used in periodontal, peri-implant and various types of bone defects (Gauthier et al. 1999; Piattelli et al. 1996b; Shi et al. 2008; Zafiropoulos et al. 2007; Schwarz et al. 2007; Jensen et al. 2007; Sculean et al. 2008; Wang et al. 2010; Choi et al. 2010) (Fig. 2.25). The combination of Emdogain with a HA/ $\beta$ -TCP bone substitute did not interfere with the regenerative potential reported for EMD and may result in formation of new cementum with an associated periodontal ligament. However, the combination of Emdogain+HA/ $\beta$ -TCP resulted in no to minimal new bone formation (Sculean et al. 2008). However, it has been showed that HA/ $\beta$ -TCP mixed with autogenous spongiosa treatments produced significantly better outcomes than autogenous spongiosa alone in intrabony tissue regeneration (Zafiropoulos et al. 2007).

Some alloplastic materials are mixed together to achieve superior results. Fortoss<sup>®</sup> Vital (Biocomposites, Staffordshire, UK) is such a mixture of  $\beta$ -TCP and calcium sulfate (Sukumar and Drizhal 2008). Due to modified surface activity and ion loading, its osteoconductive behavior might be superior to conventional calcium phosphates. In contrast to conventional  $\beta$ -TCPs, manufacturing and application of this biphasic calcium composite material use a proprietary process (Zeta Potential Control, Biocomposites) to establish

a negative zeta potential. Based on this concept, the surface of the material will be charged negatively in an aqueous environment (Stein et al. 2009). Zeta potential is an effective predictor of biomaterial attraction to osteoblasts and bone, providing a useful in vitro method for predicting such interactions (Smith et al. 2004; Ohgaki et al. 2001). The application of the  $\beta$ -TCP and calcium sulfate material was well tolerated and led to superior PD and CAL changes compared to open flap debridement for the treatment of intrabony periodontal defects. The clinical benefits of BCC were equivalent to autogenous bone spongiosa (Stein et al. 2009). At 12 months, patients treated with  $\beta$ -TCP and calcium sulfate exhibited a mean PD reduction of  $3.6 \pm 0.7$  mm and a mean CAL gain of  $3.0 \pm 0.8$  mm compared to baseline. Corresponding values for patients treated with autogenous bone spongiosa were  $3.4 \pm 0.8$  mm and  $2.9 \pm 0.9$  mm, whereas open flap debridement sites produced values of  $2.8 \pm 0.8$  mm and  $1.6 \pm 0.7$  mm.

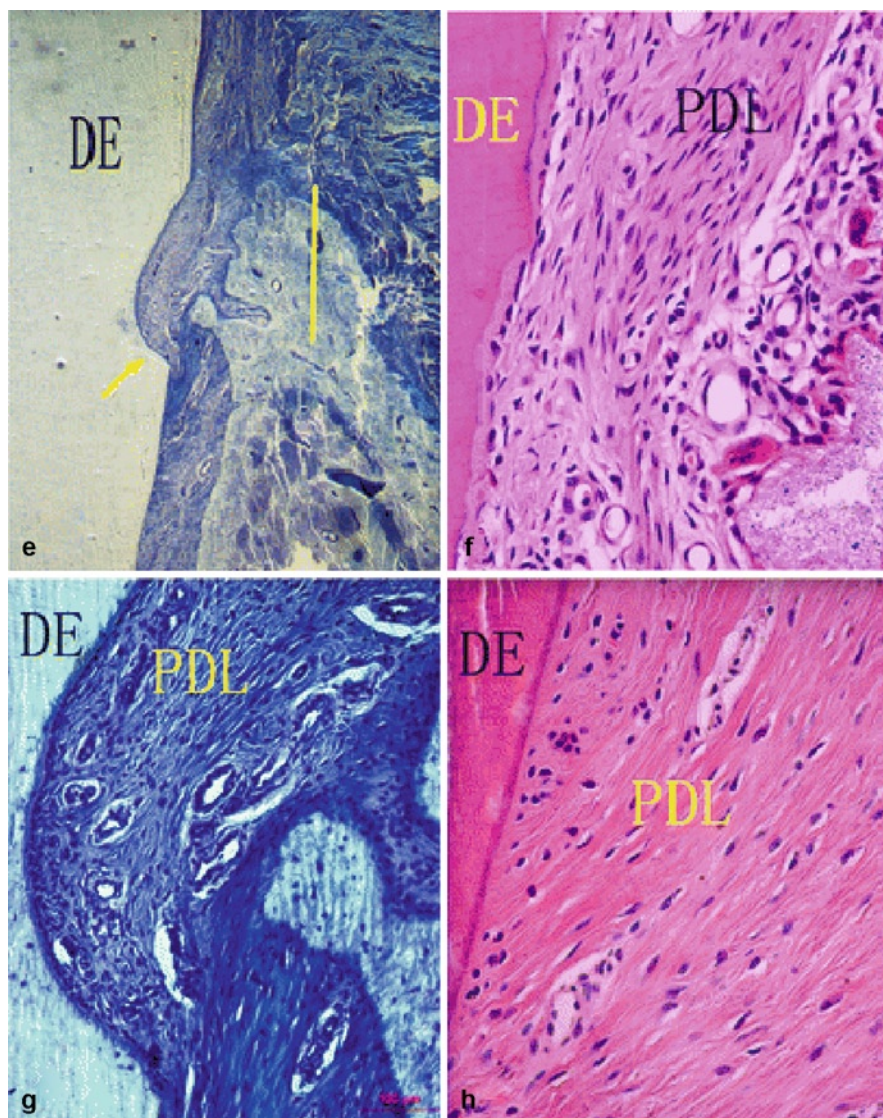
Calcium phosphates can be bound to collagen carriers or mixed with fibrin. The concept is that collagen and fibrin form a network on which minerals can crystallize. Collagen can also bind to extracellular matrix (ECM) proteins of importance in the mineralization process. Healos<sup>®</sup> (Orquest, Mountain View, CA) is a mixture of hydroxyapatite and bovine collagen and Collagraft<sup>®</sup> (Zimmer Corp., Warsaw, IN) is composed of 65% hydroxyapatite and 35% tricalcium phosphate combined with bovine collagen. Tricos<sup>®</sup> is a mixture of hydroxyapatite, tricalcium phosphate and fibrin (Hallman and Thor 2008).



**Fig. 2.25** Photomicrograph of healing of acute alveolar bone dehiscence following treatment with porous biphasic calcium phosphate in beagle dogs. The sections of a, c, e and g were stained with *toluidine blue*; the sections of b, d, f and h were stained with *hematoxylin and eosin* (yellow arrows pointed to the notch, yellow lines marked the height of the new alveolar bone, NB new bone, DE dentin, HB host bone, PDL periodontal ligament); (a) 16 weeks in PBCP: healing resulted in abundant periodontal regeneration ( $\times 40$ ); (b) 12 weeks in PBCP: new collagen fiber bundles mostly inclined to the crown with one end embedded in cementum higher than the other end buried in adjacent bone ( $\times 400$ ); (c) 16 weeks in PBCP, magnified view of yellow rectangle in (a): most fiber bundles aligned in vertical to

the root surface ( $\times 200$ ); (d) 24 weeks of PBCP: new collagen fiber bundles were in functional arrangement at right angles ( $\times 400$ ); (e) 16 weeks in OFD: limited new alveolar bone formed in the defect and covered the notch at most ( $\times 40$ ); (f) 12 weeks in OFD: new mixed cementum without inserting collagen fibers deposited on the root surface in the notch, the new PDL were thin and little, which parallel to the root surface ( $\times 400$ ); (g) 16 weeks in OFD, magnified view of (e), newly formed PDL were parallel to the root surface ( $\times 200$ ); (h) magnified view of normal PDL just below the notch, collagen fiber bundles arranged orderly with one end embedded in cementum lower than the other end buried in adjacent bone at about  $45^\circ$  ( $\times 400$ ) (Wang et al. 2010) (Reprinted with permission from Springer)

Fig. 2.25 (continued)



In the recent years, increased efforts have been focused on understanding the mechanisms of and factors required for restoring periodontal tissues in order to increase the predictability of regenerative therapy. These events are controlled by biological mediators like growth factors, morphogenetic proteins, ECM proteins and others, which are produced by monocytes, platelets and resident tissue cells like PDL cells, osteoblasts, cementoblasts and endothelial cells (Christgau et al. 2006). Several studies have shown that periodontal regeneration may be enhanced by the therapeutic application of specific growth factors to tricalcium phosphates, such as basic fibroblast growth factor (bFGF) (Shirakata et al. 2010), growth/differentiation factor-5 (Kwon et al. 2010) and platelet-derived growth factor (PDGF)

(Nevins et al. 2005a; Sarment et al. 2006; McGuire et al. 2006; Nevins et al. 2007; Yassibag-Berkman et al. 2007; Döri et al. 2008; Ridgway et al. 2008; Mellonig et al. 2009; McGuire et al. 2009a; McGuire et al. 2009b).

#### 2.4.6 Calcium Sulfate

Calcium sulfate, generally known as plaster of Paris, or gypsum, is perhaps, the oldest ceramic bone substitute material. Given the relatively simple chemistry of calcium sulfate, there is less latitude for formulation variation than is the case in the calcium phosphate domain. Traditionally, calcium sulfate hemihydrate ( $\text{CaSO}_4 \times 1/2\text{H}_2\text{O}$ ) powder is hydrated to form calcium sulfate

dihydrate ( $\text{CaSO}_4 \times 2\text{H}_2\text{O}$ ), undergoing a slight exothermic reaction to set to a solid form (Eppley et al. 2005).

Calcium sulfate resorbs quickly, over a period of 12 weeks, by a process of dissolution and is substituted by new bone (Bell 1964). The rapid resorption rate can pose a potential problem because the volume of the graft may not be maintained for a sufficiently long period of time to yield reliable grafting results in the esthetic zone (Hallman and Thor 2008).

Calcium sulfate has been considered inexpensive, readily available, easy to sterilize, safe and simple to use, eliciting little or no macrophagic reaction, does not adversely impact the cell proliferation kinetics (Winn and Hollinger 2000; Hogset and Bredberg 1986) and does not elevate serumcalcium levels (Elkins and Jones 1988).

Calcium sulfate graft material with a patented crystalline structure described as an alphasulfate acts primarily as osteoconductive bone-void filler that completely resorbs as newly formed bone remodels and restores anatomic features and structural properties. (Nandi et al. 2010). Although the exact mechanism of action remains undiscovered, calcium sulfate appears to function as a resorbable osteoconductive scaffold that provides the structural framework necessary for angiogenesis and osteogenesis while preventing soft tissue invasion by acting as a space filler. It was indicated that calcium sulfate pellets placed into a large animal metaphyseal defect was equivalent to autogenous and allogenic bone in terms of bone-volume production and significantly better than the empty control, as evidenced by backscattered electron microscopy. Histologically, the quality of bone formed in defects treated with calcium sulfate was not discernable from that formed when defects were treated with autogenous or allogenic bone. The histological response was characterized by relative completion of bone formation as evidenced by newly remodeled bone (Peters et al. 2006).

Example of commercially available calcium sulfate graft is Capset<sup>®</sup>, Lifecore Biomedical, Chaska, MN. CalForma<sup>™</sup> Calcium Sulfate Bone Graft Barrier is a modification of Lifecore Biomedical's Capset<sup>®</sup> Calcium Sulfate Bone Graft Barrier. The modification is the addition of a small amount of an excipient, HPMC (hydroxypropyl methylcellulose or hypromellose), to the accelerated calcium sulfate in order to improve handling characteristics of the device when used as a barrier over bony defects in dental applications (FDA 2010e). Lifecore Biomedical CalMatrix Calcium Sulfate Bone Graft Binder (CalMatrix) is a calcium sulfate material that contains resorbable

surgical grade plaster of Paris with approximately 10% of a pharmaceutical grade sodium carboxymethylcellulose. CalMatrix and Allomatrix<sup>®</sup> (Wright Medical Technology, Inc) utilize the same calcium sulfate (CS)/CMC blend, except that Allomatrix is provided with human demineralized bone matrix (DBM) already mixed in. CalMatrix is to be mixed with DBM or other bone graft material by the clinician prior to application (FDA 2010e). Currently, medical grade calcium sulfate impregnated with tobramycin is commercially available (Osteoset<sup>®</sup>; Wright Medical Technology, Arlington, TN, USA) (Sukumar and Drízhál 2008). A novel biphasic calcium composite grafting material that consisted of a porous  $\beta$ -tricalcium phosphate and calcium sulfate phase was recently presented (Fortoss Vital, Biocomposites, Keele, UK).

Potential application of calcium sulfate graft material includes the filling of cysts, bone cavities, benign bone lesions and segmental bone defects; expansion of grafts used for spinal fusion; and filling of bone graft harvest sites. Significant loss of its mechanical properties occurs upon its degradation; therefore, it is a questionable choice for load-bearing applications (Nandi et al. 2010). Another indications include also repair of furcation perforations (Rafter et al. 2002).

Because of its beneficial properties, calcium sulfate alone or associated with other types of materials, such as autologous bone, was used in the treatment of periodontal intrabony defects and furcation lesions (Stein et al. 2009; Paolantonio et al. 2008; Orsini et al. 2008; Harris 2004; Aichelmann-Reidy et al. 2004; Maragos et al. 2002; Orsini et al. 2001; Setya and Bissada 1999; Rosen and Reynolds 1999; Kim et al. 1998; DiBattista et al. 1995; Hashimoto 1983; Shaffer and App 1971).

The addition of DFDBA to calcium sulfate significantly enhanced the clinical outcome more than did the calcium sulfate alone (Maragos et al. 2002) or when compared to surgical debridement only (Setya and Bissada 1999; Kim et al. 1998). The ability to mix calcium sulfate with a graft material, such as DFDBA, has a number of distinct advantages. Conceptually, the calcium sulfate carrier should act as a binder to minimize the graft scatter, facilitate graft retention, decrease graft exposure and maintain the space necessary to permit regenerating tissues to occupy the osseous defect. Aichelmann-Reidy et al. (2004) indicate that calcium sulfate, when used as a binder and barrier in combination with DFDBA, supports significant clinical improvement in intrabony defects, as evidenced by reductions in probing depth, gains in clinical attachment level and defect fill and resolution. Calcium

sulfate represents an important alternative to non-resorbable ePTFE barriers in combination with DFDBA for the treatment of intrabony defects, with less morbidity and cost for the patient (Aichelmann-Reidy et al. 2004). No significant differences were seen between calcium sulfate graft and membrane versus guided tissue regeneration with collagen membrane alone (Paolantonio et al. 2008) or between the results obtained using the combination of autogenous bone grafting plus calcium sulfate or autogenous bone grafting with a bioabsorbable membrane (Orsini et al. 2008; Orsini et al. 2001).

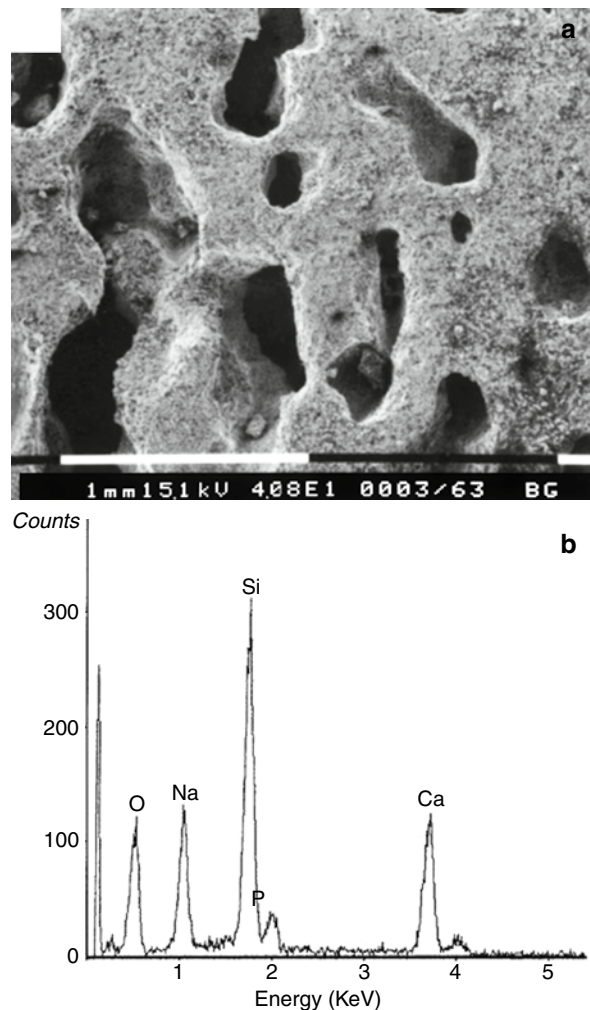
Some alloplastic materials are mixed together to achieve superior results. Fortoss® Vital (Biocomposites, Staffordshire, UK) is such a mixture of beta tricalcium phosphate and calcium sulfate (Sukumar and Drízhal 2008).

### 2.4.7 Bioactive Glasses (BG)

Among the different alloplastic materials used in periodontal therapy, hydroxyapatite, calcium phosphates and bioactive glass ceramics share a common factor, which is their capacity to form a carbonated hydroxyapatite layer on their surfaces once exposed to simulated body fluids or implanted in vivo, hence the concept of “bioactivity.” Since their invention three decades ago by Hench et al. (1971) bioactive glasses have clinically gained wide acceptance in restorative orthopaedics and dentistry (Hattar et al. 2005).

The original composition of bioactive glass approved by the FDA, designated 45 S5, was composed of 46.1 mol% SiO<sub>2</sub>, 26.9 mol% CaO, 24.4 mol% Na<sub>2</sub>O, and 2.5 mol% P<sub>2</sub>O<sub>5</sub>. The original composition and fine structure has been extensively modified in an attempt to further enhance bioactive glass as a bone replacement graft (Reynolds et al. 2010; Hench 2006). When a bioactive glass is implanted in vivo, the pH of the site increases close to 10, a layer rich in silica gel is formed on the surface of the particles and a subsequent calcium phosphate layer is formed by the interaction between calcium and phosphate from the bioactive glass and tissue fluids. The calcium phosphate layer is composed of hydroxycarbonate apatite that is chemically and structurally equivalent to bone mineral composition (Villaça et al. 2005; Hench & Wilson et al. 1984) (Fig. 2.26).

The material is easy to manipulate and it is hemostatic (Wilson and Low 1992; Low et al. 1997; Zamet et al. 1997; Froum et al. 1998; Lovelace et al. 1998; Sculean et al. 2002a). The bioactive glass particles



**Fig. 2.26** Porous structures and chemical composition of glass ceramic: (a) porous structures of glass ceramic under SEM observation and (b) EDX analysis of glass ceramic (Yuan et al. 2001) (Reprinted with permission from John Wiley & Sons)

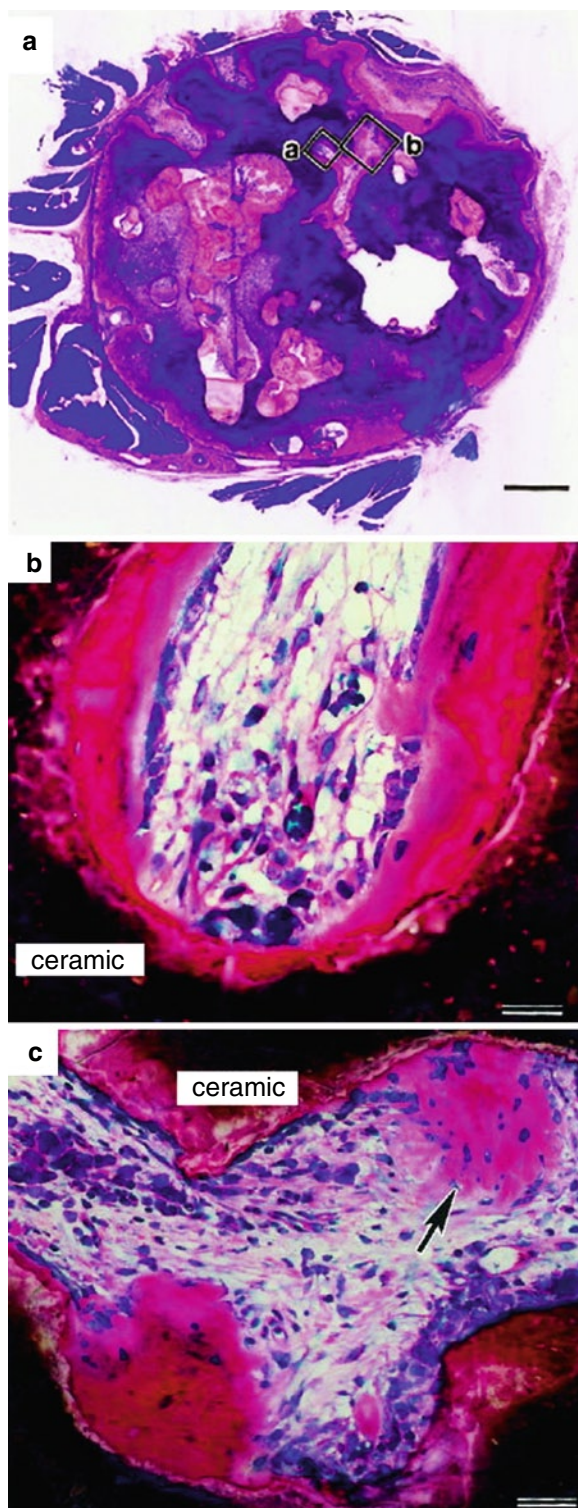
formed a cohesive mass when wetted with blood, which allowed very easy manipulation and packing into the extraction sockets or periodontal defects (Schepers et al. 1998). This transparent bioactive material has proven ability to bond to connective tissue and bone without an intervening fibrous connective tissue interface (Wilson and Low 1992). Upon contact with body fluid, there is an immediate exchange of ions which results in a physiochemical bond between Bioglass, soft tissue and bone. The ion exchange creates an environment resulting in the formation of a hydroxyl-carbonate apatite layer (HCA), a biological apatite identical to the mineral phase of bone, which allows for more rapid repair and regeneration of bone than other synthetic graft materials (Wilson and Low 1992; Shapoff et al. 1997).

It was showed that bioactive glass several **antibacterial effect** against on a large panel of clinically important bacterial species (*A. actinomycetemcomitans*, *P. gingivalis*, *Actinomyces naeslundii*, *Fusobacterium nucleatum*, *Prevotella intermedia*, *Streptococcus mutans*, and *Streptococcus sanguis*, *Candida albicans*) (Stoor et al., 1998; Allan et al., 2001; Allan et al., 2002; Yli-Urpo et al., 2003; Zehnder et al., 2004; Munukka et al., 2008; Hu et al., 2009).

Bioglass is capable of promoting osteoblast cellular proliferation and differentiation (Price et al. 1997; Xynos et al. 2000a; Vrouwenvelder et al. 1993; Xynos et al. 2000b; Hattar et al. 2005; Palmieri et al. 2008) and acts on bone formation by determining both osteoconduction (as demonstrated by the reduced cell adhesion) and osteogenesis (as shown by TGF $\beta$ -related proteins and stem cell markers) (Carinci et al. 2007). Bioactive glass is a particulate bioactive ceramic, which has the ability to bond to bone tissue and enhance bone growth because of its *osteoconductive properties*. In addition to its osteoconductive properties, it also has an *osteostimulatory effect* showing bone growth within eroded particles. These islands of newly formed bone tissue function as nuclei for further bone growth and enhance the repair of osseous defects. This new bone has the histologic and biomechanical properties of surrounding bone as soon as 7 months after grafting (Furusawa et al. 1998; Thronsdon and Sexton 2002) (Fig. 2.27).

Treatment of two-wall intrabony defects in monkeys demonstrated that bioactive glass had better healing potential than debridement only. Bioactive glass showed an inhibitory property on the apical migration of the junctional epithelium. It was observed that in the sites treated with the bioactive glass, the junctional epithelium migrated apically to the level of the particles most coronally located inside the defect, not surpassing this point (Villaça et al. 2005). Karatzas et al. (1999) in a histological study in monkeys reported significantly more new cementum and less epithelial downgrowth in the sites that received bioactive glass. However, in human histological studies, a low potential to facilitate periodontal regeneration was demonstrated as there was minimal new bone formation limited to the most apical borders of the defects. No signs of periodontal regeneration as defined by new cementum, periodontal ligament and bone formation on a previously diseased root surface were observed (Nevins et al. 2000; Sculean et al. 2005c).

In treatment of periodontal intrabony osseous defects or furcation lesions, Bioglass was used either alone (Froum et al. 1998; Ong et al. 1998;



**Fig. 2.27** Histological observation of bone formation induced by glass ceramic: (a) an overview of a histological section (bar=700  $\mu$ m), (b) a high magnification of square a in (a) (bar=50  $\mu$ m), (c) a high magnification of square b in (a) (arrow: intramembranous ossification, bar=100  $\mu$ m) (undecalcified section, methylene blue and basic fuchsin staining) (Yuan et al. 2001) (Reprinted with permission from John Wiley & Sons)

Rosenberg et al. 2000; Park et al. 2001; Zamet et al. 1997; Anderegg et al. 1999; Yukna et al. 2001; Park et al. 2001; Mengel et al. 2003, 2006; Dybvik et al. 2007; Leknes et al. 2009), with GTR membranes (Keles et al. 2006), with platelet-rich plasma (Demir et al. 2007a, 2007b) or with enamel matrix derivative (EMD) (Sculean et al. 2002a, 2005b, 2005c, 2007a; Kuru et al. 2006).

Treatment of intraosseous defects by means of bioactive glass resulted in an improvement of the bony lesion when compared to the OFD procedure. Weighted mean difference in clinical attachment level gain between bioactive glass and OFD was reported to be 1.04 mm (95% CI: 0.31–1.76) by Trombelli et al. (2002) and  $1.05 \pm 1.89$  mm by Reynolds et al. (2003), while for the PD change, the weighted mean difference was 0.6 mm (95% CI: 0.20–1.002) (Trombelli et al. 2002), and  $0.71 \text{ mm} \pm 2.22$  mm (Reynolds et al. 2003), respectively.

Leknes et al. (2009) examined the clinical efficacy of EMD and BG in the treatment of proximal intrabony periodontal defects and to evaluate factors influencing the treatment outcome. The gain in proximal attachment after treating intrabony defects by flap surgery with BCF was significant ( $P=0.004$ ) and twice that following treatment with EMD ( $P=0.056$ ). Patient and site variables affected the clinical outcome differently. Regression analysis revealed that within the EMD group, smoking and tooth mobility negatively influenced the gain of attachment, whereas within the BG group, gingival recession increased with age, increasing cemento-enamel junction to buccal crest distance and increasing mesial-distal width of the defect.

The combination of enamel matrix derivative and bioactive glass does not seem to additionally improve the clinical results when compared with enamel matrix derivative alone (Sculean et al. 2002a; Sculean et al. 2005b; Sculean et al. 2007a). Kuru et al. (2006) reported for both treatments marked clinical and radiographical improvements, but showing that combined treatment seemed to enhance the results in the treatment of wide intrabony defects. The two groups, EMD and EMD+BG, presented a mean pocket reduction of  $5.03 \pm 0.89$  and  $5.73 \pm 0.80$  mm, recession of  $0.97 \pm 0.24$  and  $0.56 \pm 0.18$  mm, relative attachment gain of  $4.06 \pm 1.06$  and  $5.17 \pm 0.85$  mm, and radiographic bone gain of  $2.15 \pm 0.42$  and  $2.76 \pm 0.69$  mm,

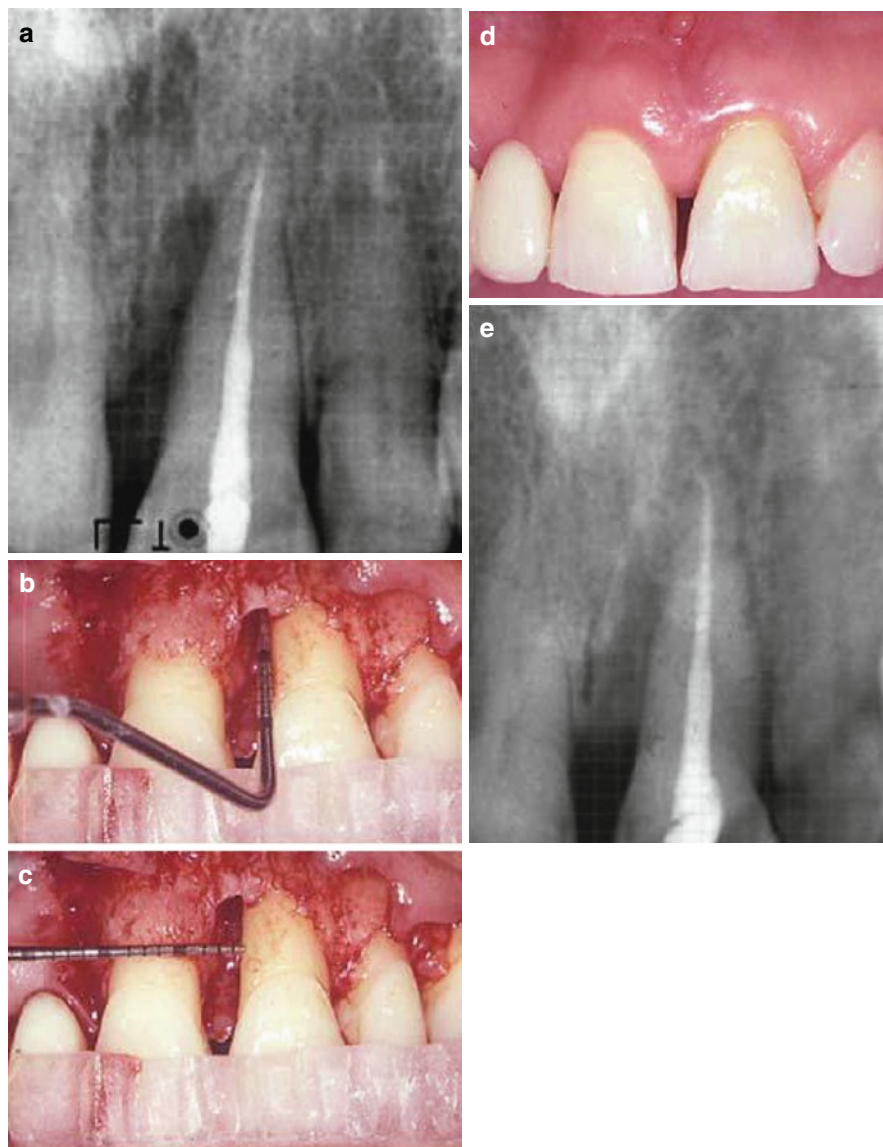
respectively. It was indicated that the clinical improvements obtained with both regenerative modalities can be maintained over a period of 4 years (Sculean et al. 2007a) (Figs. 2.28 and 2.29).

Platelets contain high concentrations of PDGF and TGF- $\beta$  in their  $\alpha$  granules and the preparation of platelet-rich plasma (PRP) seems to be an appropriate and economical method to obtain these growth factors autogenously (Demir et al. 2007a). Demir et al. (2007b) compared the use of either PRP+BG to BG alone in the treatment of patients with interproximal probing depth  $\geq 6$  mm following initial therapy. Clinical parameters were recorded at baseline and repeated 9 months after surgery and surgical reentries were also performed. The results showed that both treatment modalities were effective. Pocket depth reduction of  $3.60 \pm 0.51$  mm, clinical attachment gain of  $3.3 \pm 1.77$  mm and defect fill of  $3.47 \pm 0.53$  mm were noted in the PRP/BG group, with  $3.29 \pm 1.68$ ,  $2.86 \pm 1.56$  and  $3.36 \pm 0.55$  mm improvements, respectively, noted for the BG group. None of the differences between the two treatment modalities were statistically significant.

When the long-term effectiveness of a bioabsorbable membrane and a bioactive glass in the treatment of intrabony defects in patients with generalized aggressive periodontitis was performed, highly significant improvements in the parameters PD and CAL were recorded after 5 years with both regenerative materials. Reduction in PD of  $3.6 \pm 0.8$  mm ( $P=0.016$ ) and a gain in CAL of  $3.0 \pm 2.0$  mm ( $P=0.01$ ) were registered in the membrane group. There was a slight increase in GR by  $0.6 \pm 1.4$  mm ( $P=0.334$ ). In the PG group, a reduction in PD of  $3.5 \pm 1.4$  mm ( $P=0.01$ ) and a gain in CAL of  $3.3 \pm 2.1$  mm ( $P=0.01$ ) were recorded, whereas GR increased by  $0.2 \pm 1.7$  mm ( $P=0.525$ ). Radiographically, the defects were found to be filled significantly more in the bioactive glass group (Mengel et al. 2006). Equal clinical results with bioactive glass and ePTFE barriers in mandibular molar Class II furcations were obtained (Yukna et al. 2001). However, bioactive glass was associated with simpler application and required no additional material removal procedures.

Moreover, in soft and hard tissue measurements, no significant differences were reported between demineralized freeze-dried bone allografts (DFDBA) and BG grafted sites (Lovelace et al. 1998). The results indicated that probing depths were reduced by  $3.07 \pm 0.80$  mm with the bioactive glass and

**Fig. 2.28** Enamel matrix derivative in combination with a bioactive glass in wide intrabony defects. **(a)** A preoperative radiograph revealing the presence of an intrabony defect. **(b)** Intrabony component of the defect. **(c)** The horizontal width of the defect. **(d)** The clinical appearance of the defect filled with the combination of enamel matrix derivative and bioactive glass at 8 months. **(e)** Radiographic appearance at 8 months postoperatively (Kuru et al. 2006) (Reprinted with permission from Springer)

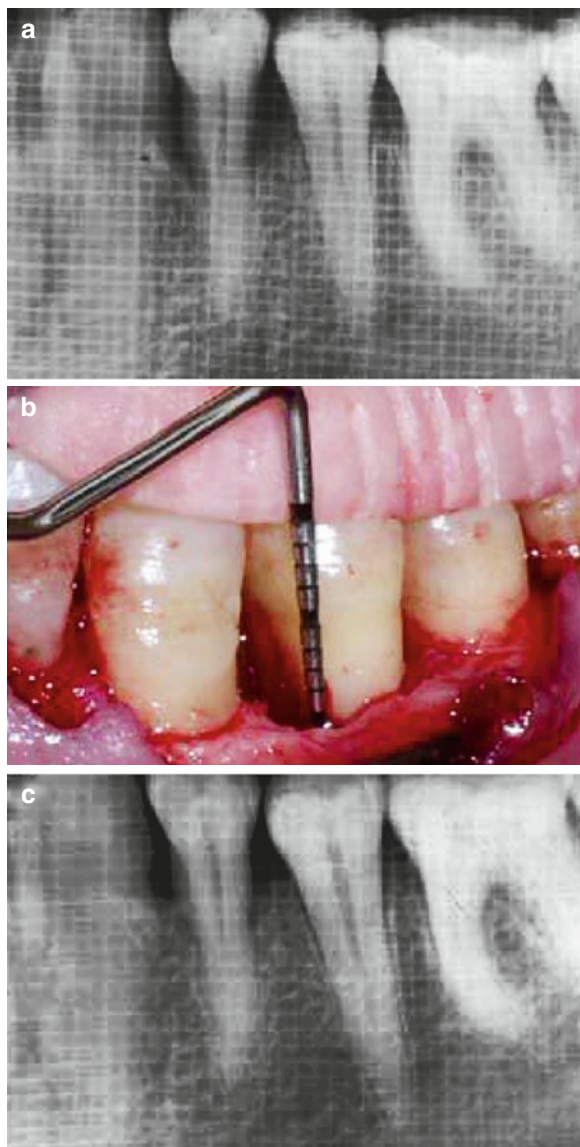


$2.60 \pm 1.40$  mm with DFDBA. Sites grafted with bioactive glass resulted in  $2.27 \pm 0.88$  mm attachment level gain, while sites grafted with DFDBA had a  $1.93 \pm 1.33$  mm gain in attachment. Bioactive glass sites displayed  $0.53 \pm 0.64$  mm of crestal resorption and 2.73 mm bone fill. DFDBA-grafted sites experienced  $0.80 \pm 0.56$  mm of crestal resorption and 2.80 mm defect fill. The use of bioactive glass resulted in 61.8% bone fill and 73.33% defect resolution. DFDBA-grafted defects showed similar results, with 62.5% bone fill and 80.87% defect resolution. Both treatments pro-

vided soft and hard tissue improvements when compared to baseline ( $P \leq 0.0001$ ).

The significant base of scientific studies conducted using Bioglass, along with the required biocompatibility and toxicology studies required by the regulatory bodies have provided a strong basis for establishing the safety of Bioglass devices placed into commerce (Hench 2006).

While the second-generation Bioglass materials performed admirably in replacing diseased or missing hard tissue, the discoveries that Bioglass could



**Fig. 2.29** Enamel matrix derivative alone in wide intrabony defects. (a) A preoperative radiographic appearance. (b) Intrabony component of the defect. (c) At 8 months after treatment with enamel matrix derivative (Kuru et al. 2006) (Reprinted with permission from Springer)

positively affect osteoblasts, and in fact “stimulate” them to produce more bone tissue earlier than other synthetic biomaterials led to the concept of “osteoproduction” and “osteostimulation.” In order to take advantage of this property, and of the need to regenerate diseased or missing tissues, the development of third-generation Bioglass products focused on

using particles rather than monolithic shapes. The products are being manufactured and sold to the clinic under the name NovaBone (Hench 2006).

The first NovaBone particulate material cleared for sale in the USA was Perioglas<sup>®</sup>, which was cleared via the 510[k] process in December, 1993. In 1995, PerioGlas obtained a CE Mark and marketing of the product began in Europe. The initial indication for the product was to restore bone loss resulting from periodontal disease in infrabony defects. In 1996, additional indications for use were cleared by FDA, including use in tooth extraction sites and for alveolar ridge augmentation (Hench 2006).

*PerioGlas<sup>®</sup>* (Block Drug Co., NJ, USA) is a synthetic absorbable osteoconductive bone graft substitute composed of a calcium phosphosilicate bioactive glass, Bioglass. The device is in a particulate form of a size range 90–710  $\mu\text{m}$ . The device is intended for dental intraosseous, oral and cranio-/maxillofacial bony defects. It is supplied sterile, packaged either in a Tyvek-sealed PET-G cup or in a filled syringe within a second sterile barrier package. The device packages are protected by an outer shrink-wrapped cardboard box. At time of use, the device is mixed with sterile water, saline, the patient’s own blood or marrow or with autogenous or allograft bone to form a wet sandy paste that is applied to the defect (FDA 2010a).

*PerioGlas<sup>®</sup> Plus* (Block Drug Co., NJ, USA) is a synthetic resorbable osteoconductive bone graft substitute composed of a calcium phosphosilicate material and a calcium sulfate binder. The device is intended for dental intraosseous, oral and maxillofacial bony defects. The inorganic calcium and phosphorous components are thermally incorporated in a sodium silicate network (*PerioGlas<sup>®</sup>*) designed specifically for its absorbability and osteoconductive nature. The calcium sulfate component binds the *PerioGlas<sup>®</sup>* particles together at the time of implantation and is absorbed from the graft site over the first several weeks following implantation. On absorption of the calcium sulfate, the *PerioGlas<sup>®</sup>* particles remain in the graft site and are progressively absorbed and replaced by host bone during the healing process (FDA 2010b).

The main technological characteristic difference between *PerioGlas<sup>®</sup> Plus* and the predicate devices is their composition. *PerioGlas<sup>®</sup>* is composed of particulate Bioglass. Capset (Lifecore Biomedical,

Chaska, MN) is composed of powdered calcium sulfate hemihydrate which, when combined with an aqueous-based setting solution, is chemically converted to calcium sulfate dihydrate. PerioGlas® Plus is composed of particulate Bioglass and powdered calcium sulfate hemihydrate; when mixed with water, the hemihydrate is chemically converted to calcium sulfate dihydrate and acts as a binder for the Bioglass particles. The calcium sulfate in the PerioGlas® Plus and Capset devices is absorbed between 4 and 8 weeks after implantation, depending on the graft site, size and material used. The particulate Bioglass in the PerioGlas® Plus device is identical to that in the PerioGlas® predicate, being substantially absorbed within the 6-month time frame normally associated with bone remodeling. For all three devices, bone forms throughout the graft site with the material being absorbed and replaced by new bone tissue (FDA 2010b).

*Biogran*™ (Orthovita Inc., Malvern, PA, USA) is a particulate bioactive glass, which has been used in a few experimental and clinical studies for the treatment of different types of bone defect. BioGran™ is a resorbable bone graft material consisting of 300–355 µm diameter bioactive glass particle size. It has the ability to bond to soft and bone tissue and, in addition, it enhances bone tissue growth due to its osteoconductive properties (Scheepers et al. 1991, 1993; Kontonasaki et al. 2007).

*Unigraft*® (Unicare Biomedical Inc., Laguna Hills, CA, USA) is a synthetic bioactive glass that is intended to use in the repair oral/maxillofacial and dental intraosseous defects. The bioactive glass (CaO, Na<sub>2</sub>O, P<sub>2</sub>O<sub>5</sub> and SiO<sub>2</sub>) used in Unigraft® is manufactured as irregular-shaped synthetic granules, sized from about 200 µm to about 420 µm. It is supplied sterile in foil-sealed polyolefin vial. The product is to be mixed with sterile saline or with patient's blood to form a sandy paste that is to be applied to the defect (FDA 2010c).

More recently, Bioglass particulate has been used for the treatment of dentinal hypersensitivity. Tooth hypersensitivity is a problem that affects an estimated 15–20% of the population of the USA, and similar numbers in Europe. Tooth hypersensitivity occurs when the root portion of the tooth, which is dentin, becomes exposed around the gum line. The dentin has small openings, or tubules, that communicate with the

pulp chamber. If the dentinal tubules become exposed, hot or cold or pressure can transmit the sensations to the nerves in the pulp, causing pain. The Bioglass material used in this application is a very fine particulate that is incorporated into toothpaste, or used with an aqueous vehicle and applied to the tooth surface around exposed root dentin. When Bioglass particles are put in contact with dentin, they adhere to the surface, rapidly form a hydroxycarbonate apatite layer and occlude the tubules, thereby relieving the pain (Hench 2006). Studies have shown that the Bioglass particulate could produce considerable sealing depth in dentinal tubules with the potential of prolonging the therapeutic effect efficaciously (Curtis et al. 2010; Chiang et al. 2010; Lee et al. 2007; Lee et al. 2005; Kuo et al. 2007).

Other dental and maxillofacial applications include pulp capping (Stanley et al. 2001; Oguntebi et al. 1993), for bone formation in combination with implants and sinus lift procedures (Govindaraj et al. 1999; Browaeys et al. 2007; Precheur et al. 2007), including its use in solid root form in extraction sockets as endogenous ridge maintenance implants (Stanley et al. 1987; Wilson et al. 1993a; Kirsh and Garg 1994), for filling oral cystic cavities or after apicoectomies (Shapoff et al. 1997).

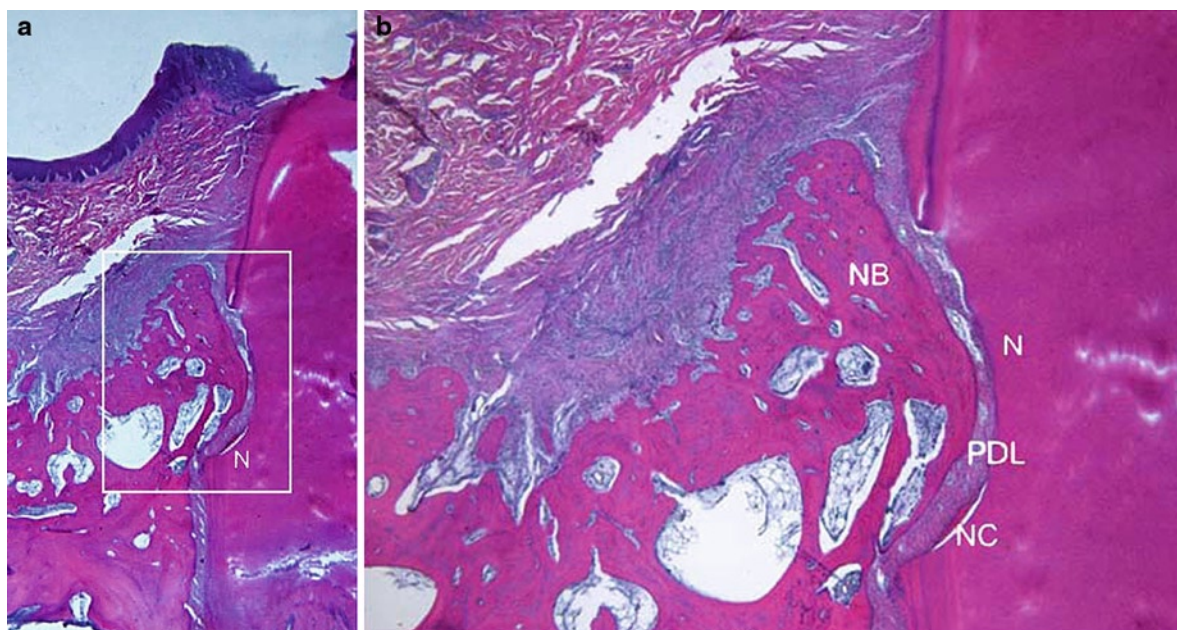
#### 2.4.8 Oily CaOH<sub>2</sub> Suspension

Calcium hydroxide (CaOH<sub>2</sub>) is a product of lime slaking from quicklime (CaO) and is used extensively in endodontics, combined with various vehicles for indirect and direct pulp-capping procedures and as a temporary root-filling material, where it has been shown to support hard tissue repair. Recently, a non-setting oily CaOH<sub>2</sub> suspension (OCHS; Osteoinductal®, Osteoinductal GmbH, Munich, Germany) has been introduced into the market for application in jaw-bone surgery. This formulation contains, apart from CaOH<sub>2</sub>, *liquid and solid carbohydrate chains and various fatty acids (e.g., oleic, palmitoleinic, gadoleinic, margarine, pentadecane, myristic, linolenic, stearic, arachidic, lauric) esterified with glycerol, while the oily part consists of a natural product of porcine origin, oleum pedum and vaselinum album* (Stavropoulos et al. 2007).

Results from pilot studies in *experimental animals* suggest that OCHS may accelerate bone healing and promote periodontal regeneration (Ito et al. 2002; Schwarz et al. 2006b). In a study in rats, Ito et al. (2002) compared the healing in OCHS-filled extraction sockets with that in sockets left untreated to serve as controls. The authors reported that after 1 month of healing, the sockets previously filled with OCHS showed statistically significantly larger amounts of bone fill than the controls. In dogs, three-wall intrabony periodontal defects were bilaterally produced and were randomly treated with both access flap surgery and the application of OCHS or access flap surgery alone. After 2 months of healing, larger amounts of regenerated bone and newly formed cementum were observed in the sites treated with OCHS than that found in the control sites, in which healing was predominantly characterized by the formation of a long junctional epithelium along the previously denuded root surface and only minimal bone regeneration (Schwarz et al. 2006b) (Fig. 2.30). In contrast with the previous reports, Stavropoulos et al. (2007) clearly demonstrated in an experimental study in rats that

OCHS does not promote bone formation when used as an adjunct to GBR, but on the contrary it may hamper it. It was also indicated that the use of the calcium hydroxide suspension. Osteoinductal has a detrimental effect on wound healing and osseointegration of dental implants and cannot be recommended for use with dental implants (Kohal et al. 1997). An *in vitro* study indicated that Osteoinductal enhances the mitogenic response of human PDL cells by activation of ERK1/2 and increases cell proliferation; however, it is inferior in comparison to EMD (Kasaj et al. 2007).

Recent clinical studies have shown that an oily calcium hydroxide suspension, applied to the root surface in conjunction with surgical periodontal therapy, may promote periodontal regeneration (Stratul 2003; Stratul and Sculean 2004; Stratul et al. 2006). OCHS resulted in statistically significant higher pocket depth reductions and clinical attachment level gains than access flap surgery alone. At 6 months after surgery, the test group showed a reduction in mean PD from  $7.7 \pm 1.5$  to  $2.9 \pm 0.9$  mm ( $P < 0.001$ ) and a change in mean CAL from  $9.6 \pm 2.1$  to  $5.5 \pm 2.5$  mm ( $P < 0.001$ ). In the control group, the mean PD was reduced from



**Fig. 2.30** Effect of an oily calcium hydroxide suspension (Osteoinductal) on healing of intrabony periodontal defects in dogs. (a) Histological view of specimen 1 following application of oily calcium hydroxide suspension (OHCS) showing periodontal regeneration (magnification  $\times 1.25$ ). (b) Higher magnifi-

cation of the regenerated area shown in a demonstrated formation of cementum, periodontal ligament and alveolar bone (magnification  $\times 4$ ) (Schwarz et al. 2006b) (Reprinted with permission from Springer)

6.9±0.9 to 3.7±0.9 mm ( $P<0.001$ ) and the mean CAL changed from 8.5±2.5 to 6.4±2.7 mm ( $P<0.001$ ) (Stratul et al. 2006).

It has been also shown that the topical subgingival application of an oily calcium hydroxide suspension (Osteoinductal) after nonsurgical periodontal therapy improved early periodontal wound healing. The application of Osteoinductal resulted in significantly greater improvement in gingival and bleeding indices in experimental versus control sites at the 1-, 2- and 3-week examinations. In addition, no side effects like inflammation or pain were reported at sites subjected to Osteoinductal application (Kasaj et al. 2006).

### 2.4.9 Porous Titanium Granules

Recently, a non-resorbable, osteoconductive bone substitute, was proposed to be used in stabilization of hip prostheses (Alffram et al. 2007; Turner et al. 2007), in connection with surgery of compression fractures in the lateral tibial plateau (Jónsson and Mjöberg 2009), in cases with large cystic cavities (Magistri et al. 2006), in patients planned for augmentation of the sinus floor prior to or in conjunction with placement of dental implants (Holmberg et al. 2008; Bystedt and Rasmusson 2009; Bystedt 2007) and in the surgical treatment of peri-implant osseous defects (Wohlfahrt et al. 2010c; Frei et al. 2010; Bergmann 2010).

Tigran™ PTG (Natix, Tigran Technologies AB, Malmö, Sweden) is irregularly shaped and porous granules manufactured using commercially pure titanium. The granules are between 0.7 mm and 1.0 mm. When they are mixed with the patient's blood or with a saline solution, the granules attach to each other due to the capillary force. The titanium surface is very thrombogenic, which facilitates the formation of stabilizing blood clots around the granules. The granules that have a porosity of about 80% and an osteoconductive surface structure, imitate properties of human bone, and create a scaffolding for bone generation that stimulates osteoblast colonization and osseointegration. The granules are non-resorbable and keep their volume during the operation and the entire healing period which ensures mechanical stability and a desired aesthetic result. Tigran™ PTG is easy to use. No special tools are needed. When osseointegration is completed, common drilling techniques are used when an implant has to be placed in the treated area (<http://www.tigran.se/>

[en/professional/products/tigrantm-ptg/](http://www.tigran.se/en/professional/products/tigrantm-ptg/)). The titanium granules do not set (i.e., no risk of heat injury to the bone) and can therefore be handled without time pressure during surgery (Jónsson and Mjöberg 2009).

Tigran's porous titanium granules have been demonstrated experimentally to have superior microstructural properties (porosity, interconnectivity, open pore size and surface area-to-volume ratio), cell viability and proliferation rate compared to both Straumann BoneCeramic and Geistlich Bio-Oss (Sabetrasekh et al. 2010).

Histological examination in an animal model revealed, 6 months after implantation, lamellar bone formation through the mantle of porous titanium granules in continuity with the surrounding cortex resulting in the formation of an integrated mantle of bone and titanium granulate around the prosthesis (Turner et al. 2007). When used calibrated defects prepared in the tibias of New Zealand rabbits, both metallic and oxidized porous titanium granules demonstrated osteoconductive properties that can be used to promote bone formation in osseous defects adjacent to titanium implants without hampering implant osseointegration (Wohlfahrt et al. 2010a). A randomized animal experiment has indicated that degree II furcation defects in minipigs grafted with PTG demonstrated significantly better osseous regeneration compared bovine hydroxyapatite (Bio-Oss) grafted defects. No significant signs of adverse events were seen in any of the treatment groups (Wohlfahrt et al. 2010b).

No randomized clinical trials are presently available regarding the efficacy of porous titanium granules in the treatment of periodontal defects.

## 2.5 Composite Grafts

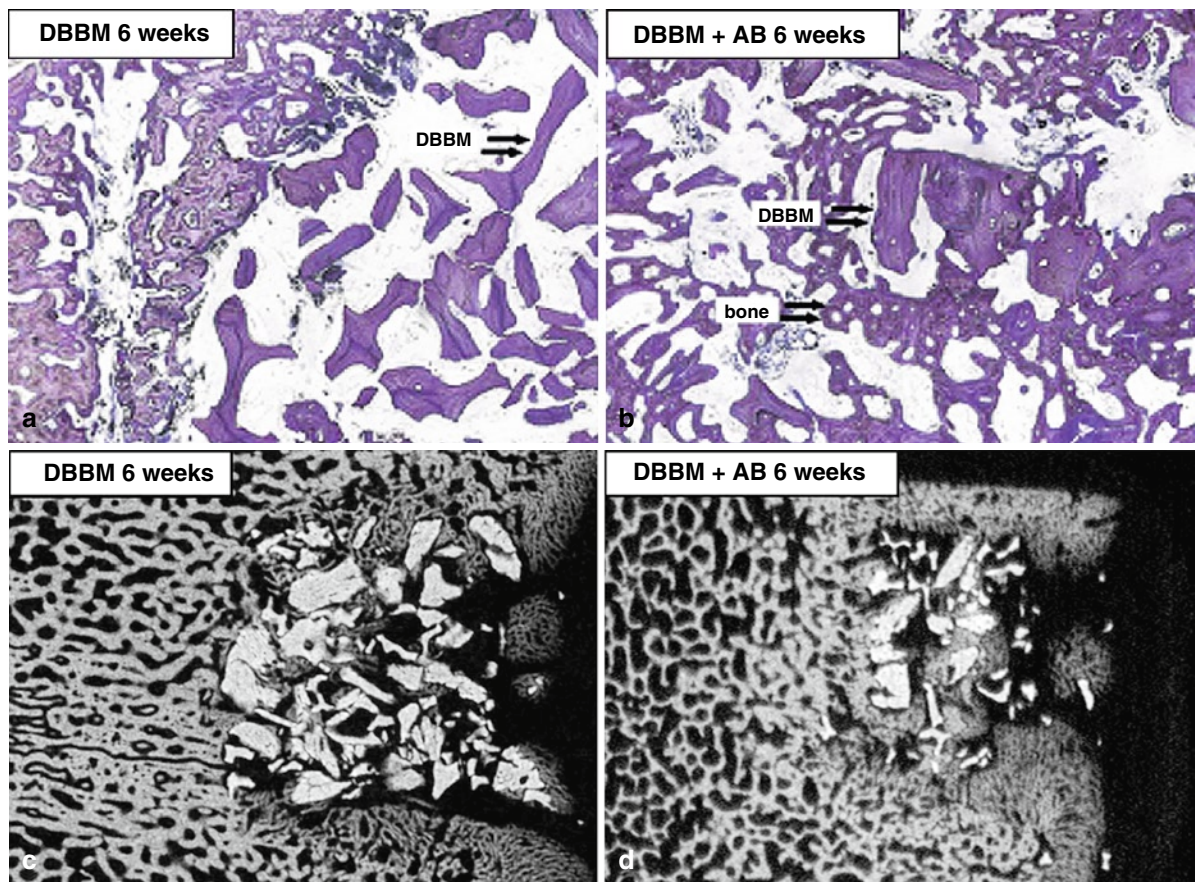
One of the most promising emerging surgical options may be the use of a "composite graft" that contains osteogenic cells and osteoinductive growth factors along with a synthetic osteoconductive matrix. Composite materials being tested in preclinical and clinical trials may exhibit functionality comparable to autograft and allograft. Composite synthetic grafts offer an alternative that can potentially unite the three essential bone-forming properties in more controlled and effective combinations without the disadvantages found with autograft. A composite graft combines an osteoconductive matrix with bioactive agents that provide osteoinductive and osteogenic properties, potentially replicating autograft functionality. The osteoconductive matrix becomes a delivery system

for bioactive agents, requiring less chemotaxis and less migration of osteoblast progenitor cells to the graft site. The direct infusion of progenitor cells should lead to more rapid and consistent bone recovery. When an osteoconductive scaffold is seeded with bone morphogenetic proteins, for example, the composite graft may become both osteogenic and osteoinductive, providing a competitive alternative to autograft (Giannoudis et al. 2005; De Long et al. 2007). Such potential composite grafts are: bone marrow/synthetic composites, ultraporous  $\beta$ -TCP/BMA composite, osteoinductive growth factors and synthetic composites, BMP/polyglycolic acid polymer-composites and BMA/BMP/polyglycolic acid polymer-composite (Giannoudis et al. 2005).

Some of the commercially available composite grafts that are commonly used are Healos<sup>®</sup> (Orquest, Mountain View, CA), Collagraft<sup>®</sup> (Zimmer Corp, Warsaw, IN)

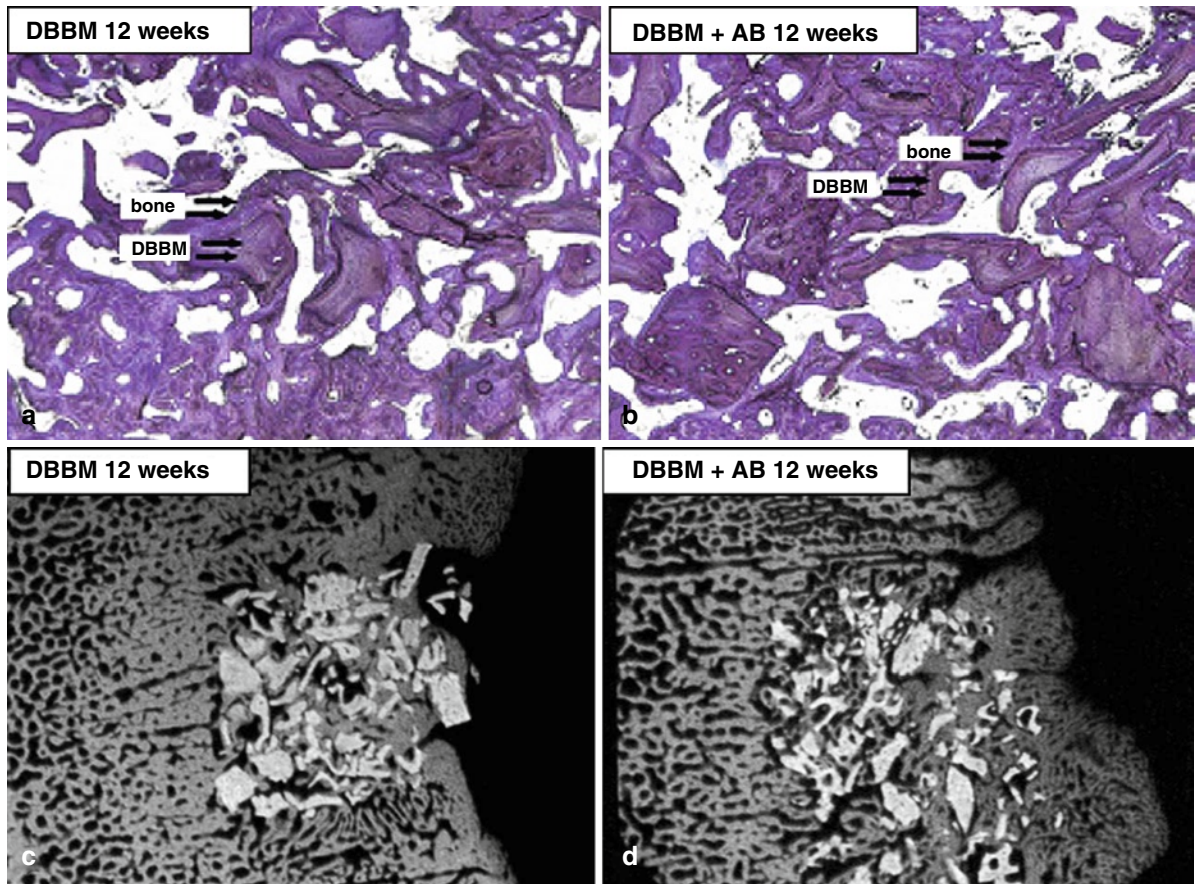
and Tricos<sup>®</sup> (Baxter BioSciences BioSurgery) ceramics (Biomatlante manufacturer, Vigneux de Bretagne, France).

Limited clinical data exist on the use of composite grafts in the treatment of periodontal defects (Sanders et al. 1983; Sottosanti 1993; Sottosanti 1995; Anson 1996; Anson 1998; Harris 2004; Harris 1998; Orsini et al. 2001; Maragos et al. 2002; Okuda et al. 2005; Orsini et al. 2008). Alloplasts can be mixed with autogenous grafts or allografts in the management of large structural defects (Zafiroopoulos et al. 2007). It was suggested that a mixture of autogenous bone and these materials should be used to overcome the lack of osseointegration of xenografts and alloplastic materials and to reduce the amount of bone resorption observed with pure autogenous grafts (Figs. 2.31 and 2.32). Thorwarth et al. (2006) demonstrated an accelerating



**Fig. 2.31** De novo bone formation following application of autogenous bone to particulated anorganic bovine material in vivo. (a, b) Light microscopy at 6 weeks (toluidine blue O staining, magnification 35). (a) Group A=DBBM. (b) Group

B=DBBM 1.25% particulated AB. (c, d) Corresponding micro-radiographic images, enhanced de novo bone formation due to addition of particulated autogenous bone in group B (Thorwarth et al. 2006) (Reprinted with permission from Elsevier)



**Fig. 2.32** De novo bone formation following application of autogenous bone to particulated anorganic bovine material in vivo. (a, b) Light microscopy at 12 weeks (toluidine blue O staining, magnification 35). (a) Group A = deproteinized bovine

bone matrix (DBBM). (b) Group B = DBBM + 25% particulated autogenous bone (AB). (c, d) Corresponding microradiographic images, adjustment of bone formation in both groups (Thorwarth et al. 2006) (Reprinted with permission from Elsevier)

effect of autogenous bone on bone formation in combination with deproteinized bovine bone matrix. This effect is likely caused by osteoinductive properties of cellular elements transplanted with the autogenous bone. It was also concluded that 25% autogenous bone was a sufficient volume to meet this accelerating effect on bone formation (Thorwarth et al. 2006). In deep intrabony defects treatment, at 12 months evaluation, the combined use of autogenous spongiosa with bovine-derived xenograft or with HA/ $\beta$ -TCP led to significantly greater gain of clinical attachment and hard tissue formation compared to the use of autogenous spongiosa alone (Zafiroopoulos et al. 2007).

In addition to these materials, research is continuing to modify the products with hopes of creating a graft that incorporates faster, resorbs and yields a bony union that resembles natural form and structure (Kuo et al. 2007).

## 2.6 Factors Impacting Treatment Outcome

### 2.6.1 Criteria for Evaluation of Graft Success for Periodontal Regeneration

For any graft material to be considered as a successful regenerative material, it should have clear histological, clinical and radiographic evidence of the following criteria (AlGhamdi et al. 2010a):

1. Biologic acceptability: the graft should not have any side effects or cause any unwanted tissue reaction.
2. Resorbability: the graft should resorb slowly and be replaced by the patient's own bone.

3. Regeneration: the graft should have evidence of regenerative ability with formation of new bone, cementum and periodontal ligament fibers.
4. Defect fill: the graft should have evidence of bone fill.
5. Stability: the outcome of the treatment should be stable at reevaluation visits.

## 2.6.2 Factors Influencing Graft Success

Several studies have investigated the possible sources of variability in the clinical outcomes of bone grafting procedures in periodontal surgery: (1) the patient, (2) the morphology of the defect, (3) the graft material, (4) the surgical procedure and (5) the healing period (Cortellini and Tonetti 2000; AlGhamdi et al. 2010a).

### 2.6.2.1 Patient Factors

The scientific literature clearly shows that plaque control (Cortellini et al. 1994), residual periodontal infection, tobacco smoking (Tonetti et al. 1995) and the patient's compliance (Wilson et al. 1984; Wilson et al. 1993b) are important prognostic factors in regenerative periodontal therapy. Other factors include conditions such as diabetes, hyperparathyroidism, thyrotoxicosis, osteomalacia, osteoporosis, Paget's disease and some medications may all affect the healing process (AlGhamdi et al. 2010a).

### 2.6.2.2 The Morphology of the Defect

Among the defect anatomy-associated factors, depth of the intrabony component of the defect and/or probing depth is consistently found to be relevant (Tonetti et al. 1996; Tonetti et al. 1998; Cortellini et al. 2001). The number of residual bony walls defining the defect seems to affect outcomes. Defects with two and three bony walls respond more favorably to treatment than do one-wall defects (Froum et al. 1976; Sepe et al. 1978). Also periodontal regeneration was more successful in deep-narrow defects than in shallow-wide defects (Dragoo and Sullivan 1973a; Froum et al. 1976; Mellonig 1984).

### 2.6.2.3 Selection of Graft Material

When bony reconstruction is presented to the surgeon, many choices must be weighed before the proper graft material is chosen (Kuo et al. 2007). Selection of graft material is guided by:

1. Biologic acceptability
2. Predictability
3. Resorbability
4. Clinical feasibility
5. Minimal operative hazards
6. Minimal postoperative sequelae
7. Patient acceptance (AlGhamdi et al. 2010a and references therein)

A range of 125–1,000  $\mu\text{m}$  is acceptable with 250–750  $\mu\text{m}$  most commonly available for particle size of grafts used in periodontal treatment. A minimal pore size of 100  $\mu\text{m}$  is needed between particles to allow vascularization and bone formation. Particles less than 100  $\mu\text{m}$  in size elicit a macrophage response and are rapidly resorbed with little or no new bone formation (Zaner and Yukna 1984; AlGhamdi et al. 2010a).

### 2.6.2.4 The Surgical Procedure

The surgical technique for the treatment of periodontal intrabony defects with bone replacement grafts is essentially the same regardless of the type of graft material being used. Incisions are designed to allow for primary closure of flaps to protect the graft site from infection and the graft material from displacement. Intrasulcular incisions are the common choice, with emphasis on preserving interdental tissue. Flaps are reflected full thickness to expose the underlying osseous defects and allow access for thorough debridement of the defects and meticulous root planning (Hanes, 2007). New surgical techniques have been developed to optimize primary closure as well as to minimize the surgical trauma in the reconstructive procedures of periodontal intraosseous defects. Recently, we proposed a minimally invasive procedure, the single-flap approach (SFA), specifically indicated when the defect extension is prevalent on the buccal or oral side. The basic principle of the SFA is the elevation of a flap to access the defect only on one side (buccal or oral), leaving the opposite side intact (Trombelli et al. 2009; Trombelli et al. 2010).

Once the defect has been debrided of soft tissue and the tooth root surfaces thoroughly planed to remove all deposits of dental plaque and calculus, the bone replacement graft material is packed into the defect to fill the defect to the level of the remaining alveolar bone (Hanes, 2007). Space maintenance is paramount to bone formation. If the graft material resorbs too rapidly, compared with the time required for bone formation, the site may fill with connective tissue rather than bone (AlGhamdi et al. 2010a). Therefore the space or contour and size of the augmentation should be maintained until the graft has formed enough bone to maintain the space itself (AlGhamdi et al. 2010a; Misch 1999; Polimeni et al. 2006). Absolute graft immobility is paramount to its union to the recipient bone. If pieces of bone graft are mobile, they cannot receive a blood supply, become encapsulated in fibrous tissue and often sequestrate (AlGhamdi et al. 2010a; Lin et al. 1990).

Flaps are closed and sutured for primary closure and complete coverage of the bone replacement graft (Hanes, 2007). Sutures should be removed in 7–10 days.

### 2.6.2.5 The Postsurgical Healing Period

Postsurgical care should include twice-daily rinsing with 0.12% chlorhexidine gluconate for 2 weeks and gentle toothbrushing starting 1 week after the surgery. Systemic antibiotics may be prescribed for 7–10 days after the surgical procedure. Patients should be seen at intervals of 1 week, 2 weeks and 4 weeks after surgery for supragingival plaque removal and then should be placed on a periodontal maintenance schedule at 3-month intervals (Hanes, 2007).

Adequate healing time must be provided to allow regeneration of the new bone volume. The amount of time required is variable and depends on local factors such as the number of remaining walls of bone, the amount of autogenous bone in the graft and the size of the defect. Larger grafts, less autogenous bone in the graft and fewer bony walls increase the amount of healing time (AlGhamdi et al. 2010a; Misch and Dietsch 1993; Misch 1999).

## References

- Aichelmann-Reidy ME, Yukna RA (1998) Bone replacement grafts. The bone substitutes. *Dent Clin North Am* 42: 491–503
- Aichelmann-Reidy ME, Heath CD, Reynolds MA (2004) Clinical evaluation of calcium sulfate in combination with demineralized freeze-dried bone allograft for the treatment of human intraosseous defects. *J Periodontol* 75:340–347
- Al Ruhaimi KA (2001) Bone graft substitutes: a comparative qualitative histologic review of current osteoconductive grafting materials. *Int J Oral Maxillofac Implants* 16:105–114
- Alffram PA, Bruce L, Bjursten LM, Urban RM, Andersson GB (2007) Implantation of the femoral stem into a bed of titanium granules using vibration: a pilot study of a new method for prosthetic fixation in 5 patients followed for up to 15 years. *Ups J Med Sci* 112:183–189
- AlGhamdi AS, Shibly O, Ciancio SG (2010a) Osseous grafting part I: autografts and allografts for periodontal regeneration—a literature review. *J Int Acad Periodontol* 12:34–38
- AlGhamdi AS, Shibly O, Ciancio SG (2010b) Osseous grafting part II: xenografts and alloplasts for periodontal regeneration—a literature review. *J Int Acad Periodontol* 12: 39–44
- Allan I, Newman H, Wilson M (2001) Antibacterial activity of particulate bioglass against supra- and subgingival bacteria. *Biomaterials* 22:1683–1687
- Allan I, Newman H, Wilson M (2002) Particulate Bioglass reduces the viability of bacterial biofilms formed on its surface in an in vitro model. *Clin Oral Implants Res* 13:53–58
- Altieri ET, Reeve CM, Sheridan PJ (1979) Lyophilized bone allografts in periodontal intraosseous defects. *J Periodontol* 50:510–519
- Ambard AJ, Mueninghoff L (2006) Calcium phosphate cement: review of mechanical and biological properties. *J Prosthodont* 15:321–328
- Anderegg CR, Alexander DC, Freidman M (1999) A bioactive glass particulate in the treatment of molar furcation invasions. *J Periodontol* 70:384–387
- Annalisa P, Furio P, Ilaria Z, Anna A, Luca S, Marcella M, Marzia A, Elena M, Carinci F (2008) Anorganic bovine bone and a silicate-based synthetic bone activate different microRNAs. *J Oral Sci* 50:301–307
- Anson D (1996) Calcium sulfate: a 4-year observation of its use as a resorbable barrier in guided tissue regeneration of periodontal defects. *Compend Contin Educ Dent* 17:895–899
- Anson D (1998) Saving periodontally “hopeless teeth” using calcium sulfate and demineralized freeze-dried bone allograft. *Compend Contin Educ Dent* 19:284, 286, 288 passim
- Aral A, Yalçın S, Karabuda ZC, Anil A, Jansen JA, Mutlu Z (2008) Injectable calcium phosphate cement as a graft material for maxillary sinus augmentation: an experimental pilot study. *Clin Oral Implants Res* 19:612–617
- Arcuri C, Cecchetti F, Germano F, Motta A, Santacroce C (2005) Clinical and histological study of a xenogenic bone substitute used as a filler in postextractive alveolus. *Minerva Stomatol* 54:351–362
- Artzi Z, Nemcovsky C (1998) The application of deproteinized bovine bone mineral for ridge preservation prior to implantation. Clinical and histological observations in a case report. *J Periodontol* 69:1062–1067
- Artzi Z, Weinreb M, Givol N, Rohrer MD, Nemcovsky CE, Prasad HS, Tal H (2004) Biomaterial resorption rate and healing site morphology of inorganic bovine bone and beta-tricalcium phosphate in the canine: a 24-month longitudinal histologic study and morphometric analysis. *Int J Oral Maxillofac Implants* 19:357–368

- Ashman A (1988) Applications of HTR polymer in dentistry. *Compend Suppl* 10):S330–S336
- Ashman A (1992) The use of synthetic bone materials in dentistry. *Compendium* 13(11):1020; 1022, 1024–1026
- Ashman A, Moss LM (1977) Implantation of porous polymethylmethacrylate resin for tooth and bone replacement. *J Prosthet Dent* 37:657–665
- Aspriello SD, Ferrante L, Rubini C, Piemontese M (2011) Comparative study of DFDBA in combination with enamel matrix derivative versus DFDBA alone for treatment of periodontal intrabony defects at 12 months post-surgery. *Clin Oral Investig* 15(2):225–232
- Aybar B, Bilir A, Akçakaya H, Ceyhan T (2004) Effects of tricalcium phosphate bone graft materials on primary cultures of osteoblast cells in vitro. *Clin Oral Implants Res* 15:119–125
- Baldock WT, Hutchens LH Jr, McFall WT Jr, Simpson DM (1985) An evaluation of tricalcium phosphate implants in human periodontal osseous defects of two patients. *J Periodontol* 56:1–7
- Bannister SR, Powell CA (2008) Foreign body reaction to anorganic bovine bone and autogenous bone with platelet-rich plasma in guided bone regeneration. *J Periodontol* 79:1116–1120
- Barnett JD, Mellonig JT, Gray JL, Towle HJ (1989) Comparison of freeze-dried bone allograft and porous hydroxylapatite in human periodontal defects. *J Periodontol* 60:231–237
- Barney VC, Levin MP, Adams DF (1986) Bioceramic implants in surgical periodontal defects. A comparison study. *J Periodontol* 57:764–770
- Barone A, Ricci M, Covani U, Nannmark U, Azarmehr I, Calvo-Guirado JL (2010) Maxillary sinus augmentation using prehydrated corticocancellous porcine bone: histomorphometric evaluation after 6 months. *Clin Implant Dent Relat Res* [Epub ahead of print]
- Beckham CH, Greenlee J, Crebo AR (1971) Bone formation at a ceramic implant surface. *Calcif Tissue Res* 8:165–171
- Beertsen W, van den Bos T, Niehof J (1993) Mineralization of dentinal collagen sheets complexed with alkaline phosphatase and integration with newly formed bone following subperiosteal implantation over osseous defects in rat calvaria. *Bone Miner* 20:41–55
- Bell WH (1964) Resorption rates of bone and bone substitutes. *Oral Surg* 17:650–657
- Beloti MM, Martins W Jr, Xavier SP, Rosa AL (2008) In vitro osteogenesis induced by cells derived from sites submitted to sinus grafting with anorganic bovine bone. *Clin Oral Implants Res* 19:48–54
- Bender SA, Rogalski JB, Mills MP, Arnold RM, Cochran DL, Mellonig JT (2005) Evaluation of demineralized bone matrix paste and putty in periodontal intraosseous defects. *J Periodontol* 76:768–777
- Benke D, Olah A, Möhler H (2001) Protein-chemical analysis of Bio-Oss bone substitute and evidence on its carbonate content. *Biomaterials* 22:1005–1012
- Benqué EP, Gineste M, Heughebaert M (1985) Histological study of the biocompatibility of hydroxyapatite crystals in periodontal surgery. *J Biol Buccale* 13:271–282
- Berglundh T, Lindhe J (1997) Healing around implants placed in bone defects treated with Bio-Oss. An experimental study in the dog. *Clin Oral Implants Res* 8:117–124
- Bergmann F (2010) Ein neues Konzept bei Periimplantitis. Vorgehen mittels aPDT und knochenregenerativ augmentativen Maßnahmen [A new concept within peri-implantitis. Approach by means of aPDT and bone regenerative augmentation]. *Implantologie Journal* 14:36–39
- Blay A, Tunchel S, Sendyk WR (2003) Viability of autogenous bone grafts obtained by using bone collectors: histological and microbiological study. *Pesqui Odontol Bras* 17:234–240
- Blokhuis TJ, Lindner T (2008) Allograft and bone morphogenetic proteins: an overview. *Injury* 39(Suppl 2):S33–S36
- Blom EJ, Klein-Nulend J, Yin L, van Waas MA, Burger EH (2001) Transforming growth factor-beta1 incorporated in calcium phosphate cement stimulates osteoconductivity in rat calvarial bone defects. *Clin Oral Implants Res* 12(6):609–616
- Blumenthal N, Steinberg J (1990) The use of collagen membrane barriers in conjunction with combined demineralized bone-collagen gel implants in human infrabony defects. *J Periodontol* 61:319–327
- Bohner M, Lemaitre J, Van Landuyt P, Zambelli PY, Merkle HP, Gander B (1997) Gentamicin-loaded hydraulic calcium phosphate bone cement as antibiotic delivery system. *J Pharm Sci* 86:565–572
- Bohner M, Gbureck U, Barralet JE (2005) Technological issues for the development of more efficient calcium phosphate bone cements: a critical assessment. *Biomaterials* 26(33):6423–6429
- Bokan I, Bill JS, Schlagenhauf U (2006) Primary flap closure combined with Emdogain® alone or Emdogain® and Cerasorb® in the treatment of intra-bony defects. *J Clin Periodontol* 33:885–893
- Borghetti A, Novakovitch G, Louise F, Simeone D, Fourel J (1993) Cryopreserved cancellous bone allograft in periodontal intraosseous defects. *J Periodontol* 64(2):128–132
- Bornstein MM, Chappuis V, von Arx T, Buser D (2008) Performance of dental implants after staged sinus floor elevation procedures: 5-year results of a prospective study in partially edentulous patients. *Clin Oral Implants Res* 19:1034–1043
- Bosshardt DD, Sculean A (2009) Does periodontal tissue regeneration really work? *Periodontol* 2000 51:208–219
- Bowen JA, Mellonig JT, Gray JL, Towle HT (1989) Comparison of decalcified freeze-dried bone allograft and porous particulate hydroxyapatite in human periodontal osseous defects. *J Periodontol* 60:647–654
- Bowers GM, Chadroff B, Carnevale R et al (1989a) Histologic evaluation of new attachment apparatus formation in humans. Part III. *J Periodontol* 60:683
- Bowers GM, Chadroff B, Carnevale R, Mellonig J, Corio R, Emerson J, Stevens M, Romberg E (1989b) Histologic evaluation of new attachment apparatus formation in humans. Part II. *J Periodontol* 60:675–682
- Bowers GM, Chadroff B, Carnevale R, Mellonig J, Corio R, Emerson J, Stevens M, Romberg E (1989c) Histologic evaluation of new attachment apparatus formation in humans. Part III. *J Periodontol* 60:683–693
- Bowers G, Felton F, Middleton C et al (1991) Histologic comparison of regeneration in human intrabony defects when osteogenin is combined with demineralized freeze-dried bone allograft and with purified bovine collagen. *J Periodontol* 62:690

- Bowers GM, Schallhorn RG, McClain PK, Morrison GM, Morgan R, Reynolds MA (2003) Factors influencing the outcome of regenerative therapy in mandibular Class II furcations: Part I. *J Periodontol* 74:1255–1268
- Boyan BD, Weesner TC, Lohmann CH, Andreacchio D, Carnes DL, Dean DD, Cochran DL, Schwartz Z (2000) Porcine fetal enamel matrix derivative enhances bone formation induced by demineralized freeze dried bone allograft in vivo. *J Periodontol* 71:1278–1286
- Boyan BD, Ranly DM, Schwartz Z (2006) Use of growth factors to modify osteoinductivity of demineralized bone allografts: lessons for tissue engineering of bone. *Dent Clin North Am* 50:217–228
- Browaeys H, Bouvry P, De Bruyn H (2007) A literature review on biomaterials in sinusmentation procedures. *Clin Implant Dent Relat Res* 9:166–177
- Brown GD, Mealey BL, Nummikoski PV, Bifano SL, Waldrop TC (1998) Hydroxyapatite cement implant for regeneration of periodontal osseous defects in humans. *J Periodontol* 69:146–157
- Burguera EF, Xu HH, Sun L (2008) Injectable calcium phosphate cement: effects of powder-to-liquid ratio and needle size. *J Biomed Mater Res B Appl Biomater* 84:493–502
- Bystedt H (2007) Natix used as osteoconductive material for sinus floor augmentation. Three years follow-up. Case report. Presented at the 44th Annual Congress of the Swedish Dental Society, November 8–10, 2007, Göteborg, Sweden. *Swed Dent J* 31:193
- Bystedt H, Rasmusson L (2009) Porous titanium granules used as osteoconductive material for sinus floor augmentation: a clinical pilot study. *Clin Implant Dent Relat Res* 11:101–105
- Callan DP, Rohrer MD (1993) Use of bovine-derived hydroxyapatite in the treatment of edentulous ridge defects: a human clinical and histologic case report. *J Periodontol* 64(6):575–582
- Calongne KB, Aichelmann-Reidy ME, Yukna RA, Mayer ET (2001) Clinical comparison of microporous biocompatible composite of PMMA, PHEMA and calcium hydroxide grafts and expanded polytetrafluoroethylene barrier membranes in human mandibular molar Class II furcations. A case series. *J Periodontol* 72(10):1451–1459
- Calvo Guirado JL, Ramírez Fernández MP, Negri B, Delgado Ruiz RA, Maté Sánchez de-Val JE, Gómez-Moreno G (2011) Experimental model of bone response to collagenized xenografts of porcine origin (OsteoBiol® mp3): a radiological and histomorphometric study. *Clin Implant Dent Relat Res*. doi:doi: 10.1111/j.1708-8208.2011.00337.x; (Epub ahead of print)
- Camargo PM, Lekovic V, Weinlaender M, Nedic M, Vasilic N, Wolinsky LE, Kenney EB (2000) A controlled re-entry study on the effectiveness of bovine porous bone mineral used in combination with a collagen membrane of porcine origin in the treatment of intrabony defects in humans. *J Clin Periodontol* 27:889–896
- Camelo M, Nevins M, Schenk R, Simion M, Rasperini G, Lynch S, Nevins M (1998) Clinical, radiographic, and histologic evaluation of human periodontal defects treated with Biooss and Bio-Gide. *Int J Periodontics Restorative Dent* 18:321–331
- Camelo M, Nevins ML, Lynch SE, Schenk RK, Simion M, Nevins M (2001) Periodontal regeneration with an autogenous bone-Bio-Oss composite graft and a Bio-Gide membrane. *Int J Periodontics Restorative Dent* 21:109–119
- Camelo M, Nevins ML, Schenk RK, Lynch SE, Nevins M (2003) Periodontal regeneration in human Class II furcations using purified recombinant human platelet-derived growth factor-BB (rhPDGF-BB) with bone allograft. *Int J Periodontics Restorative Dent* 23:213–225
- Cardaropoli G, Araújo M, Hayacibara R, Sukekava F, Lindhe J (2005) Healing of extraction sockets and surgically produced – augmented and non-augmented – defects in the alveolar ridge. An experimental study in the dog. *J Clin Periodontol* 32:435–440
- Carinci F, Palmieri A, Martinelli M, Perrotti V, Piattelli A, Brunelli G, Arlotti M, Pezzetti F (2007) Genetic portrait of osteoblast-like cells cultured on PerioGlas. *J Oral Implantol* 33(6):327–333
- Carranza FA Jr, Kenney EB, Lekovic V, Talamante E, Valencia J, Dimitrijevic B (1987) Histologic study of healing of human periodontal defects after placement of porous hydroxylapatite implants. *J Periodontol* 58:682–688
- Carvalho VA, Tosello Dde O, Salgado MA, Gomes MF (2004) Histomorphometric analysis of homogenous demineralized dentin matrix as osteopromotive material in rabbit mandibles. *Int J Oral Maxillofac Implants* 19(5):679–686
- Centers for Disease Control and Prevention (2010) Bone allografts. What is the risk of disease transmission with bone allografts? In: Department of Health and Human Services. Available at: <http://www.cd.gov/OralHealth/Infectioncontrol/faq/allografts.htm>. Accessed 19 Oct 2010
- Chen CC, Wang HL, Smith F, Glickman GN, Shyr Y, O'Neal RB (1995) Evaluation of a collagen membrane with and without bone grafts in treating periodontal intrabony defects. *J Periodontol* 66(10):838–847
- Chen FM, Zhang J, Zhang M, An Y, Chen F, Wu ZF (2010) A review on endogenous regenerative technology in periodontal regenerative medicine. *Biomaterials* 31(31):7892–7927
- Chiang YC, Chen HJ, Liu HC, Kang SH, Lee BS, Lin FH, Lin HP, Lin CP (2010) A novel mesoporous biomaterial for treating dentin hypersensitivity. *J Dent Res* 89:236–240
- Chiriac G, Herten M, Schwarz F, Rothamel D, Becker J (2005) Autogenous bone chips: influence of a new piezoelectric device (Piezosurgery) on chip morphology, cell viability and differentiation. *J Clin Periodontol* 32:994–999
- Choi JY, Jung UW, Lee IS, Kim CS, Lee YK, Choi SH (2011) Resolution of surgically created three-wall intrabony defects in implants using three different biomaterials: an in vivo study. *Clin Oral Implants Res* 22(3):343–348.
- Chris Arts JJ, Verdonshot N, Schreurs BW, Buma P (2006) The use of a bioresorbable nano-crystalline hydroxyapatite paste in acetabular bone impaction grafting. *Biomaterials* 27:1110–1118
- Christgau M, Moder D, Hiller K-A, Dada A, Schmitz G, Schmalz G (2006) Growth factors and cytokines in autologous platelet concentrate and their correlation to periodontal regeneration outcomes. *J Clin Periodontol* 33:837–845
- Cochran DL, Jones A, Heijl L, Mellonig JT, Schoolfield J, King GN (2003) Periodontal regeneration with a combination of enamel matrix proteins and autogenous bone grafting. *J Periodontol* 74:1269–1281

- Cohen MS, Whitman K (1997) Calcium phosphate bone cement: The Norian skeletal repair system in orthopedic surgery. *AORN J* 65:958–962
- Cohen RE, Mullarky RH, Noble B, Comeau RL, Neiders ME (1994) Phenotypic characterization of mononuclear cells following anorganic bovine bone implantation in rats. *J Periodontol* 65:1008–1015
- Committee on Research, Science and Therapy of the American Academy of Periodontology (2001) Tissue banking of bone allografts used in periodontal regeneration. *J Periodontol* 72:834–838
- Comuzzi L, Ooms E, Jansen JA (2002) Injectable calcium phosphate cement as a filler for bone defects around oral implants: an experimental study in goats. *Clin Oral Implants Res* 13:304–311
- Constantz BR, Ison IC, Fulmer MT et al (1995) Skeletal repair by in situ formation of the mineral phase of bone. *Science* 267:1796–1799
- Cortellini P, Pini Prato G, Tonetti MS (1994) Periodontal regeneration of human infrabony defects. V. Effect of oral hygiene on long term stability. *J Clin Periodontol* 21:606–610
- Cortellini P, Tonetti MS (2000) Focus on intrabony defects: guided tissue regeneration. *Periodontol* 22:104–132
- Cortellini P, Tonetti M, Lang NP et al (2001) The simplified papilla preservation flap in the regenerative treatment of deep intrabony defects: clinical outcomes and postoperative morbidity. *J Periodontol* 72:1702–1712
- Cortellini P, Nieri M, Prato GP, Tonetti MS (2008) Single minimally invasive surgical technique with an enamel matrix derivative to treat multiple adjacent intra-bony defects: clinical outcomes and patient morbidity. *J Clin Periodontol* 35:605–613
- Couri CJ, Maze GI, Hinkson DW, Collins BH 3rd, Dawson DV (2002) Medical grade calcium sulfate hemihydrate versus expanded polytetrafluoroethylene in the treatment of mandibular class II furcations. *J Periodontol* 73:1352–1359
- Curtis AR, West NX, Su B (2010) Synthesis of nanobioglass and formation of apatite rods to occlude exposed dentine tubules and eliminate hypersensitivity. *Acta Biomater* 6:3740–3746
- Czuryszkiewicz-Cyrana J, Banach J (2006) Autogenous bone and platelet-rich plasma (PRP) in the treatment of intrabony defects. *Adv Med Sci* 51(Suppl 1):26–30
- Damien E, Revell PA (2004) Coralline hydroxyapatite bone graft substitute: a review of experimental studies and biomedical applications. *J Appl Biomater Biomech* 2:65–73
- Danesh-Meyer MJ, Filstein MR, Shanaman R (2001) Histological evaluation of sinusmentation using platelet rich plasma (PRP): a case series. *J Int Acad Periodontol* 3:48–56
- Jr De Long WG, Einhorn TA, Koval K, McKee M, Smith W, Sanders R, Watson T (2007) Bone grafts and bone graft substitutes in orthopaedic trauma surgery: a critical analysis. *J Bone Joint Surg Am* 89:649–658
- De Putter C, De Groot K, Sillevs-Smith PAE (1983) Transmucosal implants of dense hydroxyapatite. *J Prosthet Dent* 49:87–95
- Demers C, Hamdy CR, Corsi K, Chellat F, Tabrizian M, Yahia L (2002) Natural coral exoskeleton as a bone graft substitute: a review. *Biomed Mater Eng* 12:15–35
- Demir B, Demiralp B, Güncü GN, Uyanik MO, Ca layan F (2007a) Intentional replantation of a hopeless tooth with the combination of platelet rich plasma, bioactive glass graft material and non-resorbable membrane: a case report. *Dent Traumatol* 23:190–194
- Demir B, Sengün D, Berbero lu A (2007b) Clinical evaluation of platelet-rich plasma and bioactive glass in the treatment of intra-bony defects. *J Clin Periodontol* 34:709–715
- Dereka XE, Markopoulou CE, Mamalis A, Pepelassi E, Vrotsos IA (2006) Time- and dose-dependent mitogenic effect of basic fibroblast growth factor combined with different bone graft materials: an in vitro study. *Clin Oral Implants Res* 17:554–559
- Dereka XE, Markopoulou CE, Mamalis A, Vrotsos IA (2009) Effect of rhBMP-7 combined with two bone grafts on human periodontal ligament cell differentiation. *Growth Factors* 27:274–279
- Detienville R, Mirot F, Triller C (1986) Clinical study of a bioresorbable ceramic (Synthograft) in the treatment of intraosseous lesions. 2. Clinical results after 1 year. *J Parodontol* 5:103–110
- Develioğlu H, Saraydin SU, Bolayir G, Dupoirieux L (2006) Assessment of the effect of a biphasic ceramic on bone response in a rat calvarial defect model. *J Biomed Mater Res A* 77:627–631
- DiBattista P, Bissada NF, Ricchetti PA (1995) Comparative effectiveness of various regenerative modalities for the treatment of localized juvenile periodontitis. *J Periodontol* 66:673–678
- Diem CR, Bowers GM, Moffitt WC (1972) Bone blending: a technique for bone implantation. *J Periodontol* 43:295–297
- Dietrich T, Zunker P, Dietrich D, Bernimoulin JP (2003) Periapical and periodontal healing after osseous grafting and guided tissue regeneration treatment of apicomarginal defects in periradicular surgery: results after 12 months. *Oral Surg Oral Med Oral Pathol Oral Radiol Endod* 95:474–482
- Döri F, Huszár T, Nikolidakis D, Tihanyi D, Horváth A, Arweiler NB, Gera I, Sculean A (2008) Effect of platelet-rich plasma on the healing of intrabony defects treated with Beta tricalcium phosphate and expanded polytetrafluoroethylene membranes. *J Periodontol* 79:660–669
- Dragoo MR, Kaldahl WB (1983) Clinical and histological evaluation of alloplasts and allografts in regenerative periodontal surgery in humans. *Int J Periodontics Restorative Dent* 3:8–29
- Dragoo MR, Sullivan HC (1973a) A clinical and histological evaluation of autogenous iliac bone grafts in humans. I. Wound healing 2 to 8 months. *J Periodontol* 44:599–613
- Dragoo MR, Sullivan HC (1973b) A clinical and histological evaluation of autogenous iliac bone grafts in humans. II. External root resorption. *J Periodontol* 44:614–625
- Drury GI, Yukna RA (1991) Histologic evaluation of combining tetracycline and allogeneic freeze-dried bone on bone regeneration in experimental defects in baboons. *J Periodontol* 62:652–658
- Duval BT, Maynard JG, Gunsolley JC, Waldrop TC (2000) Treatment of human mucogingival defects utilizing a bioabsorbable membrane with and without a demineralized freeze-dried bone allograft. *J Periodontol* 71:1687–1692
- Dybvik T, Leknes KN, Bøe OE, Skavland RJ, Albandar JM (2007) Bioactive ceramic filler in the treatment of severe osseous defects: 12-month results. *J Periodontol* 78:403–410
- Elder S, Frankenburg E, Goulet J, Yetkinler D, Poser R, Goldstein S (2000) Biomechanical evaluation of calcium phosphate

- cement-augmented fixation of unstable intertrochanteric fractures. *J Orthop Trauma* 14:386–393
- Elkins AD, Jones LP (1988) The effects of plaster and autogenous cancellous bone on the healing of cortical defects in the femurs of dogs. *Vet Surg* 17:71–76
- Ellinger RF, Nery EB, Lynch KL (1986) Histological assessment of periodontal osseous defects following implantation of hydroxyapatite and biphasic calcium phosphate ceramics: a case report. *Int J Periodontics Restorative Dent* 6:22–33
- Eppley BL, Pietrzak WS, Blanton MW (2005) Allograft and alloplastic bone substitutes: a review of science and technology for the craniomaxillofacial surgeon. *J Craniofac Surg* 16(6):981–989
- Espanol M, Perez RA, Montufar EB, Marichal C, Sacco A, Ginebra MP (2009) Intrinsic porosity of calcium phosphate cements and its significance for drug delivery and tissue engineering applications. *Acta Biomater* 5:2752–2762
- Esposito M, Coulthard P, Worthington HV (2003) Enamel matrix derivative (Emdogain) for periodontal tissue regeneration in intrabony defects (Cochrane Review). *Cochrane Database Syst Rev* (2):CD003875
- Esposito M, Grusovin MG, Coulthard P, Worthington HV (2006) The efficacy of various bone augmentation procedures for dental implants: a Cochrane systematic review of randomized controlled clinical trials. *Int J Oral Maxillofac Implants* 21:696–710
- Esposito M, Grusovin MG, Coulthard P, Worthington HV (2008) The efficacy of interventions to treat peri-implantitis: a Cochrane systematic review of randomised controlled clinical trials. *Eur J Oral Implantol* 1:111–125
- Evans GH, Yukna RA, Sepe WW, Mabry TW, Mayer ET (1989) Effect of various graft materials with tetracycline in localized juvenile periodontitis. *J Periodontol* 60:491–497
- Ewers R, Goriwoda W, Schopper C, Moser D, Spassova E (2004) Histologic findings at augmented bone areas supplied with two different bone substitute materials combine with sinus floor lifting. Report of one case. *Clin Oral Implants Res* 15:96–100
- Fagan MC, Owens H, Smaha J, Kao RT (2008) Simultaneous hard and soft tissue augmentation for implants in the esthetic zone: report of 37 consecutive cases. *J Periodontol* 79:1782–1788
- FDA (2010a) [http://www.accessdata.fda.gov/cdrh\\_docs/pdf4/k040278.pdf](http://www.accessdata.fda.gov/cdrh_docs/pdf4/k040278.pdf). Accessed 22 Oct 2010
- FDA (2010b) [http://www.accessdata.fda.gov/cdrh\\_docs/pdf3/k031073.pdf](http://www.accessdata.fda.gov/cdrh_docs/pdf3/k031073.pdf). Accessed 22 Oct 2010
- FDA (2010c) [http://www.accessdata.fda.gov/cdrh\\_docs/pdf/k003457.pdf](http://www.accessdata.fda.gov/cdrh_docs/pdf/k003457.pdf). Accessed 22 Oct 2010
- FDA (2010d) [http://www.accessdata.fda.gov/cdrh\\_docs/pdf4/k040980.pdf](http://www.accessdata.fda.gov/cdrh_docs/pdf4/k040980.pdf). Accessed 22 Oct 2010
- FDA (2010e) [http://www.accessdata.fda.gov/cdrh\\_docs/pdf4/K042730.pdf](http://www.accessdata.fda.gov/cdrh_docs/pdf4/K042730.pdf). Accessed 22 Oct 2010
- Feng JQ, Luan X, Wallace J, Jing D, Ohshima T, Kulkarni AB, D'Souza RN, Kozak CA, MacDougall M (1998) Genomic organization, chromosomal mapping, and promoter analysis of the mouse dentin sialophosphoprotein (Dspp) gene, which codes for both dentin sialoprotein and dentin phosphoprotein. *J Biol Chem* 273:9457–9464
- Fernández MR, Guirado JL, Ruiz RA, Sánchez de-Val JE, Ortega VV, Olmos LM (2011) Bone response to hydroxyapatites with open porosity of animal origin (porcine [OsteoBiol(®) mp3] and bovine [Endobon(®) ]): a radiological and histomorphometric study. *Clin Oral Implants Res*. doi:doi: 10.1111/j.1600-0501.2010.02058.x; (Epub ahead of print)
- Figueiredo M, Henriques J, Martins G, Guerra F, Judas F, Figueiredo H (2010) Physicochemical characterization of biomaterials commonly used in dentistry as bone substitutes—comparison with human bone. *J Biomed Mater Res B Appl Biomater* 92(2):409–419
- Flemmig TF, Ehmke B, Bolz K, Kübler NR, Karch H, Reuther J, Klaißer B (1998) Long-term maintenance of alveolar bone gain after implantation of autolyzed, antigen extracted, allogenic bone in periodontal intraosseous defects. *J Periodontol* 69:47–53
- Francis J, Brunsvold M, Prewett A, Mellonig J (1995) Clinical evaluation of an allogeneic bone matrix in the treatment of periodontal osseous defects. *J Periodontol* 66:1074–1079
- Frei B, Steveling H, Mertens C (2010) Porous titanium granules for bone regeneration in peri-implantitis-related defects. Presented at the 19th Annual Scientific Meeting of the European Association for Osseointegration, October 6–9, 2010, Glasgow, United Kingdom. *Clin Oral Implants Res* 21:1146
- Froum SJ (1996) Human histologic evaluation of HTR polymer and freeze-dried bone allograft. A case report. *J Clin Periodontol* 23:615–620
- Froum S, Stahl SS (1987) Human intraosseous healing responses to the placement of tricalcium phosphate ceramic implants. II. 13 to 18 months. *J Periodontol* 58:103–109
- Froum SJ, Thaler R, Scopp IW, Stahl SS (1975a) Osseous autografts. I. Clinical responses to bone blend or hip marrow grafts. *J Periodontol* 46:515–521
- Froum SJ, Thaler R, Scopp IW, Stahl SS (1975b) Osseous autografts. II. Histological responses to osseous coagulum-bone blend grafts. *J Periodontol* 46:656–661
- Froum SJ, Ortiz M, Witkin RT, Thaler R, Scopp IW, Stahl SS (1976) Osseous autografts. III. Comparison of osseous coagulum-bone blend implants with open curettage. *J Periodontol* 47:287–294
- Froum SJ, Kushner L, Scopp IW, Stahl SS (1982) Human clinical and histologic responses to Durapatite implants in intraosseous lesions. Case reports. *J Periodontol* 53:719–725
- Froum SJ, Kushner L, Stahl SS (1983) Healing responses of human intraosseous lesions following the use of debridement, grafting and citric acid root treatment. I. Clinical and histologic observations six months postsurgery. *J Periodontol* 54:67–76
- Froum SJ, Weinberg MA, Tarnow D (1998) Comparison of bioactive glass synthetic bone graft particles and open debridement in the treatment of human periodontal defects. A clinical study. *J Periodontol* 69:698–709
- Fujikawa K, Sugawara A, Murai S, Nishiyama M, Takagi S, Chow LC (1995) Histopathological reaction of calcium phosphate cement in periodontal bone defect. *Dent Mater* 11:45–57
- Furusawa T, Mizunuma K, Yamashita S, Takahashi T (1998) Investigation of early bone formation using resorbable bioactive glass in the rat mandible. *Int J Oral Maxillofac Implants* 13:672–676
- Galgut PN, Waite IM, Bookshaw JD, Kingston CP (1992) A 4-year controlled clinical study into the use of a

- ceramic hydroxylapatite implant material for the treatment of periodontal bone defects. *J Clin Periodontol* 19:570–577
- Gao TJ, Tuominen TK, Lindholm TS, Kommonen B, Lindholm TC (1997) Morphological and biomechanical difference in healing in segmental tibial defects implanted with Biocoral or tricalcium phosphate cylinders. *Biomaterials* 18:219–223
- Gauthier O, Boix D, Grimandi G, Aguado E, Boulter JM, Weiss P, Daculsi G (1999) A new injectable calcium phosphate biomaterial for immediate bone filling of extraction sockets: a preliminary study in dogs. *J Periodontol* 70:375–383
- Giannoudis PV, Dinopoulos H, Tsiroidis E (2005) Bone substitutes: an update. *Injury* 36(Suppl 3):S20–S27
- Ginebra MP, Traykova T, Planell JA (2006a) Calcium phosphate cements as bone drug delivery systems: a review. *J Control Release* 113:102–110
- Ginebra MP, Traykova T, Planell JA (2006b) Calcium phosphate cements: competitive drug carriers for the musculoskeletal system? *Biomaterials* 27:2171–2177
- Gomes MF, dos Anjos MJ, Nogueira TO, Guimarães SA (2001) Histologic evaluation of the osteoinductive property of autogenous demineralized dentin matrix on surgical bone defects in rabbit skulls using human amniotic membrane for guided bone regeneration. *Int J Oral Maxillofac Implants* 16:563–571
- Govindaraj S, Costantino PD, Friedman CD (1999) Current use of bone substitutes in maxillofacial surgery. *Facial Plast Surg* 15:73–81, Review
- Graziani F, Cei S, Ivanovski S, La Ferla F, Gabriele M (2007) A systematic review of the effectiveness of bone collectors. *Int J Oral Maxillofac Implants* 22:729–735
- Gross JS (1997) Bone grafting materials for dental applications: a practical guide. *Compend Contin Educ Dent* 18:1013–1020
- Guida L, Annunziata M, Belardo S, Farina R, Scabbia A, Trombelli L (2007) Effect of autogenous cortical bone particulate in conjunction with enamel matrix derivative in the treatment of periodontal intraosseous defects. *J Periodontol* 78:231–238
- Guillemin G, Meunier A, Dallant P, Christel P, Pouliquen JC, Sedel L (1989) Comparison of coral resorption and bone apposition with two natural corals of different porosities. *J Biomed Mater Res* 23:765–779
- Gupta R, Pandit N, Malik R, Sood S (2007) Clinical and radiological evaluation of an osseous xenograft for the treatment of infrabony defects. *J Can Dent Assoc* 73:513
- Gurinsky BS, Mills MP, Mellonig JT (2004) Clinical evaluation of demineralized freeze-dried bone allograft and enamel matrix derivative versus enamel matrix derivative alone for the treatment of periodontal osseous defects in humans. *J Periodontol* 75:1309–1318
- Haimi S, Suuriniemi N, Haaparanta AM, Ellä V, Lindroos B, Huhtala H, Rätty S, Kuokkanen H, Sándor GK, Kellomäki M, Miettinen S, Suuronen R (2009) Growth and osteogenic differentiation of adipose stem cells on PLA/bioactive glass and PLA/beta-TCP scaffolds. *Tissue Eng A* 15:1473–1480
- Hallman M, Thor A (2008) Bone substitutes and growth factors as an alternative/complement to autogenous bone for grafting in implant dentistry. *Periodontol* 2000 47:172–192
- Hallman M, Lundgren S, Sennerby L (2001) Histologic analysis of clinical biopsies taken 6 months and 3 years after maxillary sinus floor augmentation with 80% bovine hydroxyapatite and 20% autogenous bone mixed with fibrin glue. *Clin Implant Dent Relat Res* 3:87–96
- Hämmerle CH, Chiantella GC, Karring T, Lang NP (1998) The effect of a deproteinized bovine bone mineral on bone regeneration around titanium dental implants. *Clin Oral Implants Res* 9:151–162
- Handschel J, Simonowska M, Naujoks C, Depprich RA, Ommerborn MA, Meyer U, Kübler NR (2009) A histomorphometric meta-analysis of sinus elevation with various grafting materials. *Head Face Med* 5:12
- Hanes PJ (2007) Bone replacement grafts for the treatment of periodontal intrabony defects. *Oral Maxillofac Surg Clin North Am* 19(4):499–512
- Haris AG, Szabo G, Ashman A, Divinyi T, Suba Z, Martonffy K (1998) Five-year 224-patient prospective histological study of clinical applications using a synthetic bone alloplast. *Implant Dent* 7:287–299
- Harris RJ (1998) A clinical evaluation of an allograft combined with a bioabsorbable membrane versus an alloplast/allograft composite graft combined with a bioabsorbable membrane. 100 consecutively treated cases. *J Periodontol* 69:536–546
- Harris RJ (2004) Clinical evaluation of a composite bone graft with a calcium sulfate barrier. *J Periodontol* 75:685–692
- Harris RJ, Harris LE, Harris CR, Harris AJ (2007) Clinical evaluation of a combined regenerative technique with enamel matrix derivative, bone grafts, and guided tissue regeneration. *Int J Periodontics Restorative Dent* 27:171–179
- Hashimoto K (1983) Fundamental studies on plaster implants used for infrabony pockets, with special reference to the application of Plaster of Paris (paste type) in experimental bone defects. *Nippon Shishubyo Gakkai Kaishi* 25:44–65
- Hashimoto-Uoshima M, Ishikawa I, Kinoshita A, Weng HT, Oda S (1995) Clinical and histologic observation of replacement of biphasic calcium phosphate by bone tissue in monkeys. *Int J Periodontics Restorative Dent* 15:205–213
- Hattar S, Asselin A, Greenspan D, Oboeuf M, Berdal A, Sautier JM (2005) Potential of biomimetic surfaces to promote in vitro osteoblast-like cell differentiation. *Biomaterials* 26(8):839–848
- Hayashi C, Kinoshita A, Oda S, Mizutani K, Shirakata Y, Ishikawa I (2006) Injectable calcium phosphate bone cement provides favorable space and a scaffold for periodontal regeneration in dogs. *J Periodontol* 77:940–946
- Heinz B, Kasaj A, Teich M, Jepsen S (2010) Clinical effects of nanocrystalline hydroxyapatite paste in the treatment of intrabony periodontal defects: a randomized controlled clinical study. *Clin Oral Investig* 14(5):525–531
- Hench LL (2006) The story of Bioglass. *J Mater Sci Mater Med* 17:967–978
- Hench LL, Splinter RJ, Allen WC, Greenlee TK (1971) Bonding mechanism at the interface of ceramic prosthetic materials: Part 1. *J Biomed Mater Res Symp* 2:117–141
- Herold RW, Pashley DH, Cuenin MF, Niagro F, Hokett SD, Peacock ME, Mailhot J, Borke J (2002) The effects of varying degrees of allograft decalcification on cultured porcine osteoclast cells. *J Periodontol* 73:213–219
- Hiatt WH, Schallhorn RG (1973) Intraoral transplants of cancellous bone and marrow in periodontal lesions. *J Periodontol* 44:194–208

- Hogset O, Bredberg G (1986) Plaster of Paris: thermal properties and biocompatibility. A study on an alternative implant material for ear surgery. *Acta Otolaryngol (Stockh)* 101: 445–452
- Hoidal MJ, Grimard BA, Mills MP, Schoolfield JD, Mellonig JT, Mealey BL (2008) Clinical evaluation of demineralized freeze-dried bone allograft with and without enamel matrix derivative for the treatment of periodontal osseous defects in humans. *J Periodontol* 79:2273–2280
- Holmberg L, Forsgren L, Kristerson L (2008) Porous titanium granules for implant stability and bone regeneration - a case followed for 12 years. *Ups J Med Sci* 113:217–220
- Holtzclaw D, Toscano N, Eisenlohr L et al (2008) The safety of bone allografts used in dentistry: a review. *J Am Dent Assoc* 139:1192–1199
- Hönig JF, Merten HA, Heinemann DE (1999) Risk of transmission of agents associated with Creutzfeldt-Jakob disease and bovine spongiform encephalopathy. *Plast Reconstr Surg* 103:1324–1325
- Horvath A, Stavropoulos A, Sculean A (2009) Clinical and histological evaluation of human intrabony periodontal defects treated with an unsintered nanocrystalline hydroxyapatite paste (Ostim®). *J Clin Periodontol* 36:116
- Hu S, Chang J, Liu M, Ning C (2009) Study on antibacterial effect of 45 S5 Bioglass. *J Mater Sci Mater Med* 20:281–286
- Huber FX, Belyaev O, Hillmeier J, Kock HJ, Huber C, Meeder PJ, Berger I (2006) First histological observations on the incorporation of a novel nanocrystalline hydroxyapatite paste OSTIM in human cancellous bone. *BMC Musculoskelet Disord* 7:50
- Huber FX, Berger I, McArthur N, Huber C, Kock HP, Hillmeier J, Meeder PJ (2008) Evaluation of a novel nanocrystalline hydroxyapatite paste and a solid hydroxyapatite ceramic for the treatment of critical size bone defects (CSD) in rabbits. *J Mater Sci Mater Med* 19(1):33–38
- Hürzeler MB, Quiñones CR, Kirsch A, Gloker C, Schüpbach P, Strub JR, Caffesse RG (1997) Maxillary sinus augmentation using different grafting materials and dental implants in monkeys. Part I. Evaluation of anorganic bovine-derived bone matrix. *Clin Oral Implants Res* 8(6):476–486
- Hutchens LH Jr (1999) The use of a bovine bone mineral in periodontal osseous defects: case reports. *Compend Contin Educ Dent* 20:365–368
- Ignatius AA, Schmidt C, Kaspar D, Claes LE (2001) In vitro biocompatibility of resorbable experimental glass ceramics for bone substitutes. *J Biomed Mater Res* 55:285–294
- Ihoki M (1991) Experimental studies on induction of cartilage and bone by human dentin matrix. *Nihon Koukuugeka Gakkai* 12:1–14
- Inoue T, Deporter DA, Melcher AH (1986a) Induction of cartilage and bone by dentin demineralized in citric acid. *J Periodontol Res* 21(3):243–255
- Inoue T, Deporter DA, Melcher AH (1986b) Induction of chondrogenesis in muscle, skin, bone marrow, and periodontal ligament by demineralized dentin and bone matrix in vivo and in vitro. *J Dent Res* 65:12–22
- Ito T, Shibukawa Y, Amano H, Kawai H, Yamada S (2002) Effect of calcium hydroxide paste on bone formation. *J Dent Res* 81:A–128, Abstract 0857
- Jacobs JE, Rosenberg ES (1984) Management of an intrabony defect using osseous coagulum from a lingual torus. *Compend Contin Educ Dent* 5:57–63
- Jang BJ, Byeon YE, Lim JH, Ryu HH, Kim WH, Koyama Y, Kikuchi M, Kang KS, Kweon OK (2008) Implantation of canine umbilical cord blood-derived mesenchymal stem cells mixed with beta-tricalcium phosphate enhances osteogenesis in bone defect model dogs. *J Vet Sci* 9:387–393
- Jarcho M (1981) Calcium phosphate ceramics as hard tissue prosthetics. *Clin Orthop* 157:259–278
- Jarcho M, Kay JF, Gumaer KI, Doremus RH, Drobeck HP (1977) Tissue cellular and subcellular events at a bone-ceramics interface. *J Bioeng* 1:79–92
- Jensen SS, Aaboe M, Pinholt EM, Hjørtting-Hansen E, Melsen F, Ruyter IE (1996) Tissue reaction and material characteristics of four bone substitutes. *Int J Oral Maxillofac Implants* 11:55–66
- Jensen SS, Yeo A, Dard M, Hunziker E, Schenk R, Buser D (2007) Evaluation of ael biphasic calcium phosphate in standardized bone defects: a histologic and histomorphometric study in the mandibles of minipigs. *Clin Oral Implants Res* 18:752–760
- Jónsson B, Mjöberg B (2009) Surgical treatment of depression fractures of the lateral tibial plateau using porous titanium granules. *Ups J Med Sci* 114:52–54
- Juodzbals G, Wang H-L (2007) Soft and hard tissue assessment of immediate implant placement: a case series. *Clin Oral Implants Res* 18:237–243
- Kamitakahara M, Ohtsuki C, Miyazaki T (2008) Review paper: behavior of ceramic biomaterials derived from tricalcium phosphate in physiological condition. *J Biomater Appl* 23: 197–212
- Karatzas S, Zavras A, Greenspan D, Amar S (1999) Histologic observations of periodontal wound healing after treatment with PerioGlas in nonhuman primates. *Int J Periodontics Restorative Dent* 19:489–499
- Kasaj A, Willershausen B, Berakdar M, Tekyatan H, Sculean A (2006) Effect of an oily calcium hydroxide suspension on early wound healing after nonsurgical periodontal therapy. *Clin Oral Investig* 10:72–76
- Kasaj A, Willershausen B, Jewszyk N, Schmidt M (2007) Effect of an oily calcium hydroxide suspension (Osteoinductal) on human periodontal fibroblasts. An in vitro study. *Eur J Med Res* 12:268–272
- Kasaj A, Röhrig B, Zafropoulos GG, Willershausen B (2008a) Clinical evaluation of nanocrystalline hydroxyapatite paste in the treatment of human periodontal bony defects—a randomized controlled clinical trial: 6-month results. *J Periodontol* 79:394–400
- Kasaj A, Willershausen B, Reichert C, Röhrig B, Smeets R, Schmidt M (2008b) Ability of nanocrystalline hydroxyapatite paste to promote human periodontal ligament cell proliferation. *J Oral Sci* 50:279–285
- Kasperk C, Ewers R, Simons B, Kasperk R (1988) Algae-derived (phycogene) hydroxyapatite. *Int J Oral Maxillofac Surg* 17:319–324
- Kassolis JD, Rosen PS, Reynolds MA (2000) Alveolar ridge and sinus augmentation utilizing platelet-rich plasma in combination with freeze-dried bone allograft: case series. *J Periodontol* 71:1654–1661
- Kawai T, Urist MR (1989) A bovine tooth derived bone morphogenetic protein. *J Dent Res* 68:1069–1074
- Keles GC, Cetinkaya BO, Albayrak D, Koprulu H, Acikgoz G (2006) Comparison of platelet pellet and bioactive glass in periodontal regenerative therapy. *Acta Odontol Scand* 64:327–333

- Kenney EB, Lekovic V, Han T, Carranza FA Jr, Dimitrijevic B (1985) The use of porous hydroxylapatite (HA) implant in periodontal defects. I. Clinical results after six months. *J Periodontol* 56:82–88
- Kenney EB, Lekovic V, Sa Ferreira JC, Han T, Dimitrijevic B, Carranza FA Jr (1986) Bone formation within porous hydroxylapatite implants in human periodontal defects. *J Periodontol* 57:76–83
- Kim C-K, Choi E-J, Cho K-S, Chai JK, Wikesjö UME (1996) Periodontal repair in intrabony defects treated with a calcium carbonate implant and guided tissue regeneration. *J Periodontol* 67:1301–1306
- Kim CK, Chai JK, Cho KS, Moon IS, Choi SH, Sottosanti JS, Wikesjö UM (1998) Periodontal repair in intrabony defects treated with a calcium sulfate implant and calcium sulfate barrier. *J Periodontol* 69:1317–1324
- Kim CS, Choi SH, Cho KS, Chai JK, Wikesjö UM, Kim CK (2005) Periodontal healing in one-wall intra-bony defects in dogs following implantation of autogenous bone or a coral-derived biomaterial. *J Clin Periodontol* 32:583–589
- Kimble KM, Eber RM, Soehren S, Shyr Y, Wang HL (2004) Treatment of gingival recession using a collagen membrane with or without the use of demineralized freeze-dried bone allograft for space maintenance. *J Periodontol* 75:210–220
- Kirsh ER, Garg AK (1994) Postextraction ridge maintenance using the endosseous ridge maintenance implant (ERMI). *Compendium* 15:234, 236, 238 passim; quiz 244
- Klongnoi B, Rupprecht S, Kessler P, Zimmermann R, Thorwarth M, Pongsiri S, Neukam FW, Wiltfang J, Schlegel KA (2006) Lack of beneficial effects of platelet-rich plasma on sinus-mentation using a fluorohydroxyapatite or autogenous bone: an explorative study. *J Clin Periodontol* 33:500–509
- Knabe C, Driessens FC, Planell JA, Gildenhaar R, Berger G, Reif D, Fitzner R, Radlanski RJ, Gross U (2000) Evaluation of calcium phosphates and experimental calcium phosphate bone cements using osteogenic cultures. *J Biomed Mater Res* 52:498–508
- Kohal RJ, Hürzeler MB, Schneider SR, Riede UN, Caffesse RG (1997) The effect of a calcium hydroxide paste on wound healing and osseointegration of dental implants. A pilot study in beagle dogs. *Clin Oral Implants Res* 8:375–385
- Kolerman R, Tal H, Moses O (2008) Histomorphometric analysis of newly formed bone after maxillary sinus floor augmentation using ground cortical bone allograft and internal collagen membrane. *J Periodontol* 79:2104–2111
- Kontonasaki E, Sivropoulou A, Papadopoulou L, Garefis P, Paraskevopoulos K, Koidis P (2007) Attachment and proliferation of human periodontal ligament fibroblasts on bioactive glass modified ceramics. *J Oral Rehabil* 34:57–67
- Koo KT, Polimeni G, Qahash M, Kim CK, Wikesjö UM (2005) Periodontal repair in dogs: guided tissue regeneration enhances bone formation in sites implanted with a coral-derived calcium carbonate biomaterial. *J Clin Periodontol* 32:104–110
- Kothiwale SV, Anuroopa P, Gajiwala AL (2009) A clinical and radiological evaluation of DFDBA with amniotic membrane versus bovine derived xenograft with amniotic membrane in human periodontal grade II furcation defects. *Cell Tissue Bank* 10:317–326
- Kotschy P, Laky M (2006) Reconstruction of supracrestal alveolar bone lost as a result of severe chronic periodontitis. Five-year outcome: case report. *Int J Periodontics Restorative Dent* 26:425–431
- Kuo TC, Lee BS, Kang SH, Lin FH, Lin CP (2007) Cytotoxicity of DP-bioglass paste used for treatment of dentin hypersensitivity. *J Endod* 33:451–454
- Kuru B, Yilmaz S, Argin K, Noyan U (2006) Enamel matrix derivative alone or in combination with a bioactive glass in wide intrabony defects. *Clin Oral Investig* 10:227–234
- Kwon HR, Wikesjö UM, Park JC, Kim YT, Bastone P, Pippig SD, Kim CK (2010) Growth/differentiation factor-5 significantly enhances periodontal wound healing/regeneration compared with platelet-derived growth factor-BB in dogs. *J Clin Periodontol* 37:739–746
- Lamb JW 3rd, Greenwell H, Drisko C, Henderson RD, Scheetz JP, Rebitski G (2001) A comparison of porous and non-porous teflon membranes plus demineralized freeze-dried bone allograft in the treatment of class II buccal/lingual furcation defects: a clinical reentry study. *J Periodontol* 72:1580–1587
- Lang NP, Tonetti MS, Suvan JE, Bernard JP, Botticelli D, Fourmousis I, Hallund M, Jung R, Laurell L, Salvi GE, Shafer D, Weber H-P (2007) Immediate implant placement with transmucosal healing in areas of aesthetic priority: a multicentre randomized-controlled clinical trial I. Surgical outcomes. *Clin Oral Implants Res* 18:188–196
- Larsson S (2010) Calcium phosphates: what is the evidence? *J Orthop Trauma* 24(Suppl 1):S41–S45
- Laschke MW, Witt K, Pohlemann T, Menger MD (2007) Injectable nanocrystalline hydroxyapatite paste for bone substitution: In vivo analysis of biocompatibility and vascularization. *J Biomed Mater Res B Appl Biomater* 82:494–505
- Laurell L, Gottlow J, Zyburtz M, Persson R (1998) Treatment of intrabony defects by different surgical procedures. A literature review. *J Periodontol* 69:303–313
- Lee BS, Tsai HY, Tsai YL, Lan WH, Lin CP (2005) In vitro study of DP-bioglass paste for treatment of dentin hypersensitivity. *Dent Mater J* 24:562–569
- Lee BS, Kang SH, Wang YL, Lin FH, Lin CP (2007) In vitro study of dentinal tubule occlusion with sol-gel DP-bioglass for treatment of dentin hypersensitivity. *Dent Mater J* 26:52–61
- Lee CY, Rohrer MD, Prasad HS, Stover JD, Suzuki JB (2009) Sinus grafting with a natural fluorohydroxyapatite for immediate load: a study with histologic analysis and histomorphometry. *J Oral Implantol* 35:164–175
- Lee SB, Jung UW, Choi Y, Jamiyandorj O, Kim CS, Lee YK, Chai JK, Choi SH (2010) Investigation of bone formation using calcium phosphate glass cement in beagle dogs. *J Periodontal Implant Sci* 40:125–131
- Leknes KN, Andersen KM, Bøe OE, Skavland RJ, Albandar JM (2009) Enamel matrix derivative versus bioactive ceramic filler in the treatment of intrabony defects: 12-month results. *J Periodontol* 80:219–227
- Lekovic V, Camargo PM, Weinlaender M, Nedic M, Aleksic Z, Kenney EB (2000) A comparison between enamel matrix proteins used alone or in combination with bovine porous bone mineral in the treatment of intrabony periodontal defects in humans. *J Periodontol* 71:1110–1116
- Lekovic V, Camargo PM, Weinlaender M, Vasilic N, Djordjevic M, Kenney EB (2001) The use of bovine porous bone

- mineral in combination with enamel matrix proteins or with an autologous fibrinogen/fibronectin system in the treatment of intrabony periodontal defects in humans. *J Periodontol* 72:1157–1163
- Leung G, Jin L (2003) A combined approach of enamel matrix derivative gel and autogenous bone grafts in treatment of intrabony periodontal defects. A case report. *Prim Dent Care* 10(2):41–43
- Levin MP, Getter L, Adrian J, Cutright DE (1974) Healing of periodontal defects with ceramic implants. *J Clin Periodontol* 1:197–205
- Li H, Pujic Z, Xiao Y, Bartold PM (2000) Identification of bone morphogenetic proteins 2 and 4 in commercial demineralized freeze-dried bone allograft preparations: pilot study. *Clin Implant Dent Relat Res* 2:110–117
- Lim HC, Sohn JY, Park JC, Um YJ, Jung UW, Kim CS, Lee YK, Choi SH (2010) Osteoconductive effects of calcium phosphate glass cement grafts in rabbit calvarial defects. *J Biomed Mater Res B Appl Biomater* 95:47–52
- Lin KY, Bartlett SP, Yaremchuk MJ, Fallon M, Grossman RF, Whitaker LA (1990) The effect of rigid fixation on the survival of onlay bone grafts: an experimental study. *Plast Reconstr Surg* 86:449–456
- Liñares A, Cortellini P, Lang NP, Suvan J, Tonetti MS, European Research Group on Periodontology (ErgoPerio) (2006) Guided tissue regeneration/deproteinized bovine bone mineral or papilla preservation flaps alone for treatment of intrabony defects. II: radiographic predictors and outcomes. *J Clin Periodontol* 33:351–358
- Lindfors LT, Tervonen EA, Sándor GK, Ylikontiola LP (2010) Guided bone regeneration using a titanium-reinforced ePTFE membrane and particulate autogenous bone: the effect of smoking and membrane exposure. *Oral Surg Oral Med Oral Pathol Oral Radiol Endod* 109:825–830
- Lohmann CH, Andreacchio D, Köster G, Carnes DL Jr, Cochran DL, Dean DD, Boyan BD, Schwartz Z (2001) Tissue response and osteoinduction of human bone grafts in vivo. *Arch Orthop Trauma Surg* 121:583–590
- Louise F, Fourel J, Roig R (1985) Bioceramics in periodontal bone surgery. Clinical trial of Synthograft. *J Parodontol* 4:277–285
- Lovelace TB, Mellonig JT, Meffert RM, Jones AA, Nummikoski PV, Cochran DL (1998) Clinical evaluation of bioactive glass in the treatment of periodontal osseous defects in humans. *J Periodontol* 69:1027–1035
- Low SB, King CJ, Krieger J (1997) An evaluation of bioactive ceramic in the treatment of periodontal osseous defects. *Int J Periodontics Restorative Dent* 17:358–367
- Lu Z, Zreiqat H (2010a) Beta-tricalcium phosphate exerts osteoconductivity through  $\alpha 2\beta 1$  integrin and down-stream MAPK/ERK signaling pathway. *Biochem Biophys Res Commun* 394:323–329
- Lu Z, Zreiqat H (2010b) The osteoconductivity of biomaterials is regulated by bone morphogenetic protein 2 autocrine loop involving  $\alpha 2\beta 1$  integrin and mitogen-activated protein kinase/extracellular related kinase signaling pathways. *Tissue Eng A* 16:3075–3084
- Lu JX, Gallur A, Flaute B, Anselme K, Descamps M, Thierry B et al (1998) Comparative study of tissue reactions to calcium phosphate ceramics among cancellous, cortical, and medullar bone sites in rabbits. *J Biomed Mater Res* 42:357–367
- Mabry TW, Yukna RA, Sepe WW (1985) Freeze-dried bone allografts combined with tetracycline in the treatment of juvenile periodontitis. *J Periodontol* 56:74–81
- Machado ME, Souza AS, Araújo VC (2006) Histological evaluation of the osteoinduction capability of human dentine. *Int Endod J* 39:855–859
- Magistri A, Botticelli L, Romitelli AM, De Luca P, Evangelisti N, Guadagno I (2006) Trattamento delle grandi cavità cistiche con biomateriali [Treatment of large cystic cavities with biomaterial]. *Chir Orale* 2:16–19
- Maragos P, Bissada NF, Wang R, Cole BP (2002) Comparison of three methods using calcium sulfate as a graft/barrier material for the treatment of Class II mandibular molar furcation defects. *Int J Periodontics Restorative Dent* 22:493–501
- Markopoulou CE, Vrotsos IA, Vavouraki HN, Dereka XE, Mantzavinos ZS (2003) Human periodontal ligament cell responses to recombinant human bone morphogenetic protein-2 with and without bone allografts. *J Periodontol* 74:982–989
- Markou N, Pepelassi E, Vavouraki H, Stamatakis HC, Nikolopoulos G, Vrotsos I, Tsiklakis K (2009) Treatment of periodontal endosseous defects with platelet-rich plasma alone or in combination with demineralized freeze-dried bone allograft: a comparative clinical trial. *J Periodontol* 80:1911–1919
- Markou N, Pepelassi E, Kotsovilis S, Vrotsos I, Vavouraki H, Stamatakis HC (2010) The use of platelet-rich plasma combined with demineralized freeze-dried bone allograft in the treatment of periodontal endosseous defects: a report of two clinical cases. *J Am Dent Assoc* 141:967–978
- Marx RE (1994) Clinical application of bone biology to mandibular and maxillary reconstruction. *Clin Plast Surg* 21:377–392
- Masters L, Mellonig J, Brunsvold M, Numikowski P (1996) A clinical evaluation of demineralized freeze dried bone allograft in combination with tetracycline in the treatment of periodontal osseous defects. *J Periodontol* 67:770–781
- McGuire MK, Kao RT, Nevins M, Lynch SE (2006) rhPDGF-BB promotes healing of periodontal defects: 24-month clinical and radiographic observations. *Int J Periodontics Restorative Dent* 26:223–231
- McGuire MK, Scheyer ET, Schupbach P (2009a) Growth factor-mediated treatment of recession defects: a randomized controlled trial and histologic and microcomputed tomography examination. *J Periodontol* 80:550–564
- McGuire MK, Scheyer T, Nevins M, Schupbach P (2009b) Evaluation of human recession defects treated with coronally advanced flaps and either purified recombinant human platelet-derived growth factor-BB with beta tricalcium phosphate or connective tissue: a histologic and microcomputed tomographic examination. *Int J Periodontics Restorative Dent* 29:7–21
- Meadows CL, Gher ME, Quintero G, Lafferty TA (1993) A comparison of polylactic acid granules and decalcified freeze-dried bone allograft in human periodontal osseous defects. *J Periodontol* 64:103–109
- Mellonig JT (1984) Calcified freeze-dried bone allograft as an implant material in human periodontal defects. *Int J Periodontics Restorative Dent* 4:40–55

- Mellonig JT (1992) Autogenous and allogeneic bone grafts in periodontal therapy. *Crit Rev Oral Biol Med* 3:333–352
- Mellonig J (2000) Human histologic evaluation of a bovine-derived xenograft in the treatment of periodontal osseous defects. *Int J Periodontics Restorative Dent* 20:19–29
- Mellonig JT, Prewett AB, Moyer MP (1992) HIV inactivation in a bone allograft. *J Periodontol* 63:979–983
- Mellonig JT, Valderrama Mdel P, Cochran DL (2009) Histological and clinical evaluation of recombinant human platelet-derived growth factor combined with beta tricalcium phosphate for the treatment of human Class III furcation defects. *Int J Periodontics Restorative Dent* 29:169–177
- Mellonig JT, Valderrama P, Cochran DL (2010) Clinical and histologic evaluation of calcium-phosphate bone cement in interproximal osseous defects in humans: a report in four patients. *Int J Periodontics Restorative Dent* 30:121–127
- Mengel R, Soffner M, Flores-de-Jacoby L (2003) Bioabsorbable membrane and bioactive glass in the treatment of intrabony defects in patients with generalized aggressive periodontitis: results of a 12-month clinical and radiological study. *J Periodontol* 74:899–908
- Mengel R, Schreiber D, Flores-de-Jacoby L (2006) Bioabsorbable membrane and bioactive glass in the treatment of intrabony defects in patients with generalized aggressive periodontitis: results of a 5-year clinical and radiological study. *J Periodontol* 77:1781–1787
- Meraw SJ, Reeve CM, Lohse CM, Sioussat TM (2000) Treatment of peri-implant defects with combination growth factor cement. *J Periodontol* 71:8–13
- Merx MAW, Maltha JC, Stoeltinga PJW (2003) Assessment of the value of anorganic bone additives in sinus floormentation: a review of clinical reports. *Int J Oral Maxillofac Surg* 32:1–6
- Metsger DS, Driskell TD, Paulsrud JR (1982) Tricalcium phosphate ceramic—a resorbable bone implant: review and current status. *J Am Dent Assoc* 105:1035–1038
- Misch CE (1999) *Contemporary implant dentistry*, 2nd edn. Mosby, Pittsburgh, pp 452–476
- Misch CE, Dietsch F (1993) Bone-grafting materials in implant dentistry. *Implant Dent* 2:158–167
- Moghadam HG, Sandor GK, Holmes HH, Clokie CM (2004) Histomorphometric evaluation of bone regeneration using allogeneic and alloplastic bone substitutes. *J Oral Maxillofac Surg* 62:202–213
- Mora F, Ouhayoun JP (1995) Clinical evaluation of natural coral and porous hydroxyapatite implants in periodontal bone lesions: results of a 1-year follow-up. *J Clin Periodontol* 22:877–884
- Mott DA, Mailhot J, Cuenin MF, Sharawy M, Borke J (2002) Enhancement of osteoblast proliferation in vitro by selective enrichment of demineralized freeze-dried bone allograft with specific growth factors. *J Oral Implantol* 28:57–66
- Movin S, Borring-Møller G (1982) Regeneration of infrabony periodontal defects in humans after implantation of allogeneic demineralized dentin. *J Clin Periodontol* 9(2):141–147
- Munukka E, Leppäranta O, Korkeamäki M, Vaahtio M, Peltola T, Zhang D, Hupa L, Ylänen H, Salonen JI, Viljanen MK, Eerola E (2008) Bactericidal effects of bioactive glasses on clinically important aerobic bacteria. *J Mater Sci Mater Med* 19:27–32
- Muramatsu T, Hamano H, Fukumashi K, Shiigai T, Fujiseki M, Katayanagi T, Osada K, Inoue T, Shimono M (1993) An experimental study of chondrogenesis and osteogenesis in rat submandibular gland induced by implantation of demineralized dentin. *Bull Tokyo Dent Coll* 34:15–22
- Murphy KG, Gunsolley JC (2003) Guided tissue regeneration for the treatment of periodontal intrabony and furcation defects. A systematic review. *Ann Periodontol* 8(1):266–302
- Nakanishi S, Ota M, Shibukawa Y, Yamada S (2009) C-Graft in regeneration of periodontal tissue in intrabony periodontal defect in dog. *J Biomater Appl* 24:89–104
- Nandi SK, Roy S, Mukherjee P, Kundu B, De DK, Basu D (2010) Orthopaedic applications of bone graft and graft substitutes: a review. *Indian J Med Res* 132:15–30
- Nannmark U, Azarmehr I (2010) Short communication: collagenated cortico-cancellous porcine bone grafts. A study in rabbit maxillary defects. *Clin Implant Dent Relat Res* 12:161–163
- Nannmark U, Sennerby L (2008) The bone tissue responses to prehydrated and collagenated corticocancellous porcine bone grafts: a study in rabbit maxillary defects. *Clin Implant Dent Relat Res* 10:264–270
- Nasr HF, Aichelmann-Reidy ME, Yukna RA (1999) Bone and bone substitutes. *Periodontol* 2000 19:74–86
- Neamat A, Gawish A, Gamal-Eldeen AM (2009) beta-Tricalcium phosphate promotes cell proliferation, osteogenesis and bone regeneration in intrabony defects in dogs. *Arch Oral Biol* 54:1083–1090
- Needleman IG, Giedrys-Leeper E, Tucker RJ, Worthington HV (2001) Guided tissue regeneration for periodontal infra-bony defects. *Cochrane Database Syst Rev* 2:CD001724
- Nery EB, Lynch KL (1978) Preliminary clinical studies of bio-ceramic in periodontal osseous defects. *J Periodontol* 49:523–527
- Nery EB, LeGeros RZ, Lynch KL, Lee K (1992) Tissue response to biphasic calcium phosphate ceramic with different ratios of HA/beta TCP in periodontal osseous defects. *J Periodontol* 63:729–735
- Nevins ML, Camelo M, Nevins M, Nevins M, King CJ, Oringer RJ, Schenk RK, Fiorellini JP (2000) Human histologic evaluation of bioactive ceramic in the treatment of periodontal osseous defects. *Int J Periodontics Restorative Dent* 20:458–467
- Nevins M, Camelo M, Nevins ML, Schenk RK, Lynch SE (2003a) Periodontal regeneration in humans using recombinant human platelet-derived growth factor-BB (rhPDGF-BB) and allogeneic bone. *J Periodontol* 74(9):1282–1292
- Nevins ML, Camelo M, Lynch SE, Schenk RK, Nevins M (2003b) Evaluation of periodontal regeneration following grafting intrabony defects with bio-oss collagen: a human histologic report. *Int J Periodontics Restorative Dent* 23:9–17
- Nevins M, Giannobile WV, McGuire MK, Kao RT, Mellonig JT, Hinrichs JE, McAllister BS, Murphy KS, McClain PK, Nevins ML, Paquette DW, Han TJ, Reddy MS, Lavin PT, Genco RJ, Lynch SE (2005a) Platelet-derived growth factor stimulates bone fill and rate of attachment level gain: results of a large multicenter randomized controlled trial. *J Periodontol* 76:2205–2215
- Nevins ML, Camelo M, Rebaudi A, Lynch SE, Nevins M (2005b) Three-dimensional micro-computed tomographic

- evaluation of periodontal regeneration: a human report of intrabony defects treated with Bio-Oss collagen. *Int J Periodontics Restorative Dent* 25:365–373
- Nevins M, Hanratty J, Lynch SE (2007) Clinical results using recombinant human platelet-derived growth factor and mineralized freeze-dried bone allograft in periodontal defects. *Int J Periodontics Restorative Dent* 27:421–427
- Ning Y, Wei T, Defu C, Yonggang X, Da H, Dafu C, Lei S, Zhizhong G (2009) The research of degradability of ael bio-degradable coralline hydroxyapatite after implanted into rabbit. *J Biomed Mater Res A* 88:741–746
- Noetzel J, Ozer K, Reissbauer BH, Anil A, Rössler R, Neumann K, Kielbassa AM (2006) Tissue responses to an experimental calcium phosphate cement and mineral trioxide aggregate as materials for furcation perforation repair: a histological study in dogs. *Clin Oral Investig* 10:77–83
- Nygaard-Østby P, Bakke V, Nesdal O, Nilssen HK, Susin C, Wikesjö UM (2008) Periodontal healing following reconstructive surgery: effect of guided tissue regeneration using a bioresorbable barrier device when combined with autogenous bone grafting. A randomized controlled clinical trial. *J Clin Periodontol* 35:37–43
- Nygaard-Østby P, Bakke V, Nesdal O, Susin C, Wikesjö UM (2010) Periodontal healing following reconstructive surgery: effect of guided tissue regeneration using a bioresorbable barrier device when combined with autogenous bone grafting. A randomized-controlled trial 10-year follow-up. *J Clin Periodontol* 37:366–373
- Ogawa T, Yamada T, Miura F, Miyazaki S, Machida H, Akimoto Y, Hagiwara K, Kawanishi F, Shirakawa M, Okamoto H (1985) [Clinical evaluation of bone grafts in periodontal surgery. 1. Use of autogenous bone grafts in 2- and 3-walled interproximal bone defects]. *Hiroshima Daigaku Shigaku Zasshi* 17(1): 214–220
- Oguntebi B, Clark A, Wilson J (1993) Pulp capping with Bioglass and autologous demineralized dentin in miniature swine. *J Dent Res* 72:484–489
- Ohgaki M, Kizuki T, Katsura M, Yamashita K (2001) Manipulation of selective cell adhesion and growth by surface charges of electrically polarized hydroxyapatite. *J Biomed Mater Res* 57:366–373
- Okuda K, Tai H, Tanabe K, Suzuki H, Sato T, Kawase T, Saito Y, Wolff LF, Yoshie H (2005) Platelet-rich plasma combined with a porous hydroxyapatite graft for the treatment of intrabony periodontal defects in humans: a comparative controlled clinical study. *J Periodontol* 76:890–898
- Ong MM, Eber RM, Korsnes MI, MacNeil RL, Glickman GN, Shyr Y, Wang HL (1998) Evaluation of a bioactive glass allplast in treating periodontal intrabony defects. *J Periodontol* 69:1346–1354
- Oonishi H, Kushitani S, Yasukawa E, Iwaki H, Hench LL, Wilson J, Tsuji E, Sugihara T (1997) Particulate bioglass compared with hydroxyapatite as a bone graft substitute. *Clin Orthop* 334:316–325
- Oreamuno S, Lekovic V, Kenney EB, Carranza FA Jr, Takei HH, Prokic B (1990) Comparative clinical study of porous hydroxyapatite and decalcified freeze-dried bone in human periodontal defects. *J Periodontol* 61:399–404
- Orsini M, Orsini G, Benlloch D, Aranda JJ, Lazaro P, Sanz M, De Luca M, Piattelli A (2001) Comparison of calcium sulfate and autogenous bone graft to bioabsorbable membranes plus autogenous bone graft in the treatment of intrabony periodontal defects: a split-mouth study. *J Periodontol* 72: 296–302
- Orsini G, Traini T, Scarano A, Degidi M, Perrotti V, Piccirilli M, Piattelli A (2005) Maxillary sinusmentation with Bio-Oss particles: a light, scanning, and transmission electron microscopy study in man. *J Biomed Mater Res B Appl Biomater* 74:448–457
- Orsini M, Orsini G, Benlloch D, Aranda JJ, Sanz M (2008) Long-term clinical results on the use of bone-replacement grafts in the treatment of intrabony periodontal defects. Comparison of the use of autogenous bone graft plus calcium sulfate to autogenous bone graft covered with a bioabsorbable membrane. *J Periodontol* 79:1630–1637
- Otsuka M, Matsuda Y, Suwa Y, Fox JL, Higuchi WI (1994) A novel skeletal drug-delivery system using self-setting calcium phosphate cement. 3. Physicochemical properties and drug-release rate of bovine insulin and bovine albumin. *J Pharm Sci* 83:255–258
- Pagliani L, Andersson P, Lanza M, Nappo A, Verrocchi D, Volpe S, Senneryby L (2010) A collagenated porcine bone substitute for augmentation at Neoss implant sites: a prospective 1-year multicenter case series study with histology. *Clin Implant Dent Relat Res*. doi: 10.1111/j.1708-8208.2010.00314.x [Epub ahead of print]
- Pagliani L, Volpe S. Localized bone regeneration with porcine bone graft: clinical and histological evidences. Retrieved at [http://www.orimeda.lt/out/oxbaseshop/html/0/images/wysiwygpro/OsteoBiol/Abstracts\\_2010.03.24.pdf](http://www.orimeda.lt/out/oxbaseshop/html/0/images/wysiwygpro/OsteoBiol/Abstracts_2010.03.24.pdf)
- Palmieri A, Pezzetti F, Spinelli G, Arlotti M, Avantiaggiato A, Scarano A, Scapoli L, Zollino I, Carinci F (2008) PerioGlas regulates osteoblast RNA interfering. *J Prosthodont* 17(7):522–526
- Palmieri A, Pezzetti F, Brunelli G, Martinelli M, Lo Muzio L, Scarano A, Scapoli L, Arlotti M, Guerzoni L, Carinci F (2010) Anorganic bovine bone (Bio-Oss) regulates miRNA of osteoblast-like cells. *Int J Periodontics Restorative Dent* 30:83–87
- Palti A, Hoch T (2002) A concept for the treatment of various dental bone defects. *Implant Dent* 11(1):73–78
- Paolantonio M (2002) Combined periodontal regenerative technique in human intrabony defects by collagen membranes and anorganic bovine bone. A controlled clinical study. *J Periodontol* 73:158–166
- Paolantonio M, Scarano A, Di Placido G, Tumini V, D'Archivio D, Piattelli A (2001) Periodontal healing in humans using anorganic bovine bone and bovine peritoneum-derived collagen membrane: a clinical and histologic case report. *Int J Periodontics Restorative Dent* 21:505–515
- Paolantonio M, Perinetti G, Dolci M, Perfetti G, Tetè S, Sammartino G, Femminella B, Graziani F (2008) Surgical treatment of periodontal intrabony defects with calcium sulfate implant and barrier versus collagen barrier or open flap debridement alone: a 12-month randomized controlled clinical trial. *J Periodontol* 79:1886–1893
- Papadopoulos CE, Dereka XE, Vavouraki EN, Vrotsos IA (2003) In vitro evaluation of the mitogenic effect of platelet-derived growth factor-BB on human periodontal ligament cells cultured with various bone allografts. *J Periodontol* 74:451–457
- Park JS, Suh JJ, Choi SH, Moon IS, Cho KS, Kim CK, Chai JK (2001) Effects of pretreatment clinical parameters

- on bioactive glass implantation in intrabony periodontal defects. *J Periodontol* 72:730–740
- Parodi R, Santarelli G, Carusi G (1996) Application of slow-resorbing collagen membrane to periodontal and peri-implant guided tissue regeneration. *Int J Periodontics Restorative Dent* 16:174–185
- Peters CL, Hines JL, Bachus KN, Craig MA, Bloebaum RD (2006) Biological effects of calcium sulfate as a bone graft substitute in ovine metaphyseal defects. *J Biomed Mater Res A* 76(3):456–462
- Piattelli A, Scarano A, Corigliano M, Piattelli M (1996a) Comparison of bone regeneration with the use of mineralized and demineralized freeze-dried bone allografts: a histological and histochemical study in man. *Biomaterials* 17:1127–1131
- Piattelli A, Scarano A, Mangano C (1996b) Clinical and histologic aspects of biphasic calcium phosphate ceramic (BCP) used in connection with implant placement. *Biomaterials* 17:1767–1770
- Piattelli A, Podda G, Scarano A (1997) Clinical and histological results in alveolar ridge enlargement using coralline calcium carbonate. *Biomaterials* 18:623–627
- Piattelli M, Favero GA, Scarano A, Orsini G, Piattelli A (1999) Bone reactions to anorganic bovine bone (Bio-Oss) used in sinusmentation procedures: a histologic long-term report of 20 cases in humans. *Int J Oral Maxillofac Implants* 14:835–840
- Piemontese M, Aspriello SD, Rubini C, Ferrante L, Procaccini M (2008) Treatment of periodontal intrabony defects with demineralized freeze-dried bone allograft in combination with platelet-rich plasma: a comparative clinical trial. *J Periodontol* 79:802–810
- Pietruska MD (2001) A comparative study on the use of Bio-Oss® and enamel matrix derivative (Emdogain®) in the treatment of periodontal bone defects. *Eur J Oral Sci* 109:178–181
- Polimeni G, Koo KT, Qahash M, Xiropaidis AV, Albandar JM, Wikesjö UM (2004) Prognostic factors for alveolar regeneration: effect of a space-providing biomaterial on guided tissue regeneration. *J Clin Periodontol* 31:725–729
- Polimeni G, Xiropaidis AV, Wikesjö UM (2006) Biology and principles of periodontal wound healing/regeneration. *Periodontol* 2000 41:30–47
- Pollick S, Shors EC, Holmes RE, Kraut RA (1995) Bone formation and implant degradation of coralline porous ceramics placed in bone and ectopic sites. *J Oral Maxillofac Surg* 53:915–922
- Prakash S, Sunitha J, Abid S (2010) Evaluation of HTR polymer (Bioplant HTR) as a bone graft material in the treatment of interproximal vertical bony defects: a clinical and radiological study. *Indian J Dent Res* 21(2):179–184
- Precheur HV (2007) Bone graft materials. *Dent Clin North Am* 51(3):729–746
- Price N, Bendall SP, Fronzoza C, Jinnah RH, Hungerford DS (1997) Human osteoblast-like cells (MG63) proliferate on bioactive glass surface. *J Biomed Mater Res* 37:394–400
- Pripatnanont P, Nuntanarant T, Vongvacharanon S (2009) Proportion of deproteinized bovine bone and autogenous bone affects bone formation in the treatment of calvarial defects in rabbits. *Int J Oral Maxillofac Surg* 38:356–362
- Quattlebaum JB, Mellonig JT, Hensel NF (1988) Antigenicity of freeze-dried cortical bone allograft in human periodontal osseous defects. *J Periodontol* 59:394–397
- Rafter M, Baker M, Alves M, Daniel J, Remeikis N (2002) Evaluation of healing with use of an internal matrix to repair furcation perforations. *Int Endod J* 35:775–783
- Rajesh JB, Nandakumar K, Varma HK, Komath M (2009) Calcium phosphate cement as a “barrier-graft” for the treatment of human periodontal intraosseous defects. *Indian J Dent Res* 20:471–479
- Reddi AH, Huggins CB (1973) Influence of geometry of transplanted tooth and bone on transformation of fibroblasts. *Proc Soc Exp Biol Med* 143:634–637
- Reddy KP, Nayak DG, Uppoor AS (2006) A clinical evaluation of anorganic bovine bone graft plus 10% collagen with or without a barrier in the treatment of class II furcation defects. *J Contemp Dent Pract* 7:60–70
- Renoji W, Hoogendoorn A, Visser WJ, Lentferkink RHF, Schimtz MGJ, Ieperen HV et al (1985) Bioresorption of ceramic strontium-85-labeled calcium phosphate implants in dog femora. *Clin Orthop* 197:272–285
- Renvert S, Garrett S, Nilvéus R, Chamberlain AD, Egelberg J (1985a) Healing after treatment of periodontal intraosseous defects. VI. Factors influencing the healing response. *J Clin Periodontol* 12:707–715
- Renvert S, Garrett S, Shallhorn RG, Egelberg J (1985b) Healing after treatment of periodontal intraosseous defects. III. Effect of osseous grafting and citric acid conditioning. *J Clin Periodontol* 12:441–455
- Reynolds MA, Aichelmann-Reidy ME, Branch-Mays GL, Gunsolley JC (2003) The efficacy of bone replacement grafts in the treatment of periodontal osseous defects. *Ann Periodontol* 8:227–265
- Reynolds MA, Aichelmann-Reidy ME, Branch-Mays GL (2010) Regeneration of periodontal tissue: bone replacement grafts. *Dent Clin North Am* 54:55–71
- Ricci JL, Blumenthal NC, Spivak JM, Alexander H (1992) Evaluation of a lowtemperature calcium phosphate particulate implant material: physical-chemical properties and in vivo bone response. *Int J Oral Maxillofac Surg* 50:969–978
- Richardson CR, Mellonig JT, Brunsvold MA, McDonnell HT, Cochran DL (1999) Clinical evaluation of Bio-Oss: a bovine-derived xenograft for the treatment of periodontal osseous defects in humans. *J Clin Periodontol* 26:421–428
- Ridgway HK, Mellonig JT, Cochran DL (2008) Human histologic and clinical evaluation of recombinant human platelet-derived growth factor and beta-tricalcium phosphate for the treatment of periodontal intraosseous defects. *Int J Periodontics Restorative Dent* 28:171–179
- Ripamonti U, Crooks J, Khoali L, Roden L (2009) The induction of bone formation by coral-derived calcium carbonate/hydroxyapatite constructs. *Biomaterials* 30:1428–1439
- Ritchie HH, Ritchie DG, Wang LH (1998) Sixades of dentinogenesis research. Historical and prospective views on phosphoryn and dentin sialoprotein. *Eur J Oral Sci* 106:211–220
- Rivault AF, Toto PD, Levy S, Gargiulo AW (1971) Autogenous bone grafts: osseous coagulum and osseous retrograde procedures in primates. *J Periodontol* 42:787–796
- Robinson E (1969) Osseous coagulum for bone induction. *J Periodontol* 40:503–510
- Rosen PS, Reynolds MA (1999) Polymer-assisted regenerative therapy: case reports of 22 consecutively treated periodontal defects with ael combined surgical approach. *J Periodontol* 70:554–561

- Rosen PS, Reynolds MA (2001) Guided bone regeneration for dehiscence and fenestration defects on implants using an absorbable polymer barrier. *J Periodontol* 72:250–256
- Rosen PS, Reynolds MA (2002) A retrospective case series comparing the use of demineralized freeze-dried bone allograft and freeze-dried bone allograft combined with enamel matrix derivative for the treatment of advanced osseous lesions. *J Periodontol* 73:942–949
- Rosen PS, Reynolds MA, Bowers GM (2000) The treatment of intrabony defects with bone grafts. *Periodontol* 2000 22:88–103
- Rosenberg E, Rose LF (1998) Biologic and clinical considerations for autografts and allografts in periodontal regeneration therapy. *Dent Clin North Am* 42:467–490
- Rosenberg ES, Fox GK, Cohen C (2000) Bioactive glass granules for regeneration of human periodontal defects. *J Esthet Dent* 12:248–257
- Rummelhart JM, Mellonig JT, Gray JL, Towle HJ (1989) A comparison of freeze-dried bone allograft and demineralized freeze-dried bone allograft in human periodontal osseous defects. *J Periodontol* 60:655–663
- Sabetrisekh R, Tiainen H, Lyngstadaas SP, Reseland J, Haugen H (2011) A novel ultra-porous titanium dioxide ceramic with excellent biocompatibility. *J Biomater Appl* 25(6):559–580
- Saffar JL, Colombier ML, Detienville R (1990) Bone formation in tricalcium phosphate-filled periodontal intrabony lesions. Histological observations in humans. *J Periodontol* 61:209–216
- Sakata J, Abe H, Ohazama A, Okubo K, Nagashima C, Suzuki M, Hasegawa K (2006) Effects of combined treatment with porous bovine inorganic bone grafts and bilayer porcine collagen membrane on refractory one-wall intrabony defects. *Int J Periodontics Restorative Dent* 26:161–169
- Sanders JJ, Sepe WW, Bowers GM, Koch RW, Williams JE, Lekas JS, Mellonig JT, Pelleu GB Jr, Gambill V (1983) Clinical evaluation of freeze-dried bone allografts in periodontal osseous defects. Part III. Composite freeze-dried bone allografts with and without autogenous bone grafts. *J Periodontol* 54:1–8
- Sapkos SW (1986) The use of periograft in periodontal defects. Histologic findings. *J Periodontol* 57:7–13
- Sarment DP, Cooke JW, Miller SE, Jin Q, McGuire MK, Kao RT, McClain PK, McAllister BS, Lynch SE, Giannobile WV (2006) Effect of rhPDGF-BB on bone turnover during periodontal repair. *J Clin Periodontol* 33:135–140
- Sato I, Akizuki T, Oda S, Tsuchioka H, Hayashi C, Takasaki AA, Mizutani K, Kawakatsu N, Kinoshita A, Ishikawa I, Izumi Y (2009) Histological evaluation of alveolar ridge-mentation using injectable calcium phosphate bone cement in dogs. *J Oral Rehabil* 36:762–769
- Scabbia A, Trombelli L (2004) A comparative study on the use of a HA/collagen/chondroitin sulphate biomaterial (Biostites) and a bovine-derived HA xenograft (Bio-Oss) in the treatment of deep intra-osseous defects. *J Clin Periodontol* 31:348–355
- Schallhorn RG, Hiatt WH (1972) Human allografts of iliac cancellous bone androw in periodontal osseous defects. II. Clinical observations. *J Periodontol* 43:67–81
- Schepers E, de Clercq M, Ducheyne P, Kempeneers R (1991) Bioactive glass particulate material as a filler for bone lesions. *J Oral Rehabil* 18:439–452
- Schepers EJ, Ducheyne P, Barbier L, Schepers S (1993) Bioactive glass particles of narrow size range: a new material for the repair of bone defects. *Implant Dent* 2:151–156
- Schepers E, Barbier L, Ducheyne P (1998) Implant placement enhanced by bioactive glass particles of narrow size range. *Int J Oral Maxillofac Implants* 13:655–665
- Scheyer ET, Velasquez-Plata D, Brunsvold MA, Lasho DJ, Mellonig JT (2002) A clinical comparison of a bovine-derived xenograft used alone and in combination with enamel matrix derivative for the treatment of periodontal osseous defects in humans. *J Periodontol* 73:423–432
- Schlegel AK, Donath K (1998) Bio-Oss®: a resorbable bone substitute? *J Long Term Eff Med Implants* 8:201–209
- Schopper C, Moser D, Sabbas A, Lagogiannis G, Spassova E, Konig F, Donath K, Ewers R (2003) The fluorohydroxyapatite (FHA) FRIOS Algipore is a suitable biomaterial for the reconstruction of severely atrophic human maxillae. *Clin Oral Implants Res* 14:743–749
- Schou S, Holmstrup P, Jørgensen T, Skovgaard LT, Stoltze K, Hjørting-Hansen E, Wenzel A (2003) Anorganic porous bovine-derived bone mineral (Bio-Oss) and ePTFE membrane in the treatment of peri-implantitis in cynomolgus monkeys. *Clin Oral Implants Res* 14:535–547
- Schrad SC, Tussing GJ (1986) Human allografts of iliac bone androw in periodontal osseous defects. *J Periodontol* 57: 205–210
- Schulz A, Hilgers RD, Niedermeier W (2000) The effect of splinting of teeth in combination with reconstructive periodontal surgery in humans. *Clin Oral Investig* 4(2): 98–105
- Schwartz Z, Mellonig JT, Carnes DL Jr, de la Fontaine J, Cochran DL, Dean DD, Boyan BD (1996) Ability of commercial demineralized freeze-dried bone allograft to induce new bone formation. *J Periodontol* 67:918–926
- Schwartz Z, Somers A, Mellonig JT, Carnes DL Jr, Dean DD, Cochran DL, Boyan BD (1998a) Ability of commercial demineralized freeze-dried bone allograft to induce new bone formation is dependent on donor age but not gender. *J Periodontol* 69:470–478
- Schwartz Z, Somers A, Mellonig JT, Carnes DL Jr, Wozney JM, Dean DD, Cochran DL, Boyan BD (1998b) Addition of human recombinant bone morphogenetic protein-2 to inactive commercial human demineralized freeze-dried bone allograft makes an effective composite bone inductive implant material. *J Periodontol* 69:1337–1345
- Schwarz F, Bieling K, Latz T, Nuesry E, Becker J (2006a) Healing of intrabony peri-implantitis defects following application of a nanocrystalline hydroxyapatite (Ostim) or a bovine-derived xenograft (Bio-Oss) in combination with a collagen membrane (Bio-Gide). A case series. *J Clin Periodontol* 33:491–499
- Schwarz F, Stratul SI, Herten M, Beck B, Becker J, Sculean A (2006b) Effect of an oily calcium hydroxide suspension (Osteoinductal) on healing of intrabony periodontal defects. A pilot study in dogs. *Clin Oral Investig* 10:29–34
- Schwarz F, Herten M, Ferrari D et al (2007) Guided bone regeneration at dehiscence-type defects: using biphasic hydroxyapatite + beta tricalcium phosphate (Bone Ceramic) or a collagen-coated natural bone mineral (BioOss Collagen): an immunohistochemical study in dogs. *Int J Oral Maxillofac Surg* 36:1198–1206

- Schwarz F, Sculean A, Bieling K, Ferrari D, Rothamel D, Becker J (2008) Two-year clinical results following treatment of peri-implantitis lesions using a nanocrystalline hydroxyapatite or a natural bone mineral in combination with a collagen membrane. *J Clin Periodontol* 35:80–87
- Schwarz F, Sahn N, Bieling K, Becker J (2009) Surgical regenerative treatment of peri-implantitis lesions using a nanocrystalline hydroxyapatite or a natural bone mineral in combination with a collagen follow-up report. *J Clin Periodontol* 36:807–814
- Sculean A, Barbé G, Chiantella GC, Arweiler NB, Berakdar M, Brex M (2002a) Clinical evaluation of an enamel matrix protein derivative combined with a bioactive glass for the treatment of intrabony periodontal defects in humans. *J Periodontol* 73:401–408
- Sculean A, Chiantella GC, Windisch P, Gera I, Reich E (2002b) Clinical evaluation of an enamel matrix protein derivative (Emdogain) combined with a bovine-derived xenograft (Bio-Oss) for the treatment of intrabony periodontal defects in humans. *Int J Periodontics Restorative Dent* 22:259–267
- Sculean A, Berakdar M, Chiantella GC, Donos N, Arweiler NB, Brex M (2003) Healing of intrabony defects following treatment with a bovine-derived xenograft and collagen membrane. A controlled clinical study. *J Clin Periodontol* 30:73–80
- Sculean A, Stavropoulos A, Windisch P, Keglevich T, Karring T, Gera I (2004a) Healing of human intrabony defects following regenerative periodontal therapy with a bovine-derived xenograft and guided tissue regeneration. *Clin Oral Investig* 8:70–74
- Sculean A, Windisch P, Chiantella GC (2004b) Human histologic evaluation of an intrabony defect treated with enamel matrix derivative, xenograft, and GTR. *Int J Periodontics Restorative Dent* 24:326–333
- Sculean A, Chiantella GC, Windisch P, Arweiler NB, Brex M, Gera I (2005a) Healing of intra-bony defects following treatment with a composite bovine-derived xenograft (Bio-Oss Collagen) in combination with a collagen membrane (Bio-Gide PERIO). *J Clin Periodontol* 32:720–724
- Sculean A, Pietruska M, Schwarz F, Willershausen B, Arweiler NB, Ausschill TM (2005b) Healing of human intrabony defects following regenerative periodontal therapy with an enamel matrix protein derivative alone or combined with a bioactive glass. A controlled clinical study. *J Clin Periodontol* 32:111–117
- Sculean A, Windisch P, Keglevich T, Gera I (2005c) Clinical and histologic evaluation of an enamel matrix protein derivative combined with a bioactive glass for the treatment of intrabony periodontal defects in humans. *Int J Periodontics Restorative Dent* 25:139–147
- Sculean A, Pietruska M, Arweiler NB, Ausschill TM, Nemcovsky C (2007a) Four-year results of a prospective-controlled clinical study evaluating healing of intra-bony defects following treatment with an enamel matrix protein derivative alone or combined with a bioactive glass. *J Clin Periodontol* 34:507–513
- Sculean A, Schwarz F, Chiantella GC, Donos N, Arweiler NB, Brex M, Becker J (2007b) Five-year results of a prospective, randomized, controlled study evaluating treatment of intra-bony defects with a natural bone mineral and GTR. *J Clin Periodontol* 34:72–77
- Sculean A, Windisch P, Szendrői-Kiss D, Horváth A, Rosta P, Becker J, Gera I, Schwarz F (2008) Clinical and histologic evaluation of an enamel matrix derivative combined with a biphasic calcium phosphate for the treatment of human intrabony periodontal defects. *J Periodontol* 79:1991–1999
- Sepe WW, Bowers GM, Lawrence JJ, Friedlaender GE, Koch RW (1978) Clinical evaluation of freeze-dried bone allografts in periodontal osseous defects—part II. *J Periodontol* 49:9–14
- Serre CM, Papillard M, Chavassieux P, Boivin G (1993) In vitro induction of a calcifying matrix by biomaterials constituted of collagen and/or hydroxyapatite: an ultrastructural comparison of three types of biomaterials. *Biomaterials* 14:97–106
- Setya AB, Bissada NF (1999) Clinical evaluation of the use of calcium sulfate in regenerative periodontal surgery for the treatment of Class III furcation involvement. *Periodontol Clin Investig* 21:5–14
- Shaffer CD, App GR (1971) The use of plaster of paris in treating infrabony periodontal defects in humans. *J Periodontol* 42:685–690
- Shahmiri S, Singh IJ, Stahl SS (1992) Clinical response to the use of the HTR polymer implant in human intrabony lesions. *Int J Periodontics Restorative Dent* 12:295–299
- Shapoff CA, Alexander DC, Clark AE (1997) Clinical use of a bioactive glass particulate in the treatment of human osseous defects. *Compend Contin Educ Dent* 18:352–358
- Shi K, Hayashida K, Hashimoto J, Sugamoto K, Kawai H, Yoshikawa H (2006) Hydroxyapatite augmentation for bone atrophy in total ankle replacement in rheumatoid arthritis. *J Foot Ankle Surg* 45(5):316–321
- Shi H, Ma J, Zhao N, Chen Y, Liao Y (2008) Periodontal regeneration in experimentally-induced alveolar bone dehiscence by an improved porous biphasic calcium phosphate ceramic in beagle dogs. *J Mater Sci Mater Med* 19:3515–3524
- Shirakata Y, Oda S, Kinoshita A, Kikuchi S, Tsuchioka H, Ishikawa I (2002) Histocompatible healing of periodontal defects after application of an injectable calcium phosphate bone cement. A preliminary study in dogs. *J Periodontol* 73:1043–1053
- Shirakata Y, Yoshimoto T, Goto H, Yonamine Y, Kadomatsu H, Miyamoto M, Nakamura T et al (2007) Favorable periodontal healing of 1-wall infrabony defects after application of calcium phosphate cement wall alone or in combination with enamel matrix derivative: a pilot study with canine mandibles. *J Periodontol* 78:889–898
- Shirakata Y, Setoguchi T, Machigashira M, Matsuyama T, Furuichi Y, Hasegawa K, Yoshimoto T, Izumi Y (2008) Comparison of injectable calcium phosphate bone cement grafting and open flap debridement in periodontal intrabony defects: a randomized clinical trial. *J Periodontol* 79:25–32
- Shirakata Y, Taniyama K, Yoshimoto T, Miyamoto M, Takeuchi N, Matsuyama T, Noguchi K (2010) Regenerative effect of basic fibroblast growth factor on periodontal healing in two-wall intrabony defects in dogs. *J Clin Periodontol* 37(4):374–381
- Shirmohammadi A, Chitsazi MT, Lafzi A (2009) A clinical comparison of autogenous bone graft with and without autogenous periodontal ligament graft in the treatment of periodontal intrabony defects. *Clin Oral Investig* 13:279–286
- Sibilla P, Sereni A, Aguiari G, Banzi M, Manzati E, Mischiati C, Trombelli L, del Senno L (2006) Effects of a hydroxyapatite-

- based biomaterial on gene expression in osteoblast-like cells. *J Dent Res* 85:354–358
- Simonpietri-C JJ, Novaes AB Jr, Batista EL Jr, Filho EJ (2000) Guided tissue regeneration associated with bovine-derived anorganic bone in mandibular class II furcation defects. 6-month results at re-entry. *J Periodontol* 71:904–911
- Skoglund A, Hising P, Young CA (1997) Clinical and histologic examination of the osseous response to implanted natural bone mineral. *Int J Oral Maxillofac Implants* 12:194–199
- Smith IO, Baumann MJ, McCabe LR (2004) Electrostatic interactions as a predictor for osteoblast attachment to biomaterials. *J Biomed Mater Res A* 70:436–441
- Snyder AJ, Levin MP, Cutright DE (1984) Alloplastic implants of tricalcium phosphate ceramic in human periodontal osseous defects. *J Periodontol* 55:273–277
- Sogal A, Tofe AJ (1999) Risk assessment of bovine spongiform encephalopathy transmission through bone graft material derived from bovine bone used for dental applications. *J Periodontol* 70:1053–1063
- Sorensen RG, Wikesjö UM, Kinoshita A, Wozney JM (2004) Periodontal repair in dogs: evaluation of a bioresorbable calcium phosphate cement (Ceredex) as a carrier for rhBMP-2. *J Clin Periodontol* 31:796–804
- Sottosanti JS (1993) Aesthetic extractions with calcium sulfate and the principles of guided tissue regeneration. *Pract Periodontics Aesthet Dent* 5:61–69
- Sottosanti JS (1995) Calcium sulfate-aided bone regeneration: a case report. *Periodontol Clin Investig* 17:10–15
- Stahl SS, Froum S (1986) Histological evaluation of human intraosseous healing responses to the placement of tricalcium phosphate ceramic implants. I. Three to eight months. *J Periodontol* 57:211–217
- Stahl SS, Froum SJ (1987) Histologic and clinical responses to porous hydroxylapatite implants in human periodontal defects. Three to twelve months postimplantation. *J Periodontol* 58:689–695
- Stahl SS, Froum SJ, Tamow D (1990) Human clinical and histologic responses to the placement of HTR polymer particles in 11 intrabony lesions. *J Periodontol* 61:269–274
- Stanley HR, Hall MB, Colaizzi F, Clark AE (1987) Residual alveolar ridge maintenance with a new endosseous implant material. *J Prosthet Dent* 58:607–613
- Stanley HR, Clark AE, Pameijer CH, Louw NP (2001) Pulp capping with a modified bioglass formula (#A68-modified). *Am J Dent* 14:227–232
- Stavropoulos A, Karring T (2005) Five-year results of guided tissue regeneration in combination with deproteinized bovine bone (Bio-Oss) in the treatment of intrabony periodontal defects: a case series report. *Clin Oral Investig* 9:271–277
- Stavropoulos A, Kostopoulos L, Nyengaard JR, Karring T (2003) Deproteinized bovine bone (Bio-Oss®) and bioactive glass (Biogran®) arrest bone formation when used as an adjunct to guided tissue regeneration (GTR). *J Clin Periodontol* 30:636–643
- Stavropoulos A, Sculean A, Karring T (2004) GTR treatment of intrabony defects with PLA/PGA copolymer or collagen bioresorbable membranes in combination with deproteinized bovine bone (Bio-Oss). *Clin Oral Investig* 8:226–232
- Stavropoulos A, Geenen C, Nyengaard JR, Karring T, Sculean A (2007) Oily calcium hydroxide suspension (Osteoinductal) used as an adjunct to guided bone regeneration: an experimental study in rats. *Clin Oral Implants Res* 18:761–767
- Stavropoulos A, Windisch P, Szendrői-Kiss D, Peter R, Gera I, Sculean A (2010) Clinical and histologic evaluation of granular beta-tricalcium phosphate for the treatment of human intrabony periodontal defects: a report on five cases. *J Periodontol* 81(2):325–334
- Stein JM, Fickl S, Yekta SS, Hoischen U, Ocklenburg C, Smeets R (2009) Clinical evaluation of a biphasic calcium composite grafting material in the treatment of human periodontal intrabony defects: a 12-month randomized controlled clinical trial. *J Periodontol* 80:1774–1782
- Stoor P, Söderling E, Salonen JI (1998) Antibacterial effects of a bioactive glass paste on oral microorganisms. *Acta Odontol Scand* 56:161–165
- Stratul SI (2003) Oily calcium hydroxide plus  $\alpha$ -TCP in treating intrabony defects. *J Clin Periodontol* 30:71
- Stratul SI, Sculean A (2004) Oily calcium hydroxide suspension and  $\alpha$ -TCP in treating intrabony defects. *Int Poster J Dent Oral Med* 6:Poster 235
- Stratul SI, Schwarz F, Becker J, Willershausen B, Sculean A (2006) Healing of intrabony defects following treatment with an oily calcium hydroxide suspension (Osteoinductal). A controlled clinical study. *Clin Oral Investig* 10:55–60
- Strub JR, Gaberthuel TW, Firestone AR (1979) Comparison of tricalcium phosphate and frozen allogenic bone implants in man. *J Periodontol* 50:624–629
- Sugawara A, Fujikawa K, Takagi S, Chow LC (2008) Histological analysis of calcium phosphate bone grafts for surgically created periodontal bone defects in dogs. *Dent Mater J* 27:787–794
- Sukumar S, Drízhai L (2008) Bone grafts in periodontal therapy. *Acta Medica (Hradec Kralove)* 51:203–207
- Sun W, Chu C, Wang J, Zhao H (2007) Comparison of periodontal ligament cells responses to dense and nanophase hydroxyapatite. *J Mater Sci Mater Med* 18:677–683
- Tadic D, Epple M (2004) A thorough physicochemical characterisation of 14 calcium phosphate-based bone substitution materials in comparison to natural bone. *Biomaterials* 25:987–994
- Tadjoedin ES, de Lange GL, Bronckers AL, Lyaruu DM, Burger EH (2003) Deproteinized cancellous bovine bone (Bio-Oss) as bone substitute for sinus floor elevation. A retrospective, histomorphometrical study of five cases. *J Clin Periodontol* 30:261–270
- Tamimi F, Torres J, Bettini R, Ruggera F, Rueda C, López-Ponce M, Lopez-Cabarcos E (2008) Doxycycline sustained release from brushite cements for the treatment of periodontal diseases. *J Biomed Mater Res A* 85:707–714
- Taschieri S, Del Fabbro M, Testori T, Weinstein R (2007) Efficacy of xenogeneic bone grafting with guided tissue regeneration in the management of bone defects after surgical endodontics. *J Oral Maxillofac Surg* 65:1121–1127
- TenHuisen KS, Brown PW (1998) Formation of calcium-deficient hydroxyapatite from alpha-tricalcium phosphate. *Biomaterials* 19:2209–2217
- Tezulas E, Dilek OC (2008) Decontamination of autogenous bone grafts collected from dental implant sites via osteotomy: a review. *Oral Surg Oral Med Oral Pathol Oral Radiol Endod* 106:679–684

- Tezulas E, Dilek OC, Topcuoglu N, Kulekci G (2009) Decontamination of autogenous bone grafts collected during dental implant site preparation: a pilot study. *Oral Surg Oral Med Oral Pathol Oral Radiol Endod* 107(5):656–660
- Thorwarth M, Schultze-Mosgau S, Kessler P, Wiltfang J, Schlegel KA (2005) Bone regeneration in osseous defects using a resorbable nanoparticulate hydroxyapatite. *J Oral Maxillofac Surg* 63:1626–1633
- Thorwarth M, Schlegel KA, Wehhan F, Srouf S, Schultze-Mosgau S (2006) Acceleration of de novo bone formation following application of autogenous bone to particulated anorganic bovine material in vivo. *Oral Surg Oral Med Oral Pathol Oral Radiol Endod* 101:309–316
- Thronsdorff RR, Sexton SB (2002) Grafting mandibular third molar extraction sites: a comparison of bioactive glass to a nongrafted site. *Oral Surg Oral Med Oral Pathol Oral Radiol Endod* 94:413–419
- Tonetti MS, Pini Prato G, Cortellini P (1995) Effect of cigarette smoking on periodontal healing following GTR in intrabony defects: a preliminary retrospective study. *J Clin Periodontol* 22:229–234
- Tonetti M, Pini-Prato G, Cortellini P (1996) Factors affecting the healing response of intrabony defects following guided tissue regeneration and access flap surgery. *J Clin Periodontol* 23:548–556
- Tonetti M, Cortellini P, Suvan J et al (1998) Generalizability of the added benefits of guided tissue regeneration in the treatment of deep intrabony defects. Evaluation in a multi-center randomized controlled clinical trial. *J Periodontol* 69:1183–1192
- Tonetti MS, Cortellini P, Lang NP, Suvan JE, Adriaens P, Dubravec D, Fonzar A, Fourmousis I, Rasperini G, Rossi R, Silvestri M, Topoll H, Wallkamm B, Zybutz M (2004) Clinical outcomes following treatment of human intrabony defects with GTR/bone replacement material or access flap alone. A multicenter randomized controlled clinical trial. *J Clin Periodontol* 31:770–776
- Trejo PM, Weltman R, Caffesse R (2000) Treatment of intraosseous defects with bioabsorbable barriers alone or in combination with decalcified freeze-dried bone allograft: a randomized clinical trial. *J Periodontol* 71:1852–1861
- Trombelli L, Heitz-Mayfield LJ, Needleman I, Moles D, Scabbia A (2002) A systematic review of graft materials and biological agents for periodontal intraosseous defects. *J Clin Periodontol* 29:117–135
- Trombelli L (2005) Which reconstructive procedures are effective for treating the periodontal intraosseous defect? *Periodontol* 2000 37:88–105
- Trombelli L, Annunziata M, Belardo S, Farina R, Scabbia A, Guida L (2006) Autogenous bone graft in conjunction with enamel matrix derivative in the treatment of deep periodontal intra-osseous defects: a report of 13 consecutively treated patients. *J Clin Periodontol* 33:69–75
- Trombelli L, Farina R, Franceschetti G, Calura G (2009) Single-flap approach with buccal access in periodontal reconstructive procedures. *J Periodontol* 80:353–360
- Trombelli L, Simonelli A, Pramstraller M, Wikesjö UM, Farina R (2010) Single flap approach with and without guided tissue regeneration and a hydroxyapatite biomaterial in the management of intraosseous periodontal defects. *J Periodontol* 81:1256–1263
- Turner TM, Urban RM, Hall DJ, Andersson GB (2007) Bone ingrowth through porous titanium granulate around a femoral stem: histological assessment in a six-month canine hemiarthroplasty model. *Ups J Med Sci* 112:191–197
- Valentini P, Abensur D (1997) Maxillary sinus floor elevation for implant placement with demineralized freeze-dried bone and bovine bone (Bio-Oss): a clinical study of 20 patients. *Int J Periodontics Restorative Dent* 17:232–241
- Valentini P, Abensur DJ (2003) Maxillary sinus grafting with anorganic bovine bone: a clinical report of long-term results. *Int J Oral Maxillofac Implants* 18:556–560
- Valentini P, Abensur D, Densari D, Graziani JN, Hämmerle C (1998) Histological evaluation of Bio-Oss in a 2-stage sinus floor elevation and implantation procedure. A human case report. *Clin Oral Implants Res* 9:59–64
- Valentini P, Abensur D, Wenz B, Peetz M, Schenk R (2000) Sinus grafting with porous bone mineral (Bio-Oss) for implant placement: a 5-year study on 15 patients. *Int J Periodontics Restorative Dent* 20:245–253
- Velasquez-Plata D, Scheyer ET, Mellonig JT (2002) Clinical comparison of an enamel matrix derivative used alone or in combination with a bovine-derived xenograft for the treatment of periodontal osseous defects in humans. *J Periodontol* 73:433–440
- Venezia E, Goldstein M, Boyan BD, Schwartz Z (2004) The use of enamel matrix derivative in the treatment of periodontal defects: a literature review and meta-analysis. *Crit Rev Oral Biol Med* 15:382–402
- Villaça JH, Novaes AB Jr, Souza SL, Taba M Jr, Molina GO, Carvalho TL (2005) Bioactive glass efficacy in the periodontal healing of intrabony defects in monkeys. *Braz Dent J* 16(1):67–74
- von Arx T, Cochran DL, Hermann JS, Schenk RK, Buser D (2001) Lateral ridge augmentation using different bone fillers and barrier membrane application. A histologic and histomorphometric pilot study in the canine mandible. *Clin Oral Implants Res* 12:260–269
- Vouros I, Aristodimou E, Konstantinidis A (2004) Guided tissue regeneration in intrabony periodontal defects following treatment with two bioabsorbable membranes in combination with bovine bone mineral graft. A clinical and radiographic study. *J Clin Periodontol* 31:908–917
- Vrouwenvelder WCA, Groot CG, Groot K (1993) Histological and biochemical evaluation of osteoblasts cultured on bioactive glass, hydroxylapatite, titanium alloy, and stainless steel. *J Biomed Mater Res* 27:465–475
- Wada T, Wu CH, Sugita H, Sugita N, Katagiri S, Shimizu M, Hara K (1989) Autogenous, allogenic, and beta-TCP grafts: comparative effectiveness in experimental bone furcation defects in dogs. *J Oral Implantol* 15:231–236
- Wagner JR (1989) Clinical and histological case study using resorbable hydroxylapatite for the repair of osseous defects prior to endosseous implant surgery. *J Oral Implantol* 15:186–192
- Wallace SS, Froum SJ (2003) Effect of maxillary sinus augmentation on the survival of endosseous dental implants. A systematic review. *Ann Periodontol* 8:328–343
- Wang HL, Kimble K, Eber R (2002) Use of bone grafts for the enhancement of a GTR-based root coverage procedure: a pilot case study. *Int J Periodontics Restorative Dent* 22:119–127

- Wang L, Shi H, Chen Y, Xue J, Chen Y, Liao Y (2010) Healing of acute alveolar bone dehiscence following treatment with porous biphasic calcium phosphate in beagle dogs. *Clin Oral Investig* [Epub ahead of print]
- Wenz B, Oesch B, Horst M (2001) Analysis of the risk of transmitting bovine spongiform encephalopathy through bone grafts derived from bovine bone. *Biomaterials* 22: 1599–1606
- Wikesjö UM, Sorensen RG, Kinoshita A, Wozney JM (2002) RhBMP-2/alphaBSM induces significant vertical alveolar ridgementation and dental implant osseointegration. *Clin Implant Dent Relat Res* 4:174–182
- Wikesjö UM, Lim WH, Razi SS, Sigurdsson TJ, Lee MB, Tatakis DN, Hardwick WR (2003) Periodontal repair in dogs: a bioabsorbable calcium carbonate coral implant enhances space provision for alveolar bone regeneration in conjunction with guided tissue regeneration. *J Periodontol* 74:957–964
- Wildemann B, Kadow-Romacker A, Pruss A, Haas NP, Schmidmaier G (2007) Quantification of growth factors in allogenic bone grafts extracted with three different methods. *Cell Tissue Bank* 8:107–114
- Wilson J, Low SB (1992) Bioactive ceramics for periodontal treatment: comparative studies in the Patus monkey. *J Appl Biomater* 3:123–129
- Wilson TG, Glover ME, Schoen J, Baust C, Jacobs T (1984) Compliance with maintenance therapy in a private periodontal practice. *J Periodontol* 55:468–473
- Wilson J, Clark AE, Hall M, Hench LL (1993a) Tissue response to bioglass endosseous ridge maintenance implants. *J Oral Implantol* 19:295–302
- Wilson TG, Hale S, Temple R (1993b) The results of efforts to improve compliance with supportive periodontal treatment in a private practice. *J Periodontol* 64:311–314
- Winn SR, Hollinger JO (2000) An osteogenic cell culture system to evaluate the cytocompatibility of Osteoset, a calcium sulfate bone void filler. *Biomaterials* 21:2413–2425
- Wohlfahrt JC, Aass AM, Rønold HJ, Karlsson S, Ellingsen JE, Saxegaard E, Lyngstadaas SP (2010a) Porous titanium granules in the surgical treatment of peri-implant osseous defects – a randomized clinical trial. Presented at the 19th Annual Scientific Meeting of the European Association for Osseointegration, October 6–9, 2010, Glasgow, United Kingdom. *Clin Oral Implants Res* 21:1014
- Wohlfahrt JC, Monjo M, Rønold HJ, Aass AM, Ellingsen JE, Lyngstadaas SP (2010b) Porous titanium granules promote bone healing and growth in rabbit tibia peri-implant osseous defects. *Clin Oral Implants Res* 21:165–173
- Wohlfahrt JC, Rønold HJ, Aass AM, Heijl L, Lyngstadaas SP (2010c) Porous titanium granules in furcation defects – an animal experimental study. Presented at the 88th General Session of the International Association of Dental Research, July 14–17, 2010, Barcelona, Spain. *J Dent Res* 89(Spec Iss B):3862
- Wong MY, Hong CY, Chang WK (1989) Comparison of histological effects of different bioceramic implants on surgically created periodontal defects in monkeys. *Taiwan Yi Xue Hui Za Zhi* 88:152–158
- Xu HH, Quinn JB, Takagi S, Chow LC (2002) Processing and properties of strong and non-rigid calcium phosphate cement. *J Dent Res* 81:219–224
- Xu HH, Takagi S, Sun L, Hussain L, Chow LC, Guthrie WF, Yen JH (2006) Development of a nonrigid, durable calcium phosphate cement for use in periodontal bone repair. *J Am Dent Assoc* 137:1131–1138
- Xu HH, Carey LE, Simon CG Jr, Takagi S, Chow LC (2007) Premixed calcium phosphate cements: synthesis, physical properties, and cell cytotoxicity. *Dent Mater* 23:433–441
- Xynos ID, Edgar AJ, Buttery LD, Hench LL, Polak JM (2000a) Ionic products of bioactive glass dissolution increase proliferation of human osteoblasts and induce insulin like growth factor II mRNA expression and protein synthesis. *Biochem Biophys Res Commun* 276:461–565
- Xynos ID, Hukkanen MV, Batten JJ, Buttery LD, Hench LL, Polak JM (2000b) Bioglass 45 S5 stimulates osteoblast turnover and enhances bone formation in vitro: implication and applications for bone tissue engineering. *Calcif Tissue Int* 67: 321–329
- Yagihashi K, Miyazawa K, Togari K, Goto S (2009) Demineralized dentin matrix acts as a scaffold for repair of articular cartilage defects. *Calcif Tissue Int* 84:210–220
- Yamada M, Minamikawa H, Ueno T, Sakurai K, Ogawa T (2010) N-acetyl cysteine improves affinity of beta-tricalcium phosphate granules for cultured osteoblast-like cells. *J Biomater Appl*; (Epub ahead of print)
- Yassibag-Berkman Z, Tuncer O, Subasioglu T, Kantarci A (2007) Combined use of platelet-rich plasma and bone grafting with or without guided tissue regeneration in the treatment of anterior interproximal defects. *J Periodontol* 78:801–809
- Yilmaz S, Cakar G, Yildirim B, Sculean A (2010) Healing of two and three wall intrabony periodontal defects following treatment with an enamel matrix derivative combined with autogenous bone. *J Clin Periodontol* 37:544–550
- Yli-Urpo H, Närhi T, Söderling E (2003) Antimicrobial effects of glass ionomer cements containing bioactive glass (S53P4) on oral micro-organisms in vitro. *Acta Odontol Scand* 61:241–246
- Ymane S, Higuchi Y, Abe N, Fujii K, Okamura K, Nosaka T, Funabashi K, Ueno T (1998) Application of denta root tips as bone replacement material. *Nihon Koukuugeka Implant* 11:16–22
- Yu D, Wong J, Matsuda Y, Fox JL, Higuchi WI, Otsuka M (1992) Self-setting hydroxyapatite cement: a novel skeletal drug-delivery system for antibiotics. *J Pharm Sci* 81:529–531
- Yuan H, Kurashina K, de Bruijn JD, Li Y, de Groot K, Zhang X (1999) A preliminary study on osteoinduction of two kinds of calcium phosphate ceramics. *Biomaterials* 20: 1799–1806
- Yuan H, Li Y, de Bruijn JD, de Groot K, Zhang X (2000) Tissue responses of calcium phosphate cement: a study in dogs. *Biomaterials* 21:1283–1290
- Yuan H, De Groot K (2004) Calcium phosphate biomaterials: an overview. In: Reis RL, Weiner S (eds) *Learning from nature how to design new implantable biomaterials*. Kluwer Academic Publishers, Dordrecht, pp 37–57
- Yukna RA (1990) HTR polymer grafts in human periodontal osseous defects. I. 6-month clinical results. *J Periodontol* 61:633–642
- Yukna RA (1994a) Clinical evaluation of coralline calcium carbonate as a bone replacement graft material in human periodontal osseous defects. *J Periodontol* 65:177–185

- Yukna RA (1994b) Clinical evaluation of HTR polymer bone replacement grafts in human mandibular class II molar furcations. *J Periodontol* 65:342–349
- Yukna RA, Greer RO Jr (1992) Human gingival tissue response to HTR polymer. *J Biomed Mater Res* 26:517–527
- Yukna RA, Vastardis S (2005) Comparative evaluation of decalcified and non-decalcified freeze-dried bone allografts in rhesus monkeys. I. Histologic findings. *J Periodontol* 76:57–65
- Yukna RA, Yukna CN (1997) Six-year clinical evaluation of HTR synthetic bone grafts in human grade II molar furcations. *J Periodontol Res* 32:627–633
- Yukna RA, Callan DP, Krauser JT, Evans GH, Aichelmann-Reidy ME, Moore K, Cruz R, Scott JB (1998) Multi-center clinical evaluation of combination anorganic bovine-derived hydroxyapatite matrix (ABM)/cell binding peptide (P-15) as a bone replacement graft material in human periodontal osseous defects: 6-month results. *J Periodontol* 69:655–663
- Yukna RA, Evans GH, Aichelmann-Reidy MB, Mayer ET (2001) Clinical comparison of bioactive glass bone replacement graft material and expanded polytetrafluoroethylene barrier membrane in treating human mandibular molar class II furcations. *J Periodontol* 72:125–133
- Yukna R, Salinas TJ, Carr RF (2002a) Periodontal regeneration following use of ABM/P-15: a case report. *Int J Periodontics Restorative Dent* 22:146–155
- Yukna RA, Krauser JT, Callan DP, Evans GH, Cruz R, Martin M (2002b) Thirty-six month follow-up of 25 patients treated with combination anorganic bovine-derived hydroxyapatite matrix (ABM)/cell-binding peptide (P-15) bone replacement grafts in human intrabony defects. I. Clinical findings. *J Periodontol* 73:123–128
- Zafiroopoulos GG, Hoffmann O, Kasaj A, Willershausen B, Weiss O, Van Dyke TE (2007) Treatment of intrabony defects using guided tissue regeneration and autogenous spongiosa alone or combined with hydroxyapatite/beta-tricalcium phosphate bone substitute or bovine-derived xenograft. *J Periodontol* 78:2216–2225
- Zamet JS, Darbar UR, Griffiths GS, Bulman JS, Brägger U, Bürgin W, Newman HN (1997) Particulate bioglass as a grafting material in the treatment of periodontal intrabony defects. *J Clin Periodontol* 24:410–418
- Zaner DJ, Yukna RA (1984) Particle size of periodontal bone grafting materials. *J Periodontol* 55:406–409
- Zehnder M, Söderling E, Salonen J, Waltimo T (2004) Preliminary evaluation of bioactive glass S53P4 as an endodontic medication in vitro. *J Endod* 30:220–224
- Zitzmann NU, Naef R, Schärer P (1997) Resorbable versus non-resorbable membranes in combination with Bio-Oss for guided bone regeneration. *Int J Oral Maxillofac Implants* 12:844–852
- Zitzmann NU, Schärer P, Marinello CP, Schüpbach P, Berglundh T (2001) Alveolar ridge regeneration with Bio-Oss: a histologic study in humans. *Int J Periodontics Restorative Dent* 21:288–295
- Zucchelli G, Amore C, Montebugnoli L, De Sanctis M (2003) Enamel matrix proteins and bovine porous bone mineral in the treatment of intrabony defects: a comparative controlled clinical trial. *J Periodontol* 74:1725–1735



<http://www.springer.com/978-3-642-18224-2>

Chemicals in Surgical Periodontal Therapy

Dumitrescu, A.L.

2011, IX, 307 p. 127 illus., 98 in color., Hardcover

ISBN: 978-3-642-18224-2